

## Unusual fungal infection of conidiobolomycosis presenting as nasal tumor – A case report

Shubhangi Agale<sup>1</sup>, Vanita Rathi<sup>2</sup>, Monica Tandale<sup>3</sup>

From <sup>1</sup>Professor, <sup>2</sup>Assistant Professor, <sup>3</sup>Resident, Department of Pathology, Grant Government Medical College, Mumbai, Maharashtra, India

### ABSTRACT

Conidiobolomycosis is an unusual chronic subcutaneous fungal infection belonging to the order *Entomophthorales* of zygomycetes. It commonly affects the upper respiratory tract, mucous membranes of the upper lip, and subcutaneous tissues. Clinically, it presents as painless woody swelling commonly affecting the rhinofacial region causing extensive facial deformity. Due to its rarity and the lack of awareness, the diagnosis can be challenging. The definitive diagnosis of rhinofacial conidiobolomycosis is based on histopathological examination of skin lesions. The awareness of this entity is important for early diagnosis and patient management which helps in reducing morbidity associated with disease. We report a rare histopathologically diagnosed case of conidiobolomycosis in a 17-year-old male which was clinically considered a vascular tumor and radiologically diagnosed as hemangioma.

**Key words:** Conidiobolomycosis, Nose, Subcutaneous zygomycoses, Tumor, Woody

Conidiobolomycosis is an unusual, chronic subcutaneous fungal infection belonging to the order *Entomophthorales* of zygomycetes. It is caused by *Conidiobolus coronatus*, *Conidiobolus incongruus*, and *Conidiobolus lamprauges* species of *Conidiobolus* [1,2]. Conidiobolomycosis, which is also known as entomophthoramycosis commonly affects the upper respiratory tract, mucous membranes of the upper lip, and subcutaneous tissues [3]. Clinically, it presents as painless woody swelling commonly affecting the rhinofacial region causing extensive facial deformity [4,5]. It can be misdiagnosed clinically as a soft-tissue tumor involving the nose and paranasal sinuses [6,7]. This infection mainly occurs in the tropical regions of Africa, Central America, and South-East Asia of which, only a few cases have been reported in India [8,9]. Studies on the prevalence of rhinofacial conidiobolomycosis are limited in the literature. The available information is based on various published case reports. A case report by Jain *et al.* highlighted an update on the disease in Asia showing about 46 cases (74%) reported from India followed by 8 cases (13%) in Thailand. The other cases were from Malaysia (two cases), China (single case), Taiwan (single case), Japan (single case), Sri Lanka (single case), and Singapore (single case) [3].

We report a rare histopathologically diagnosed case of conidiobolomycosis in a 17-year-old male which was clinically

considered a vascular tumor and radiologically diagnosed as hemangioma.

### CASE REPORT


A 17 year old male, student of 12<sup>th</sup> class, resident of Gorkhpur (Uttar Pradesh) came with painless gradually progressive firm to hard dorsal nasal swelling for 3 months along with deviated nasal septum to the left. The itching was present over the swelling. There was no history of trauma. There was no history of nasal obstruction/fever/recurrent cold/sneezing. No history of nasal bleed/headache was given by patient.

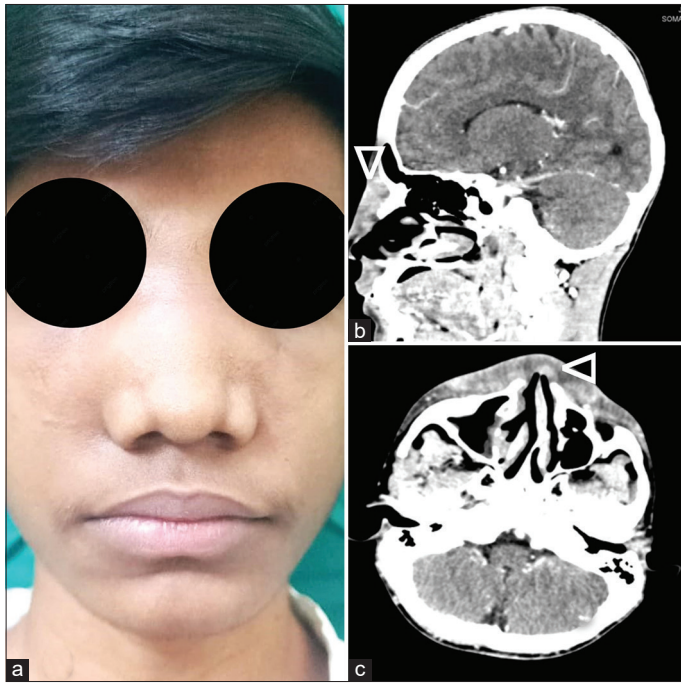
On clinical examination, there was 12 × 5 cm diffuse, hard, non-tender swelling at the root of the nose extending superiorly to the glabella and inferiorly 1 cm above the tip of the nose. There was lateral extension up to 3 cm from the ala of the nose toward the eyes at the midpoint between the medial and lateral canthus of the eyes (Fig. 1a). There was no regional lymph node enlargement.

Ultrasonography of the nose revealed diffuse heterogeneously hypoechoic soft-tissue lesion around the nasal bridge and nose in the subcutaneous plane with both arterial and venous vascularity suggestive of vascular tumor likely hemangioma. High-resolution computed tomography of the nose showed a well-defined homogeneously enhancing lesion in the subcutaneous plane overlying the nose and bilateral cheeks suggestive of hemangioma along with sinusitis along with deviated nasal septum to the left (Fig. 1b and c). The angiogram study was normal in this patient.

**Correspondence to:** Vanita Rathi, G 604, Redwoods, Yogi Hills, Cypress, Mulund West, Mumbai- 400080, Maharashtra, India. E-mail: drvanitarathi@gmail.com

© 2024 Creative Commons Attribution-NonCommercial 4.0 International License (CC BY-NC-ND 4.0).

Access this article online	
Received - 08 March 2024 Initial Review - 26 March 2024 Accepted - 31 May 2024	Quick Response code 
DOI: ***	



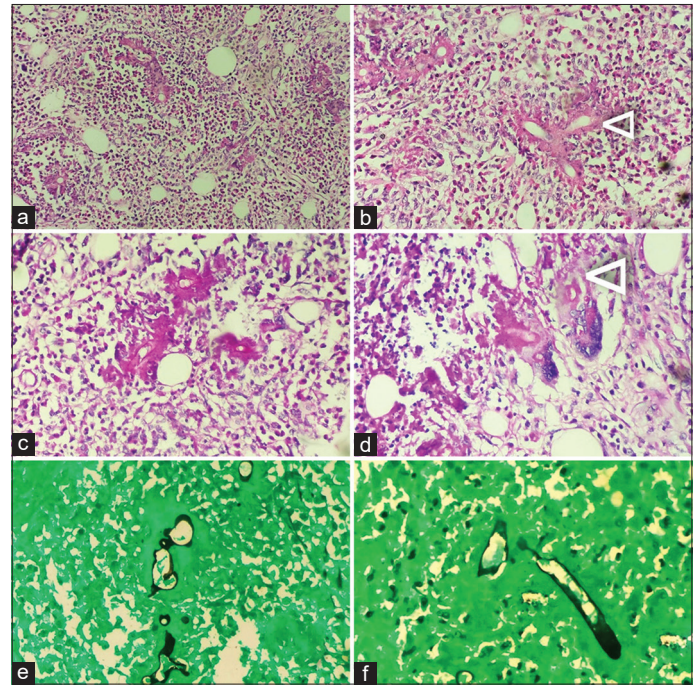
**Figure 1:** (a) Clinical examination showing diffuse and hard swelling with enlargement of nose and bilateral cheeks on medial side; (b and c) –Homogenously enhancing lesion in subcutaneous plane overlying nose and bilateral cheeks with no extension into nasal cavity suggestive of soft-tissue hemangioma on high-resolution computed tomography (Arrow head).

A biopsy was performed which showed a dense granulomatous inflammatory reaction with foreign body type of giant cells along with a dense mixed inflammatory infiltrate of neutrophils, eosinophils, lymphocytes, histiocytes, and plasma cells. There were broad aseptate fungal hyphae along with the Splendore–Hoepli phenomenon. Special stains such as grocott methenamine silver and periodic acid–Schiff stain highlighted broad fungal hyphae, a few of which were ingested by giant cells (Fig. 2). However, fungal culture did not yield any growth.

Based on histomorphological features and clinical history, diagnosis of conidiobolomycosis was given.

## DISCUSSION

Chronic subcutaneous infection by *Conidiobolus* species has been described in man, horses, dogs, and dolphins [10]. Bras *et al.* in 1965 reported the first human case of rhinoentomophthoromycosis due to *C. Coronatus* in the West Indies [11]. Klokke reported the first case of rhinoentomophthoromycosis in India at the Christian Medical College, Vellore, Tamil Nadu [12]. Chowdhary *et al.* studied a total of 39 sporadic cases of rhinoentomophthoromycosis, which were reported in 2010 from India. Of these, 13 cases were diagnosed histopathologically, whereas 26 cases were confirmed on culture and histopathological examination [13]. A review of 75 cases from the Indian subcontinent region by Gupta and Soneja found the majority of the cases were from the hot and humid states of West Bengal, Tamil Nadu, Delhi, and Punjab [14]. The infection typically occurs in immunocompetent hosts within tropical and subtropical climates [13]. Adult males in the age



**Figure 2:** (a and b) Hematoxylin and eosin (H and E) stained section showing Splendore–Hoepli phenomenon with star-like eosinophilic projections around broad aseptate fungal hyphae (arrowhead) with surrounding soft tissue showing dense eosinophilic infiltration; (c) Periodic acid-schiff stain showing Splendore–Hoepli phenomenon surrounding broad aseptate fungal hyphae; (d) Periodic acid-schiff stain showing fungal hyphae engulfed by giant cells (arrowhead); (e and f) grocott methenamine silver highlighting broad aseptate fungal hyphae with focal right-angled branching

group of 20–50 years with a history of outdoor occupations or who are involved in agriculture activities are typically affected [15]. A study by Gupta and Soneja found 62 males and 13 females presented with centropacial swelling in which the majority of cases were immunocompetent with a mean age of 35 years at presentation [14]. In our case report, the patient was immunocompetent and presented with nasal swelling.

It has an unknown incubation period having a predilection for the head and face region with chronic progressive subcutaneous infection; which can occur after an average of 10 months of progressive nasal symptoms [16]. Inhalation of spores that survive in soil and vegetables for a longer time or accidental inoculation by soiled hands in nasal mucosa are probable modes of transmission in fungal infections caused by *Conidiobolus* species [1,17]. From nasal mucosa as a result of enzymatic activity spores can penetrate into the subcutaneous tissue of the face, nasal cavity, and sinuses [18]. The habit of chewing tobacco leaves, pond bathing, and cattle ranching can be found in these patients [19]. *Conidiobolus* and *Basidiobolus* are two genera of zygomycetes that cause nasal swelling with centropacial deformity and limb girdle deformity, respectively [17].

Subcutaneous swelling over the nose may pose a wide range of differential diagnoses such as sarcoma, lymphoma, lymphedema, hemangioma, cellulitis, rhinoscleroma, and subcutaneous zygomycosis [4,17]. In our case, due to the high incidence of nasal tumors over subcutaneous zygomycosis, the case was misdiagnosed as hemangioma clinically and radiologically.

Hence, it is essential to consider subcutaneous zygomycoses clinically while encountering nasal tumors or nasal obstruction due to subcutaneous nasal swelling.

The histopathology from the biopsy specimen of the affected side is essential for a definitive diagnosis. The presence of broad aseptate hyphae with the Splendore–Hoeppli phenomenon is usually required for the diagnosis of conidiobolomycosis over mucormycosis in which the Splendore–Hoeppli phenomenon is rarely described [14].

Antifungal treatment with various combinations such as saturated potassium iodide solution, amphotericin B, cotrimoxazole, ketoconazole, itraconazole, and surgical debridement was found to be more effective with rapid effects [20].

## CONCLUSION

Rhinofacial conidiobolomycosis cases have been reported rarely. Due to its rarity and the lack of awareness, the diagnosis can be challenging. This infection may remain undiagnosed due to the lack of clinical suspicion. It should be considered one of the differential diagnoses in addition to nasal and paranasal sinus tumors for subcutaneous swelling in the rhinofacial region. The definitive diagnosis of rhinofacial conidiobolomycosis is based on a histopathological examination of skin lesions and a fungal culture for species identification. The awareness of this entity is important for early diagnosis and patient management which helps in reducing morbidity associated with disease. Early detection will be helpful in starting antifungal treatment which is rapid and effective in cases of rhinofacial conidiobolomycosis.

## REFERENCES

- Sigera LS, Janappriya GH, Lakshan MT, Pitigalage NJ, Jayasekera PI, Dayasena RP, *et al.* Rhinofacial conidiobolomycosis: A case series and review of the literature. *Ear Nose Throat J* 2021;100:835S-41.
- Chayakulkeeree M, Ghannoum MA, Perfect JR. Zygomycosis: The re-emerging fungal infection. *Eur J Clin Microbiol Infect Dis* 2006;25:215-29.
- Jain A, Rynga D, Singh PK, Chowdhary A. Rhinofacial conidiobolomycosis due to *Conidiobolus coronatus*: A case report and update of the disease in Asia. *Southeast Asian J Case Rep Rev* 2015;4:1576-89.
- Thomas MM, Bai SM, Jayaprakash C, Jose P, Ebenezer R. Rhinoentomophthoromycosis. *Indian J Dermatol Venereol Leprol* 2006;72:296-9.
- Richardson MD, Warnock DW. Entomophromycosis. In: Richardson MD, Warnock DW, editor. *Fungal Infection: Diagnosis and Management*. 3<sup>rd</sup> ed. UK: Blackwell Publishing; 2003. p. 293-7.
- Das SK, Das C, Maity AB, Maiti PK, Hazra TK, Bandyopadhyay SN. Conidiobolomycosis: An unusual fungal disease-our experience. *Indian J Otolaryngol Head Neck Surg* 2019;71:1821-6.
- Thotan SP, Kumar V, Gupta A, Mallya A, Rao S. Subcutaneous Phycomycosis--fungal infection mimicking a soft tissue tumor: A case report and review of literature. *J Trop Pediatr* 2010;56:65-6.
- Gugnani HC. Entomophthoromycosis due to *Conidiobolus*. *Eur J Epidemiol* 1992;8:391-6.
- Pfaller MA, Diekema DJ. Unusual fungal and pseudofungal infections of humans. *J Clin Microbiol* 2005;43:1495-504.
- Robinson CS, Robertson JT, Reed SM, Pinchbeck LR. Treatment of a mare for *Conidiobolus coronatus* infection. *Equine Vet Educ* 2007;19:396-403.
- Bras G, Gordon CC, Emmons CW, Prendegast KM, Sugar M. A case of phycomycosis observed in Jamaica; Infection with *Entomophthora coronata*. *Am J Trop Med Hyg* 1965;14:141-5.
- Klokke AH, Job CK, Warlow PF. Subcutaneous phycomycosis in India. Report of four patients with a review of the disease. *Trop Geogr Med* 1966;18:20-5.
- Chowdhary A, Randhawa HS, Khan ZU, Ahmad S, Khanna G, Gupta R, *et al.* Rhinoentomophthoromycosis due to *Conidiobolus coronatus*. A case report and an overview of the disease in India. *Med Mycol* 2010;48:870-9.
- Gupta N, Soneja M. Diagnosis and treatment of conidiobolomycosis: A review of 75 cases from the Indian subcontinent. *J Clin Diagn Res* 2019;13:OM1-3.
- Martinson FD, Clark BM. Rhinophycomycosis entomophthorae in Nigeria. *Am J Trop Med Hyg* 1967;16:40-7.
- Moisés-Hernández JF, Santamaria-Saad C, Reyes-Millan M, Furlong-Murillo A. Rhinofacial conidiobolomycosis, two cases in Mexican patients from rural and urban backgrounds. *Rev Méd Hosp Gen Méx* 2021;84:32-5.
- Dutta S, Sarkar S, Linka U, Dora S. Conidiobolomycosis: A case report of rare fungal infection from the Eastern India. *Indian Dermatol Online J* 2015;6:393-5.
- Deak L, Mudalagiriappa S, Ballin A, Saxton D, Chakrabarti A. A rhinofacial *Conidiobolus coronatus* fungal infection presenting as an intranasal tumour. *Sultan Qaboos Univ Med J* 2018;18:e549-52.
- Raju H. Conidiobolomycosis-A case report. *IOSR J Nurs Health Sci* 2020;9:28-31.
- Kimura M, Yaguchi T, Sutton DA, Fothergill AW, Thompson EH, Wickes BL. Disseminated human conidiobolomycosis due to *Conidiobolus lamprauges*. *J Clin Microbiol* 2011;49:752-6.

*Funding: Nil; Conflicts of interest: Nil.*

**How to cite this article:** Agale S, Rathi V, Tandale M. Unusual fungal infection of conidiobolomycosis presenting as nasal tumor – A case report. *Indian J Case Reports*. 2024; June 11 [Epub ahead of print].