

Synchronous multiple primary squamous cell carcinoma a rare entity

Anuna Laila Mathew¹, Biju Baby Joseph², M S Deepa², Preeja Premkumar², S Sunil³

From ¹Departments of Oral Medicine and Radiology and ³Department of Oral Pathology, Pushpagiri College of Dental Sciences, Thiruvalla, Kerala, India, ²Departments of Oral Medicine and Radiology, Azeezia College of Dental Sciences and Research, Kollam, Kerala, India

Correspondence to: Anuna Laila Mathew, Departments of Oral Medicine and Radiology, Pushpagiri College of Dental Sciences, Thiruvalla, Kerala, India. E-mail: drmathewdan@yahoo.co.in

Received - 30 August 2017

Initial Review - 27 September 2017

Published Online - 27 October 2017

ABSTRACT

Second primary tumor (SPT) develops due to extensive initiation and promotion by various carcinogens such as tobacco and alcohol, leading to a widespread disorder of the epithelial maturation and differentiation with a field effect. Therefore, environmental factors which cause the development of the first tumor can probably cause the subsequent premalignant and malignant changes. This article describes an unusual case of metachronous multiple primary squamous cell carcinomas in the oral mucosa in a chronic smoker and alcoholic and also discusses the clinical features and outcome of SPT.

Key words: Buccal mucosa, Carcinoma, Multiple, Primary, Synchronous carcinomas

Squamous cell carcinoma (SCC) of the oral cavity is a common malignancy and has one of the lowest 5 years survival rates among all cancers. New surgical techniques, improved radiotherapy and use of concomitant chemotherapy, have not improved the survival rate over the last decades [1,2]. Head and neck cancer patients are at high risk of developing second primary tumors (SPTs) arising from the same dysplastic mucosal field. It was Lund in 1993, who first reported the presence of SPT only in 6% of patients with oral SCC [2,3]. Risk for second cancer in patients with oral-maxillofacial malignancies varies between 1.8 and 4.3% and up to 30% [4]. Warren and Gates [5] were the first to publish the criteria for the diagnosis of a SPT. Field concretization explains SPT as a progression from one or multiple precancerous lesions in morphologically abnormal tissue surrounding the tumor site [6]. This article describes an unusual case of multiple primary SCC in the oral mucosa in a chronic smoker and alcoholic and also discusses the clinical features and outcome of SPT.

CASE REPORT

A 45-year-old male reported to our department with the chief complaint of swelling on the right cheek of 5 months duration. Initially, it was small in size which has gradually increased in size with associated pain since 1 week. Pain is intermittent, sharp, and moderate and it radiates to the side of the head. Pain is aggravated on eating from the same side. No history of bleeding, pus discharge, fever, weight loss, swelling elsewhere in the body, loss of appetite, loss of taste, trauma, paresthesia, and mobility or loss of teeth. Past medical and dental histories were noncontributory. He had a habit of smoking 8 beedies per day and

chewing betel quid 3 times per day for the 15 years. No history of alcohol consumption.

On examination, mouth opening was within the normal limits. Right submandibular lymph nodes were palpable, 2 in number, size 2 × 2 cm in size, hard, mobile, and tender. There was an ulcer-proliferative growth on the right buccal mucosa in the posterior region measuring around 3 × 2 cm in size (Fig. 1). Surface appears granular covered with whitish slough. No bleeding or pus discharge. A similar growth adjacent to the first growth at a gap of 1.5 cm extending into the buccal sulcus was present. The clinical appearance was similar to that of the first growth. Growth is mildly tender on manipulation, and the base was indurated. A provisional diagnosis of malignancy of the right buccal mucosa and right vestibular sulcus in the region of posterior teeth was made (T2 N1 M0).

Panoramic radiograph revealed no bony involvement (Fig. 2). Incisional biopsy was done, and histopathological report showed a well-differentiated invasive SCC. A wide excision was done under general anesthesia, and specimen was sent for histopathological examination. It showed dysplastic stratified squamous epithelium invading into the underlying moderately collagenous and vascular connective tissue. The invading islands of epithelium showed well differentiation, which confirmed the diagnosis of well-differentiated SCC (Fig. 3). The patient was referred to Radiotherapy and Oncology Department for further management. Chemotherapy with concomitant boost radiotherapy was planned. Chemotherapy of 2 cycles with cisplatin 150 mg and radiotherapy of 54 Gy 30 fractions over 6 weeks and 18 Gy over 12 fractions were planned. The patient had an uneventful post-operative and post radiotherapy period. The patient was followed for a period of 2 years without any symptoms and signs and was then he lost to follow-up.

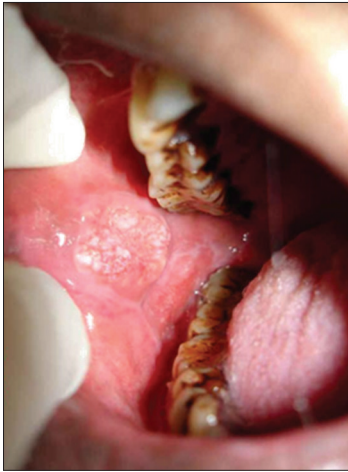

Figure 1: Intraoral photograph of lesion

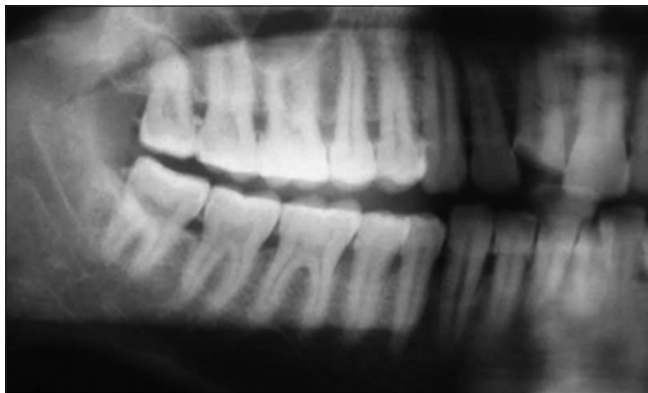


Figure 2: Orthopantomograph

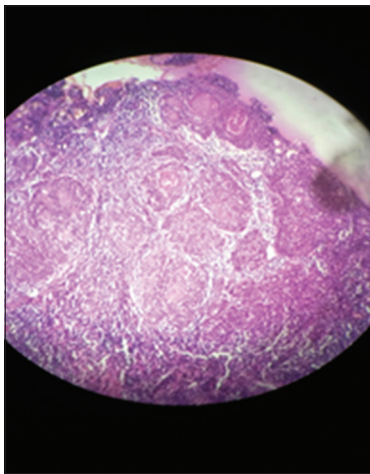


Figure 3: Photomicrograph showing the connective tissue with islands of invading epithelial cells which are well differentiated

DISCUSSION

Based on the time of diagnosis, multiple tumors can be classified into synchronous (diagnosed simultaneously or within 6 months after the diagnosis of the index tumor) or metachronous (diagnosed after a time interval of 6 months) [3]. Cancer developing at the site of the initial malignancy at any time after treatment is a recurrence, regardless of the length of follow-up. Warren and Gates [5] studied several cases of multiple primary tumors arising

from nonrelated sites and defined the criteria for a second primary carcinoma: Confirmation of malignancy in both tumors, each tumor must be distinct, and the second primary must be ruled out as metastatic spread from first cancer. The requirement for separation by normal non-neoplastic mucosa is at present often replaced by a distance of 2 cm [7].

Slaughter et al. in 1953, proposed the process of “field concretization,” referring to continuous exposure of the upper aerodigestive tract epithelium to unknown carcinogenic agents that lead to the development of multiple primary tumors [6]. For patients with carcinomas of the head and neck mucosal sites, the rates of developing synchronous and metachronous carcinomas range from 16 to 36%. SPT can share some or even all genetic markers with the index tumor, indicating that both tumors have arisen from a common clonal progenitor cell [9,10]. Patients with metachronous SPT located in the upper aerodigestive tract are thought to have a better prognosis than those with synchronous [11]. Cianfriglia et al. [3] reported that 90% of patients with synchronous oral SCCs are over than 40 years of age. About 40% of the second malignancies of the upper aerodigestive tract arise simultaneously and represent a synchronous tumor.

The 5 years survival rate decreases in patients with multiple primary tumors. Development of synchronous and metachronous SCC of the head and neck mucosal sites are in part responsible for justifying frequent follow-up and studies on chemoprevention. Despite marked improvements in locoregional control of head and neck SCC over the past 40 years, the overall 5 years survival rate has not changed since the 1960s, ranging from 40 to 50% and even that locoregional recurrence and distant metastasis collaborate to the low survival rate, the development of SPT also contributed with significant negative impact on the prognosis. Hence, patients treated for SCC require a long-term follow-up.

CONCLUSION

Our case did not show any signs or symptoms during the 2 years follow-up period so it can be assumed that with proper dietary modification, with stoppage of inadvertent habits along with the immunity might have contributed for the good prognosis of the lesion. However, a systematic follow-up protocol should be planned for such cases on a long duration basis which can contribute to the prognosis.

REFERENCES

1. Escher A, Piotet E, Waridel F, Iggo R, Monnier P. P53 Mutation in histologically normal mucosa of the aero-digestive tract is not a marker of increased risk for second primary carcinoma in head and neck cancer patients. *Eur Arch Otorhinolaryngol.* 2009;266(4):547-51.
2. Lund CC. Second primary cancers in cases of cancer of the buccal mucosa. *N Engl J Med.* 1933;209:1144-9.
3. Cianfriglia F, Gregorio DA, Manieri A. Multiple primary tumors in patients with oral squamous cell carcinoma. *Oral Oncol.* 1999;35:157-63.
4. Friedrich RE. Primary and second primary cancer in 649 patients with malignancies of the maxillofacial region. *Anticancer Res.* 2007;27(4A):1805-18.
5. Warren S, Gates O. Multiple primary malignant tumors. A survey of the

- literature and a statistical study. Am J Cancer. 1932;16:1358-414.
6. Slaughter DP, Southwick HW, Smejkal W. Field concretization in oral stratified squamous epithelium. Cancer. 1953;6:963-8.
 7. Thomson PJ, Hamadah O. Cancerisation within the oral cavity: The use of field mapping biopsies in clinical management. Oral Oncol. 2007;43(1):20-6.
 8. van der Waal I, de Bree R. Second primary tumours in oral cancer. Oral Oncol. 2010;46(6):426-8.
 9. Priante AV, Castilho EC, Kowalski LP. Second primary tumors in patients with head and neck cancer. Curr Oncol Rep. 2011;13(2):132-7.
 10. Liao CT, Kang CJ, Chang JT, Wang HM, Ng SH, Hsueh C, et al. Survival of second and multiple primary tumors in patients with oral cavity squamous cell carcinoma in the betel quid chewing area. Oral Oncol. 2007;43(8):811-9.
 11. Jégu J, Binder-Foucard F, Borel C, Velten M. Trends over three decades of the risk of second primary cancer among patients with head and neck cancer. Oral Oncol. 2013;49(1):9-14.

Funding: None; Conflict of Interest: None Stated.

How to cite this article: Mathew AL, Joseph BB, Deepa MS, Premkumar P, Sunil S. Mucoepidermoid carcinoma of palate - A rare entity. Indian J Case Reports. 2017;3(4):261-263.