

## Interpectoral tuberculous lymphadenitis masquerading as carcinoma breast: A case report

Nisha Hariharan<sup>1</sup>, T Subramanyeshwar Rao<sup>2</sup>, Chandra C K Naidu<sup>3</sup>, Sudha M Murthy<sup>4</sup>, Anjaneyulu Vasala<sup>5</sup>, Veeraiah Koppula<sup>6</sup>, Basanthkumar Rayani<sup>7</sup>, Krishnakumar Dayanand<sup>5</sup>

From <sup>1</sup>Consultant Breast Oncosurgeon, <sup>2</sup>Medical Director and Chief Surgical Oncologist, <sup>3</sup>Senior Consultant, Breast Oncoplastic Surgeon, Departments of <sup>4</sup>Pathology, <sup>5</sup>Pathology, <sup>6</sup>Radiology, <sup>7</sup>Anaesthesiology, Basavatarakam Indo American Cancer Hospital and Research Institute, Hyderabad, Telangana, India

**Correspondence to:** Dr. T Subramanyeshwar Rao, Basavatarakam Indo American Cancer Hospital and Research Institute, Road No. 10, Banjara Hills, Hyderabad - 500 034, Telangana, India. Phone: +91-9848038716. E-mail: subramanyesh@gmail.com

Received - 19 July 2017

Initial Review - 17 August 2017

Published Online - 27 September 2017

### ABSTRACT

Carcinoma of the breast is showing a rising trend in India and is an important diagnosis in an elderly postmenopausal lady presenting with a breast mass. Clinical assessment and mammography are the initial diagnostic tools. Unfortunately, in India, tuberculosis (TB) continues to remain an important public health problem. While mammary TB is relatively rare and has traditionally been described in young lactating multiparous women, this clinical picture can at times be misleading. TB is known to be a great masquerade, and TB granulomatous mastitis often mimics malignancy in the breast. An accurate diagnosis is essential as the treatment for these two entities is entirely different. We present a case of a breast lump in an elderly postmenopausal lady, which at the time of surgery, proved to be a caseating TB interpectoral node.

**Key words:** Carcinoma breast, Masquerading, Tuberculous lymphadenitis

Mammary tuberculosis (TB) is a relatively rare condition comprising only 0.4% of all breast lesions. Until 1982, over 500 cases were reported in the world literature [1]. Since then, sporadic case reports have added to that number. Çakar and Çiledag evaluated consecutive patients treated for TB in an 8 year period from 2006 to 2013. They suggested that the incidence of mammary TB constituted 1.08% of all the patients diagnosed [2]. In India, recent reports have found the incidence of this entity to be 3-4.5% of all surgically treated breast lesions [1,3,4].

Clinically, mammary TB can present in the nodular, sclerozing or disseminated form. While the disseminated variety has pathognomonic multiple discharging sinuses in the breast, the nodular and sclerozing variety closely resemble breast malignancy in their clinical presentation. Often, even the radiology and imaging of these lesions can be indistinguishable from malignancy. In this aspect, mammary TB can be difficult to distinguish from other benign or malignant lesions in the breast.

### CASE REPORT

A 71-year-old lady presented to our outpatient department with a recently detected painless left breast lump. Clinically, there was a single, firm, mobile 3 cm lump at the 3 o'clock position on the left breast. The overlying skin was normal. The ipsilateral axilla

had a single discrete mobile 1.5 cm sized node. The contralateral breast, axilla, and supraclavicular fossa were unremarkable.

A bilateral digital mammogram revealed a lobulated lesion in the super lateral quadrant of the left breast (Figs. 1 and 2). The corresponding ultrasound demonstrated a 4.4 cm × 2.1 cm sized well defined hyper echoic lesion with internal necrotic foci at the 2 o'clock position - classified as breast imaging reporting and data system 4b. Furthermore, a 2 cm sized heterogeneously hypo echoic lesion was seen in the deeper plane of the axillary tail, which appeared to be a metastatic node. The ultrasound guided core biopsy was reported as necrotizing mastitis. Her chest X-ray and routine blood investigations were normal.

The clinical picture and the mammography features were strongly in favor of malignancy. In view of the high index of clinical suspicion, she was planned for an excision biopsy of the left breast lump under general anesthesia. The same was discussed and explained to the patient and consent was obtained.

A radial incision was taken directly over the palpable lump on the left breast. As the lumpectomy proceeded, the base of the lump was seen extending as a tortuous tract. It tracked behind the pectoralis major muscle into the interpectoral space. On further dissection, it appeared to dip in-between the fibers of the pectoralis minor. The dissection was carried down to the surface of the rib. However, the surface of the rib and the underlying pleura was grossly free of disease. The entire lump with the necrotic tortuous extension was dissected into and sent

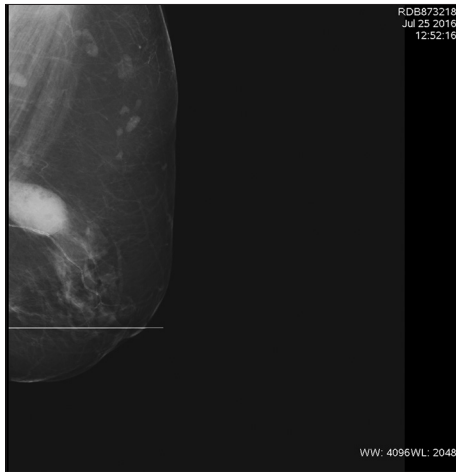

Figure 1: Mammography mediolateral oblique view

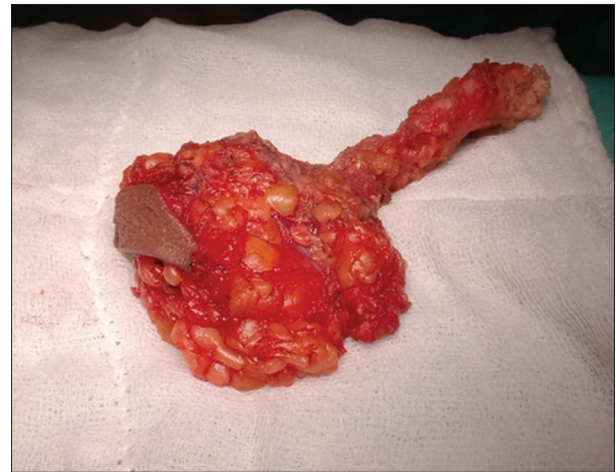


Figure 3: Intra-operative specimen

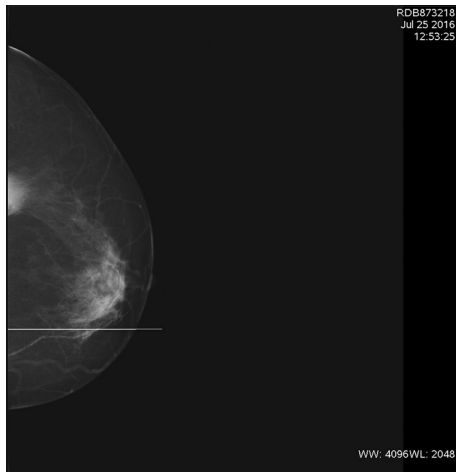


Figure 2: Mammography craniocaudal view

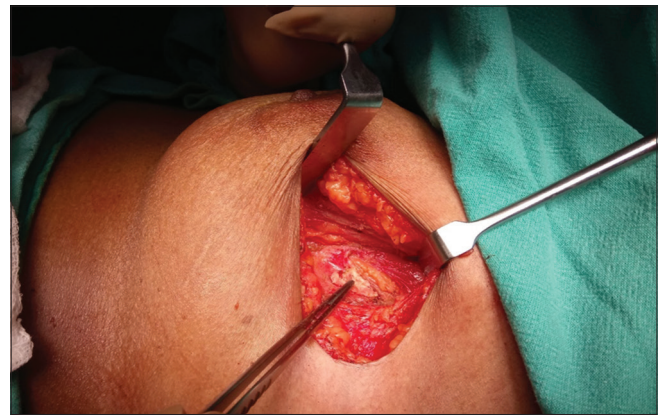


Figure 4: Intra-operative view

for histopathology review (Figs. 3 and 4). The post-operative recovery was uneventful. On gross examination of the specimen, there was a 2 cm × 2 cm gray white nodular lesion. The sinuous part of the specimen consisted entirely of a matted lymph node (Fig. 5). On microscopy, the sections showed breast parenchyma with multiple granulomatous lesions consisting of lymphocytes, macrophages, epithelioid cells, and giant cells admixed with areas of caseating necrosis. Sections from the matted lymph node exhibited similar morphology with multiple granulomata and extensive caseating necrosis. Based on these findings, the final impression was granulomatous mastitis with granulomatous lymphadenitis most likely of Koch's etiology.

To rule out any cold abscess tracking down from the spine, a post-operative computed tomography thorax was done. The spine and ribs were completely normal. The underlying lung showed old infective changes. No active TB lesion was seen. Her sputum test was negative. She was put under the care of a pulmonologist at our institute and was started on anti-TB medication. She received a four drug regimen for 2 months (rifampicin, isoniazid, pyrazinamide, and ethambutol) followed by a two drug regimen for 4 months (rifampicin and isoniazid). At 12 months follow-up, the wound has healed entirely, and the patient was asymptomatic.

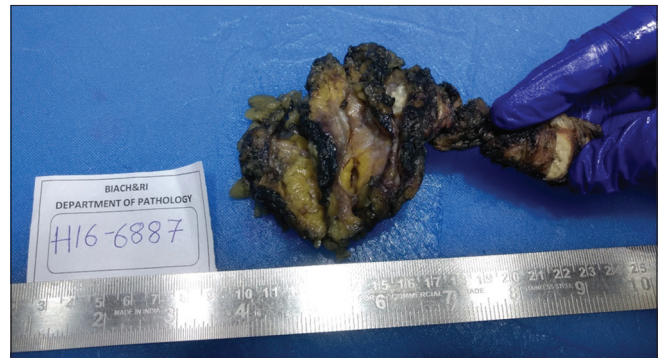

Figure 5: Histopathology gross specimen

**DISCUSSION**

Mammary TB is usually secondary to a focus in the underlying ribs or lungs or mediastinum. The spread can be contiguous or hematogenous. There are reports of cold abscesses tracking down from the spine along the ribs to present as a lump in the breast [5]. However, it is very rare for an interpectoral node to be the sole site of involvement. The caseation of an interpectoral node presenting as a breast malignancy is clinically challenging to diagnose. In the absence of any demonstrable focus in the body, mammary TB is considered to be primary in origin. It is speculated that this variety could be due to infection passed on from suckling infants

through the duct openings in the nipple. Consequently, mammary TB is more common in multiparous women in the child bearing age group. The current classification of TB mastitis includes three variants - nodulocaseous, disseminated, and tubercular breast abscess [6]. As observed by Khanna et al. [3], in their series of 52 patients, the classic presentation of lump associated with sinus is seen in 39% patients, isolated breast lump in 23%, sinus without a lump in 12%, and tender nodularity in 23% patients.

Shinde et al., in their series of 100 patients observed that a lump with or without ulceration was the most common presentation. Furthermore, one-third of the patients may have associated palpable axillary nodes [7]. This resemblance to carcinoma in clinical presentation necessitates a histological confirmation of the absence of malignancy before instituting tubercular treatment. Mammography or ultrasound may be misleading in differentiating between TB and carcinoma of the breast. A fine-needle aspiration cytology or core biopsy can be attempted, but if the index of suspicion is high, and excision biopsy can confirm the diagnosis effectively. Caseous epithelioid granulomas with Langhan's giant cells with lymphohistiocytic aggregates are characteristic of mammary TB. Other possible differential diagnoses for granulomatous mastitis include idiopathic granulomatous mastitis, fat necrosis, giant cell arteritis, actinomycosis, sarcoidosis, and Wegener's granulomatosis [8]. Mycobacterial culture, the gold standard for the diagnosis of TB is often negative due to the paucibacillary nature of mammary TB [7]. Mammary TB responds well to a conservative line of management with anti-TB medications. In their series of 100 patients, Shinde et al. [7] reported a simple mastectomy rate of 14%. The common reasons for surgical intervention include lack of response to anti-tubercular medications or large painful ulcers or sinuses.

## CONCLUSION

TB mastitis continues to remain an important differential diagnosis for a woman presenting with a breast lump, especially in endemic countries. Although it is rare in an elderly postmenopausal woman, it should be kept in mind as a differential diagnosis for a breast lump with an atypical presentation. The clinical and radiological features can mimic malignancy and therefore, a histological confirmation of the same is a must before instituting treatment.

## REFERENCES

1. Hamit HF, Ragsdale TH. Mammary tuberculosis. *J R Soc Med.* 1982;75(10):764-5.
2. Çakar B, Çiledag A. Retrospective analysis of seven breast tuberculosis cases. *Exp Ther Med.* 2016;12(5):3053-7.
3. Khanna R, Prasanna GV, Gupta P, Kumar M, Khanna S, Khanna AK. Mammary tuberculosis: Report on 52 cases. *Postgrad Med J.* 2002;78(921):422-4.
4. Tiwari VS, Agarwal A, Singh PK, Upadhyaya GC. Tuberculosis of the breast. *Indian J Tuberc.* 1990;37(3):149-50.
5. Chowdri NA, Fazl QP, Rayees AD, Ajaz AM, Majid M, Rais AM. Tubercular mastitis - A rare presentation. *Int J Surg.* 2010;8(5):398-400.
6. Tewari M, Shukla HS. Breast tuberculosis: Diagnosis, clinical features and management. *Indian J Med Res.* 2005;122(2):103.
7. Shinde SR, Chandawarkar RY, Deshmukh SP. Tuberculosis of the breast masquerading as carcinoma: A study of 100 patients. *World J Surg.* 1995;19(3):379-81.
8. Sen M, Canan G, Bozer M. Isolated Primary Breast Tuberculosis: Report of 3 cases and review of literature. *Clinics.* 2009;64(6):607-10.8.

*Funding: None; Conflict of Interest: None Stated.*

**How to cite this article:** Hariharan N, Rao S, Naidu CCK, Murthy SM, Vasala A, Koppula V, Rayani B, Dayanand K. Interpectoral tuberculous lymphadenitis masquerading as carcinoma breast: A case report. *Indian J Case Reports.* 2017;3(4):224-226.