

## Umbilical discharge - An extremely rare presentation

Ipseet Mishra<sup>1</sup>, Sudip Haldar<sup>2</sup>, Souvik Paul<sup>3</sup>, Purnendu Dutta<sup>4</sup>

From Departments of <sup>1</sup>Gastrointestinal Oncology, <sup>2</sup>Surgical Oncology, Saroj Gupta Cancer Centre and Research Institute, <sup>4</sup>Department of Surgical Gastroenterology, Institute of Postgraduate Medical Education and Research and Seth Sukhlal Karnani Memorial Hospital, Kolkata, West Bengal, <sup>3</sup>Department of Gastroenterology, BLK Super Speciality Hospital, New Delhi, India

**Correspondence to:** Dr. Ipseet Mishra, T33/7G, Genexx Valley, Joka, Kolkata -700104, India. E-mail: drimishra13@gmail.com

Received - 26 June 2017

Initial Review - 15 July 2017

Published Online - 16 August 2017

### ABSTRACT

Umbilical discharge and dermoid cyst of ovary are quiet commonly encountered problems in the outpatient departments. However, dermoid cyst presenting as a cause of umbilical discharge is extremely rare, and we could find only one case reported in literature so far. A 20-year-old lady presented with painful umbilical swelling and purulent discharge from umbilicus for the last 2 months. A 1 cm×2 cm sprouting granulation tissue with purulent discharge was found at the umbilicus with surrounding erythema. The dilemma in diagnosis was not resolved with routine investigations and imaging studies. On surgical exploration, a fistulous tract was found extending from the umbilicus to the enlarged right ovary. The diagnosis of benign teratoma of ovary with sinus tract up to umbilicus was made on histopathology. The rarity of this case makes its reporting further relevant, considering the differential diagnosis of umbilical discharge or presentations of dermoid cyst of ovary.

**Key words:** *Dermoid cyst of ovary, Fistulation, Infected teratoma of ovary, Umbilectomy, Umbilical discharge, Oophorectomy*

Umbilical discharge with its varied etiological factors is quiet a commonly encountered problem in outpatient departments (OPD). Similarly, dermoid cyst of ovary is also a familiar entity. Interestingly, dermoid cyst had been reported with its complications such as torsion, malignant transformation or fistulation into bladder, small bowel, rectum, sigmoid colon, vagina, and peritoneal cavity [1]; however, its presentation as a cause of umbilical discharge is extremely rare. This is the second case been reported in literature so far [2].

### CASE REPORT

A 20-year-old lady presented in the surgery OPD of Calcutta National Medical College and Hospital, with painful umbilical swelling and purulent discharge from umbilicus for the last 2 months. There were occasional episodes of fever without chills and rigor. Bowel and bladder habits were normal. No history of tuberculosis or any surgical procedures were evident previously. Her parents, the informants, also revealed she had primary amenorrhea. She had profound mental retardation (pronouncing only syllables), height - 117 cm and weight - 38 kg on presentation. A 1 cm× 2 cm sprouting granulation tissue with discharging pus was found at the umbilicus with surrounding erythema. Other systemic examinations were unremarkable.

Routine investigations were unyielding. Gram stain, acid fast bacilli stain and culture and sensitivity of purulent discharge did not show any microorganism. Thyroid stimulating hormone on presentation was 23. 6 µIU/ml and was optimized with

tab. Levothyroxine 100 µg once a day. On ultrasonography, there was a complex heterogeneous cystic lesion noted from umbilicus to right side of urinary bladder with thick echogenic wall, internal fluid, few calcifications, and low internal echoes. Contrast enhanced computed tomography scan of whole abdomen suggested a pocket of collection in the right paraumbilical level extending to umbilicus (Fig. 1). Upper gastrointestinal contrast study, barium enema and cystoscopy ruled out any possible hollow viscus communications with umbilicus. The dilemma in diagnosis was not resolved since the imaging studies could not localize any index anatomical structure involved. Fistulogram was not done keeping in mind the diagnosis of intra-abdominal abscess [3] and surgical exploration was thus scheduled.

After taking proper consent from the parents, a transverse incision was made encircling the umbilicus under general anesthesia (Fig. 2). On exploration, a fistulous tract 10 cm long was found extending from the umbilicus to the enlarged 4 cm×6 cm right ovary (Fig. 3). Cut section of the ovary exhibited thickened walls containing greasy material with tuft of hair (Fig. 4). Umbilectomy with right sided oophorectomy was done along with complete excision of the fistulous tract. Histopathological examination unveiled cyst wall lined with dermoid component, ovarian follicle, bony trabeculations, and glandular components (in 10× hematoxylin and eosin stain) (Figs. 5-7). The sinus tract was lined by lymphocytes, macrophages, and other chronic inflammatory cells (Fig. 8). The diagnosis of benign teratoma of ovary with sinus tract up to umbilicus was made. The patient

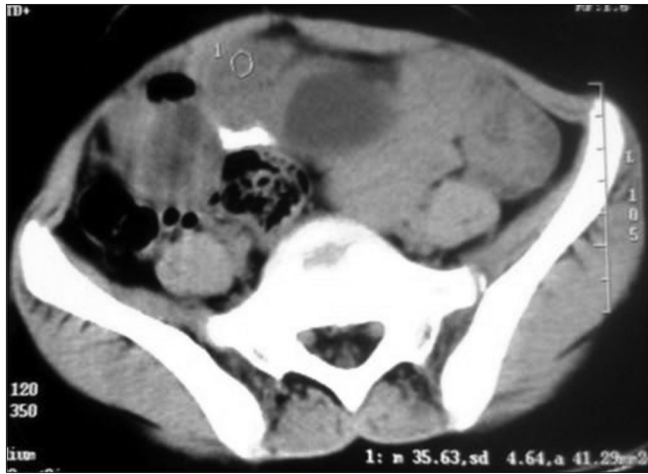

Figure 1: Computed tomography scan whole abdomen showing a pocket of collection in the right paraumbilical level extending to umbilicus

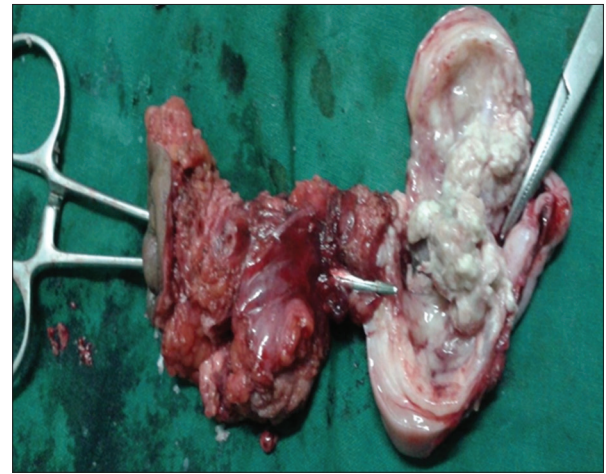


Figure 4: Illustration showing cut section of the ovary with thickened walls, greasy material and tuft of hair. The fistulous tract has been probed by artery forceps

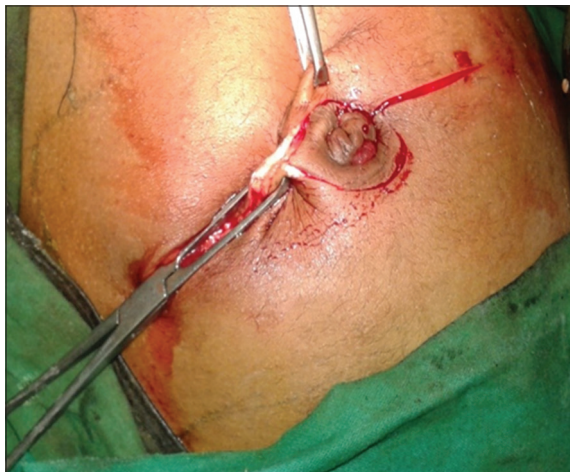

Figure 2: Intraoperative illustration showing transverse incision encircling the umbilicus

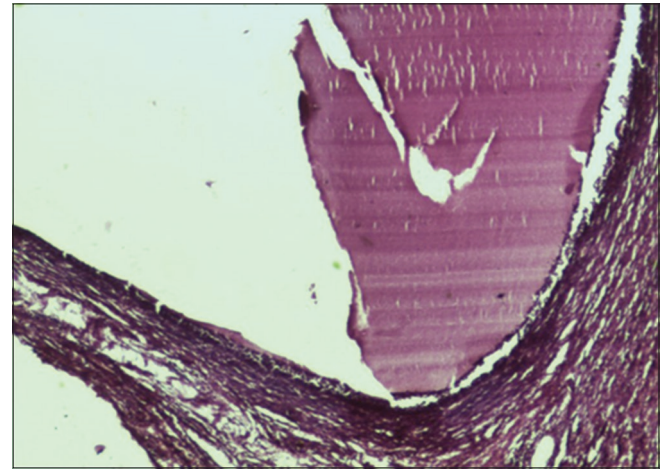


Figure 5: Histopathological examination showing ovarian follicle lining (in 10x hematoxylin and eosin stain)

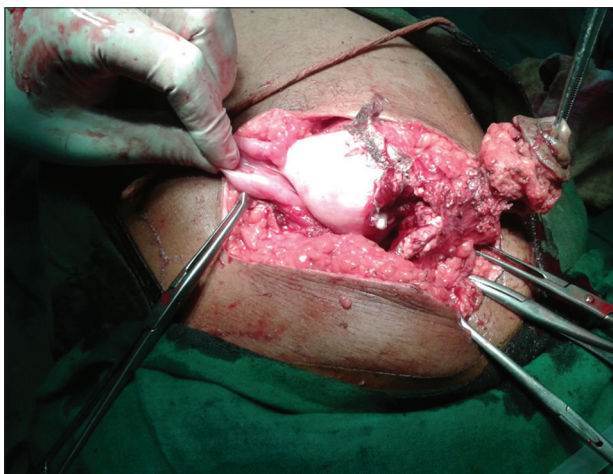


Figure 3: Intraoperative illustration showing a fistulous tract 10 cm long found extending from the umbilicus to the enlarged 4 cm×6 cm right ovary

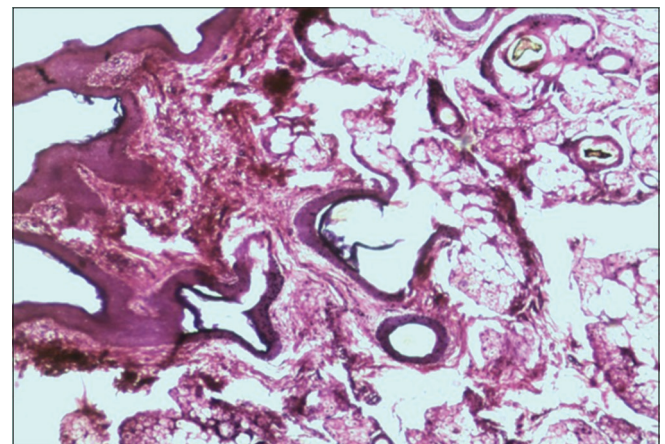
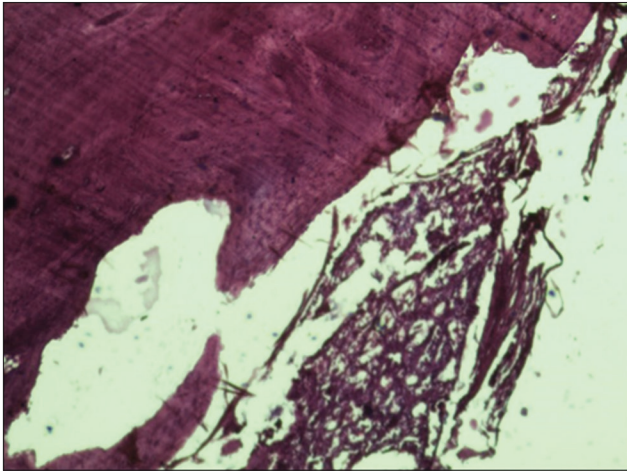


Figure 6: Histopathological examination showing cyst wall lining with dermoid component (in 10x hematoxylin and eosin stain)

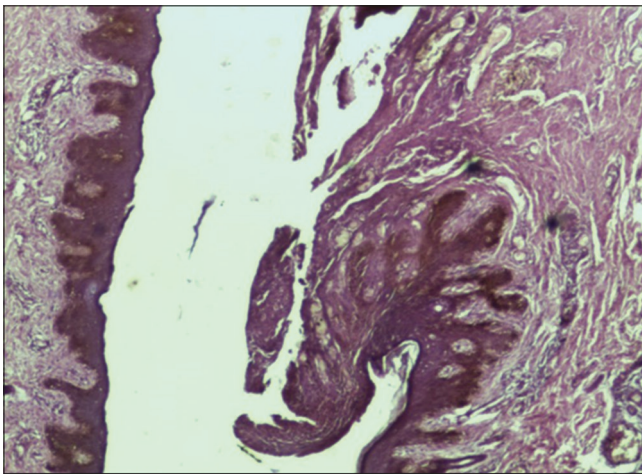
recovered uneventfully in post-operative period and had been monitored for the past 3 years without the need of any further treatment.

**DISCUSSION**

Benign teratoma of the ovary, also called dermoid cysts are the most common type of benign ovarian tumors accounting for 10-20% of all ovarian neoplasm. They mostly present as asymptomatic



**Figure 7:** Histopathological examination showing bony trabeculations and glandular component (in 10x hematoxylin and eosin stain)



**Figure 8:** Histopathological examination showing sinus tract (in 10x hematoxylin and eosin stain)

adnexal mass or are discovered on routine abdominopelvic examination or during imaging studies. Although reported with complications, e.g., torsion (16%) and malignant transformation (2%), fistulation (1%) have been rare mainly due to the thick wall of the cyst [3,4]. The hypotheses for fistulation suggests either rupture of cyst wall from ischemic necrosis by complete torsion of cyst or inflammatory adhesions from incomplete torsion or from malignant infiltration [5]. Even fistulation of ovarian dermoid cyst into bladder, small bowel, rectum, sigmoid colon, vagina, and peritoneal cavity [1,4-6] has been previously reviewed, but its

presentation as a cause of umbilical discharge has been reported in literature only once by Choudhary et al. [2].

Although persistent umbilical discharge can be attributed to varied reasons such as patent urachus or vitello-intestinal duct, tuberculosis, post-surgery, superficial infections such as omphalitis or umbilical hernia ulceration and intra-abdominal malignancies or abscesses [3], dermoid cyst of ovary as its etiology is very unusual.

## CONCLUSION

The rarity of this case makes its reporting further relevant, considering the differential diagnosis of umbilical discharge or presentations of dermoid cyst of ovary.

## ACKNOWLEDGMENTS

We thank the faculty members of the Department of General Surgery and Department of Pathology, Calcutta National Medical College and Hospital, for assistance with the patient's examination and treatment.

## REFERENCES

1. Upadhye V, Gujral S, Maheshwari A, Wuntkal R, Gupta S, Tongaonkar H. Benign cystic teratoma of ovary perforating into small intestine with coexistent typhoid fever. *Indian J Gastroenterol.* 2005;24(5):216-7.
2. Choudhary A, Shukla S, Nawlakhey P, Jain R, Koshariya M. Spontaneous discharging umbilical sinus secondary to infected cystic teratoma ovary An atypical presentation. *J Clin Diagn Res.* 2014;8(4):ND05-6.
3. Martin M, Lembo R. A 17-year-old boy with umbilical discharge; 2004. Available from: [http://www.turnerwhite.com/memberfile.php?PubCode=hp\\_may04\\_boy.pdf](http://www.turnerwhite.com/memberfile.php?PubCode=hp_may04_boy.pdf). [Last accessed on 2017 Jul 17].
4. Sardesai S, Raghoeji V, Dabade R, Shaikh H. Benign cystic teratoma of ovary perforating into the urinary bladder a rare case. *J Obstet Gynaecol India.* 2012;62 Suppl 1:54-5.
5. Conway AZ, Hanna T. A dermoid cyst fistulating with the transverse colon. *Ann R Coll Surg Engl.* 2012;94(7) e230-1.
6. von-Walter AR, Nelken RS. Benign cystic ovarian teratoma with a fistula into the small and large bowel. *Obstet Gynecol.* 2012;119:434-6.

*Funding: None; Conflict of Interest: None Stated.*

**How to cite this article:** Mishra I, Halder S, Paul S, Dutta P. Umbilical discharge - An extremely rare presentation. *Indian J Case Reports.* 2017; 3(4):187-189.