

Adenomatoid odontogenic tumor in anterior maxilla: A case report

V Gopalakrishnan¹, N S C Charles², Amolika Choube³

From ¹Consultant, Department of Oral and Maxillofacial Surgery, ²Consultant, Department of Oral Pathology, Microbiology and Forensic Odontology, New Delhi, ³Consultant, Department of Oral Pathology, Microbiology and Forensic Odontology, Bikaner, Rajasthan, India

ABSTRACT

Adenomatoid odontogenic tumor (AOT) is an uncommon benign lesion of odontogenic origin. This tumor mainly affects young individuals in the second decade with a female predilection and is most commonly located in the anterior maxilla, usually associated with an impacted canine tooth. The aim of this report is to discuss the case of a 24-year-old female with AOT in the maxillary incisor region and includes the surgical management of the case.

Key words: Anterior maxilla, Benign tumor, Jaw swelling, Odontogenic tumor

Adenomatoid odontogenic tumor (AOT) is an uncommon benign lesion of odontogenic epithelial origin characterized by the clinical presentation of absent or impacted teeth, absence of pain, expansion of bone, and deformity of the face as the lesion develops and grows [1]. This was first described by Dreibaldt in 1907 as a pseudo-adenameloblastoma [2,3], and terms such as adenoameloblastoma, ameloblastic adenomatoid tumor, adamantinoma, or teratomatous odontoma have been used to define the lesion which is currently known as AOT. The term AOT was introduced by Philipsen and Birn and later adopted by the World Health Organization (WHO) in 2005 [4]. AOT was initially classified by the WHO as a mixed odontogenic neoplasm because it sometimes contains dental hard tissue formed by interactions between the dental epithelium and mesenchyme. At present, AOT is classified as an epithelial tumor without odontogenic ectomesenchyme and has an overall distinctive histomorphology, which exhibits a remarkable consistency making its diagnosis easy and non-ambiguous [4-6]. It represents 3-7% of all odontogenic tumors. AOT mostly occurs in patients between 10 and 30 years [3,6,7]. It has a tendency to occur in the anterior portion of the jaws (95%) and is found twice as often in the maxilla (65%) than in the mandible. Females are affected about twice as often when compared to males [7-9].

Due to the benign nature of the lesion and its very low recurrence rate, extensive surgery is not indicated. The surgical management of this lesion would be enucleation along with the associated impacted tooth; because of its capsule, it enucleates easily from the bone [7]. This report presents the case of a 24-year-old female with AOT in the anterior region of the maxilla

involving maxillary incisors, which was surgically managed along with enucleation of the lesion.

CASE REPORT


A 24-year-old female reported to the Department of Oral and Maxillofacial Surgery with a chief complaint of an asymptomatic swelling in the maxillary anterior region for 6 months.

The patient was well oriented to time, place, and person and with no pallor, icterus, clubbing, cyanosis, and organomegaly. Her vital signs were within normal limits. On extraoral examination, the swelling was diffuse, non-lobulated, non-tender, about 3 × 3 cm in size, and was not fixed to the overlying skin in the anterior region of the maxilla. Intraoral examination revealed a soft fluctuant swelling extending in the maxillary anterior region, obliterating the buccal vestibule (Fig. 1).

The surgical procedure was planned for the patient. After injection of 4 ml local anesthetic with 1:80000 adrenaline in the buccal mucosa, a full-thickness flap was raised. The lesion was exposed and was removed in toto. Peripheral osteotomy was done and a bone graft was placed in the defect. Suturing was done with 3-0 vicryl. Extraction of the left maxillary central and lateral incisor was done. The tissue, measuring 2 cm × 1.5 cm × 1.5 cm, attached to the incisors was sent for histopathological examination (Fig. 2a).

Histopathologic examination showed a circumscribed lesion comprising variably sized epithelial nests with peripheral palisading of tall columnar cells and central cystic space along with occasional stellate cells, suggestive of AOT (Fig. 3).

The mucoperiosteal flap was raised in the maxillary anterior region followed by the extraction of incisors. The management of the lesion was done with enucleation of tumor (Fig. 2b).

Access this article online	
Received - 07 May 2023 Initial Review - 18 May 2023 Accepted - 30 September 2023	Quick Response code 
DOI: 10.32677/ijcr.v9i10.4031	

Correspondence to: Amolika Choube, MIG 576 Dhanvantari Nagar, Jabalpur - 482 003, Madhya Pradesh, India. E-mail: amol2918@gmail.com

© 2023 Creative Commons Attribution-NonCommercial 4.0 International License (CC BY-NC-ND 4.0).

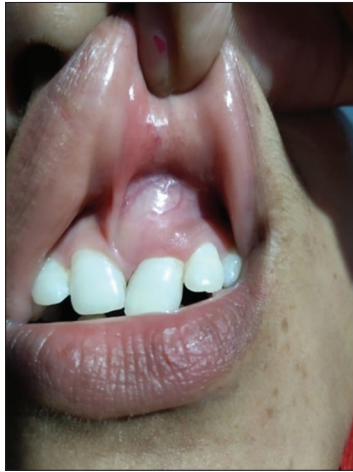

Figure 1: Intraoral examination showing soft fluctuant swelling extending in the maxillary anterior region, obliterating the buccal vestibule

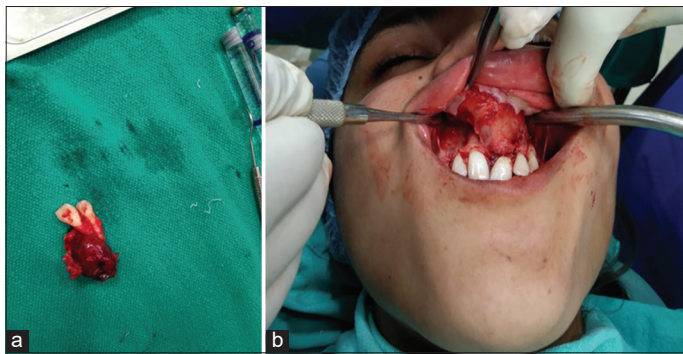


Figure 2: (a) Excisional biopsy specimen for histopathological examination; (b) intraoperative image showing enucleation of tumor

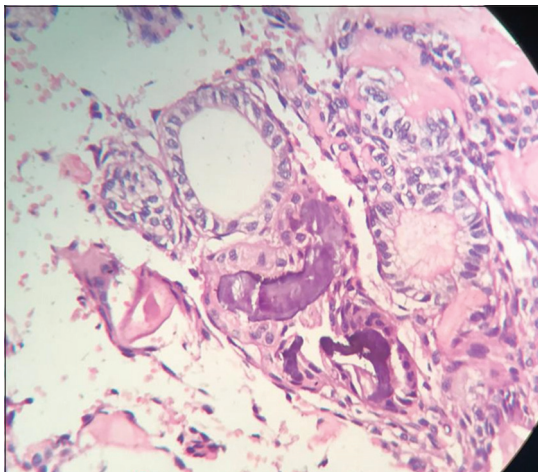


Figure 3: Photomicrograph with features suggestive of adenomatoid odontogenic tumor

DISCUSSION

The AOT is a slow-growing and relatively rare lesion, constituting only 3% of all odontogenic tumors and 0.1% of jaw tumors in general with a predilection for the anterior maxilla (ratio 2:1 relative to mandible). It is usually associated with impacted canines of females in the second decade of life [3,6-10]. AOT is an uncommon cause of jaw swelling. The lesions are usually

asymptomatic but may be associated with cortical expansion. The involved teeth are commonly impacted and adjacent teeth may be slightly displaced [11]. Root resorption is not a usual feature.

AOT is a benign, non-aggressive epithelial tumor that exhibits slow but progressive growth and is derived from the epithelial component of the tooth-forming tissues. None of the associated teeth were described as morphologically defective [12,13]. Stafne originally suggested that the cell of origin was that of the epithelium entrapped in the line of embryonic fusion, but the current belief is that it originates from the odontogenic epithelium of the dental lamina complex or its remnants [14].

Tumor has three clinicopathologic variants, namely intraosseous follicular, intraosseous extrafollicular, and peripheral. The extrafollicular type (24%) has no relation with an impacted tooth, whereas the follicular type (73%) is associated with an unerupted tooth and the peripheral variant (3%) is attached to the gingival structures. Peripheral type (3%) usually presents as a gingival swelling and often appears as small sessile masses on the buccal maxillary gingiva. Clinically, these lesions cannot be differentiated from the common gingival fibrous lesion [7].

Radiographically, AOT has two variants, that is, follicular and extrafollicular type. The follicular variety shows a well-defined, unilocular (round or ovoid) radiolucency associated with either the crown of the tooth, the root, or the whole tooth [15]. It may mimic a dentigerous cyst or, in the presence of scattered radiopacities, a calcifying epithelial odontogenic tumor. In the presence of the radiopaque foci, the differential diagnosis should also include fibrous dysplasia, Pindborg tumor, ameloblastic fibroma, and dentinogenic ghost cell tumor. Hence, radiographic differentiation of such odontogenic lesions becomes a difficult task. Diagnosis can be established by careful analysis of the site of the lesion, its borders, the effect of the lesion on adjacent structures, cortical expansion, cortical erosion, root divergence, root resorption, and calcific bodies in radiographs.

Histologically, all variants of AOT show a consistent and identical picture. They are characterized by odontogenic epithelium with duct-like structures with varying degrees of inductive changes in the connective tissue [5]. Dystrophic calcification, osteodentin, and cementum-like substances have been reported by some authors, whereas the occurrence of enamel matrix is extremely rare [5].

Due to its benign behavior, slow growth, and well-encapsulated delimitation, the treatment of choice is conservative surgical enucleation and simple curettage. However, in exceptional cases of large tumors or risk of bone fracture, partial resection or *en bloc* of the mandible or maxilla has been indicated. Conservative treatment is adequate because tumor is not locally invasive, is well encapsulated, and can be easily separated from the bone. The surgical specimen may be solid or cystic. The recurrence rate is as low as 0.2%. In this case, enucleation was done along with the extraction of the maxillary central and lateral incisors. Follow-up after the surgery was done and no recurrence was noted after 6 months.

CONCLUSION

AOTs are usually asymptomatic lesions that sometimes may cause cortical expansion and displacement of the adjacent teeth. The rarity and slow-growing nature of the lesion makes it difficult to diagnose. Early diagnosis by the dental surgeon is mandatory when clinical signs are suggestive of AOT, and early enucleation prevents excessive destruction of bone.

ETHICAL APPROVAL

The ethical clearance certificate was obtained from the institutional ethical committee as per the standard guidelines.

REFERENCES

- Santos JN, Pinto LP, de Figueredo CR, de Souza LB. Odontogenic tumors: Analysis of 127 cases. *Pesqui Odontol Bras* 2001;15:308-13.
- Lucas RB. *Pathology of Tumors of the Oral Tissues*. 4th ed. Edinburgh, Scotland: Churchill Livingstone; 1984.
- Batra P, Prasad S, Prakash H. Adenomatoid odontogenic tumor: Review and case report. *J Can Dent Assoc* 2005;7:250-3.
- Kramer IR, Pindborg JJ. *Histological Typing of Odontogenic Tumours, Jaw Cysts and Allied Lesions*. Berlin: Springer, Verlag; 1971.
- Philipsen HP, Reichart PA. Adenomatoid odontogenic tumour: Facts and figures. *Eur J Cancer B Oral Oncol* 1998;35:125-31.
- Wright JM, Vered M. Update from the 4th edition of the World Health Organization Classification of head and neck tumours: Odontogenic and maxillofacial bone tumors. *Head Neck Pathol* 2017;11:68-77.
- Jing W, Xuan M, Lin Y, Wu L, Liu L, Zheng X, *et al.* Odontogenic tumours: A retrospective study of 1642 cases in a Chinese population. *Int J Oral Maxillofac Surg* 2007;36:20-5.
- Chrcanovic BR, Gomez RS. Adenomatoid odontogenic tumor: An updated analysis of the cases reported in the literature. *J Oral Pathol Med* 2019;48:10-6.
- Vidal HM, Silva NR, Correa DB, Mori FA. Maxillary adenomatoid odontogenic tumor: Case report in a hospital in Santiago de Chile. *Res Rep Oral Maxillofac Surg* 2021;5:61.
- Narayanan VS, Naidu G, Ragavendra R, Mhaske-Jedhe S, Haldar M. Adenomatoid odontogenic tumor of the mandible with unusual radiographic features: A case report. *Imaging Sci Dent* 2013;43:111-5.
- Kalia V, Kalra G, Kaushal N, Sharma V, Vermani M. Maxillary adenomatoid odontogenic tumor associated with a premolar. *Ann Maxillofac Surg* 2015;5:119-22.
- Shreedhar B, Ali I, Agarwal A, Alam S. A huge adenomatoid odontogenic tumor of maxilla. *Case Rep Med* 2012;2012:317341.
- Shafer WG, Hine MK, Levy BM. *A Textbook of Oral Pathology*. 4th ed. Philadelphia, PA: WB Saunders Co.; 1993.
- Uppal A, Singh G, Mishra M, Gaur A. Adenomatoid odontogenic tumor of anterior maxilla: A case report. *Traumaxilla* 2019;1:96-9.
- Fujita A, Ueyama Y, Nagatsuka H, Kawamata H. A case of large adenomatoid odontogenic tumor in the posterior region of the mandible showing root resorption. *J Oral Med Oral Surg* 2021;27:19.

Funding: Nil; Conflicts of interest: Nil.

How to cite this article: Gopalakrishnan V, Charles NSC, Choube A. Adenomatoid odontogenic tumor in anterior maxilla: A case report. *Indian J Case Reports*. 2023;9(10):312-314.