

## Infantile tremor syndrome: Case report

Murali Keshava Sarpangala<sup>1</sup>, Rishabh Jain<sup>2</sup>

From <sup>1</sup>Assistant Professor, <sup>2</sup>Post Graduate Resident, Department of Paediatrics, Kasturba Medical College, Mangaluru, Manipal Academy of Higher Education, Manipal, Karnataka, India

### ABSTRACT

Infantile tremor syndrome (ITS) is a very rare disease with an incidence of <0.2% in India. Affecting children are around 1 year of age and characterized by developmental delay, skin pigmentation, and coarse tremors. Studies since 1990 conclude that ITS is caused by nutritional deficiencies, most prominently of Vitamin B12. Since lactating mothers from a poor socioeconomic background in regions where vegetarianism is prevalent because of cultural reasons are most likely to be deficient in Vitamin B12, the syndrome is most likely to affect this segment. The case described herein is unique because it is from Mangalore in India which is a coastal town with very low levels of vegetarianism. A 14-month-old girl presented with fever, vomiting, and loose stools coupled with abnormal movements of eyes, tongue, and hands which were coarse, rhythmic, continuous of low amplitude, present throughout the day, and absent during sleep. Although initial suspicions were of seizures and the patient was administered anti-epileptics, there was no improvement in the condition of the patient. On suspicions of symptoms being of ITS, an MRI-brain was done which showed diffuse mild loss of white matter. Consequently, blood investigations showed macro-to-microcytic hypochromic anemia. Thereafter, the child was started on injectable B12 supplementation and propranolol at 0.5 mg/kg/day for tremors. The child responded well clinically.

**Key words:** Coarse tremors, Dimorphic anemia, Vegetarianism, Vitamin B12

Infantile tremor syndrome (ITS) is an uncommon disease that has symptoms associated with coarse tremors, anemia, and progressive regression of developmental milestones (motor and/or mental) in children of around 1 year of age. Although the precise incidence is unknown, ITS accounts for 0.2% of all admissions in the country [1]. This disease's incidence has decreased due to improvements in nutrition and socioeconomic status [1]. Various nutrient deficiencies have been linked to ITS. Acute regression of mental and motor milestones, pallor with megaloblastic anemia, tremors, and an insidious beginning are all characteristics of ITS. Lethargy, brown sparse hair, bleating goat-like cries, various body site hyperpigmentation, and infections are some of the symptoms seen in this condition [2]. The rationale behind this study is that any abnormal movement of hands, eyes, and tongue need not always be seizures, and thus other diagnoses should always be kept in mind and peripheral smear and Vitamin B12 levels should be considered in such cases.

### CASE REPORT


A 14-month-old girl child, fourth in birth order with no significant natal and post-natal history born to a non-consanguineously

married couple from a lower socioeconomic status. The child had degeneration of milestones. She was last immunized at 3 months of age. She arrived at the pediatrics casualty with complaints of low-grade fever, vomiting, loose stools, and abnormal movement of eyes, tongue, and hands 2 days before admission. The movements were coarse, rhythmic, and continuous, had low amplitude, and were present throughout the day except during sleep. There was no significant family history.

Her weight, height, and head circumference were <50<sup>th</sup> centile, <1<sup>st</sup> centile, and <3<sup>rd</sup> centile, respectively. On physical examination, she was found to be plump looking, dull, expressionless with a vacant stare, microcephaly, and scanty brown-colored hairs. Pallor was present with hyperpigmented extremities over the dorsum of fingers (Fig. 1). Central nervous system examination showed exaggerated deep tendon reflexes and plantar-extensor, suggestive of an upper motor neuron lesion. Cardiovascular, respiratory, and per abdomen examinations were normal.

Initial blood investigations revealed anemia (Hb- 7.7), a total white blood cell count of 6770, and thrombocytosis (platelets- 5.18 lacs). Serum electrolytes and blood glucose levels were normal.

Since CNS findings were present, the initial suspicion was of seizure disorder. The treatment with anti-epileptics was

Access this article online	
Received - 05 May 2023 Initial Review - 16 May 2023 Accepted - 06 June 2023	Quick Response code 
DOI: 10.32677/ijcr.v9i6.4027	

**Correspondence to:** Rishabh Jain, Department of Paediatrics, Kasturba Medical College, Mangaluru, Manipal Academy of Higher Education, Manipal, Karnataka, India. E-mail: dr.rishabhjain0810@gmail.com

© 2023 Creative Commons Attribution-NonCommercial 4.0 International License (CC BY-NC-ND 4.0).

administered henceforth, however, the child did not respond positively to the same. Meanwhile, to identify the cause of anemia, the peripheral smear was studied, and it showed macro-to-microcytic hypochromic anemia with polychromatophils (MCV- 109, MCHC- 26.6, MCH- 28.9, and RDW- 21.5). Serum iron was low. Even though serum B12 level was normal, it could be because of prior treatment with multivitamins, as macro-to-microcytic hypochromic anemia is strongly correlated to Vitamin B12 deficiency.

Thus, based on clinical hints, a probable diagnosis of ITS was made. Hence, an MRI-brain with contrast was carried out that showed diffuse mild loss of white matter in bilateral cerebral hemispheres with atrophic changes of brain parenchyma, brain stem (Fig. 2a), and thinning of the corpus callosum (Fig. 2b). The report seconded the clinical suspicions of ITS.

As part of the treatment, anemia and malnutrition were addressed. As there were indications of low B12 levels, the child was started on injectable B12. For tremors, propranolol at 0.5 mg/kg/day was added. Studies had shown that the syndrome can also be caused because of low levels of other vitamins and minerals. To safeguard against such a scenario, the patient was also administered supplements for ascorbic acid and iron. The initial results were visible in 72 h. The patient became more responsive and active. Within 1 week, the appetite got improved. The first signs of reduction in tremor amplitude and severity took almost a month. The patient was discharged after a visible reduction in tremors; however, the parents were advised to

follow the multivitamin and propranolol regime strictly. Weekly follow-up checks were carried out for another month. Tremors had reduced significantly after 2 months; however, skin and hair pigmentation had only begun to resolve.

## DISCUSSION

The classic picture of ITS is a malnourished 6–18-month plump infant who is lethargic, apathetic, and indifferent to its surroundings. The hair is light-colored and sparse, with dark pigmentation on the nail folds, hands, knees, ankles, feet, and buttocks. It is associated with recent milestone regression. Tremor arises suddenly because of an illness or stress. It is intermittent at first, then, it becomes continuous. They are more prominent on the limbs, head, face, and distal parts of the tongue and these disappear during sleep. Most of the typical features were present in our case.

The neurological symptoms may manifest if the cerebrospinal fluid has lower B12 coupled with lower levels of its transport protein transcobalamin II [3]. Tremors result from structural and functional changes in the extrapyramidal system [4]. Anemia can be microcytic, normocytic, or macrocytic. The cause is still unknown. The diet theory is widely accepted. Many studies have found that B12 deficiency is linked to ITS [5]. Other dietary deficiencies such as that of proteins, vitamins A, B complex, and C, and micronutrients are also common. Iron, magnesium, and zinc deficiencies are also thought to contribute to ITS [3,6,7]. It usually affects children who have been exclusively breastfed by vegetarian mothers for an extended period of time.

ITS is primarily diagnosed clinically based on a peripheral smear that demonstrates anemia (most typically megaloblastic anemia, hypersegmented polymorphic cells, and macrocytosis [7]. Maternal B12 levels may be inadequate as well, indicating a lack of amounts in breast milk. The most prevalent abnormalities in brain CT/MRI are cortical atrophy which was detected in our case [8].

As part of the treatment, anemia and malnutrition are addressed. If B12 levels are low, treatment may be required. The patient might require supplements for ascorbic acid, proteins, iron, and magnesium [9]. Phenobarbitone (3–5 mg/kg/day) may be administered to reduce the intensity of tremors [10]. The tremors gradually reduce in amplitude and severity at first, then become sporadic, and ultimately stop. Propranolol and chlorpromazine can also be used to treat tremors. Skin and hair pigmentation changes take months to fade [6].

Finally, ITS should be considered in young children who exhibit indications of starvation, growth retardation, tremors, and characteristic crying. Even if a few findings point in a different direction than a large set of other findings, one must remember that the exceptions can be mere aberrations. For example here, although Vitamin B-12 levels were normal, most of the other findings pointed toward ITS.

## CONCLUSION

Abnormal movement of hands, eyes, and tongue need not always

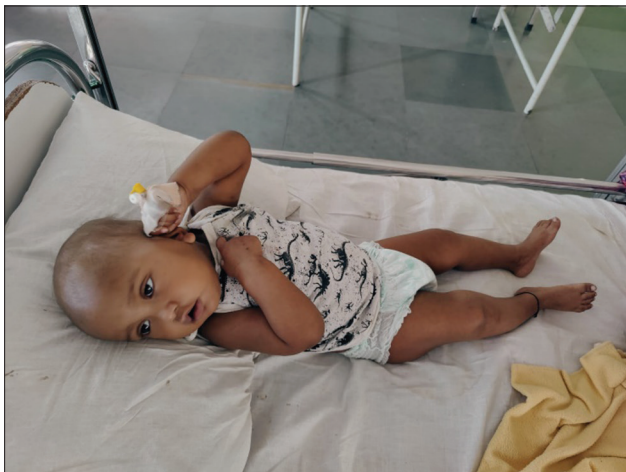

Figure 1: A child with infantile tremor syndrome

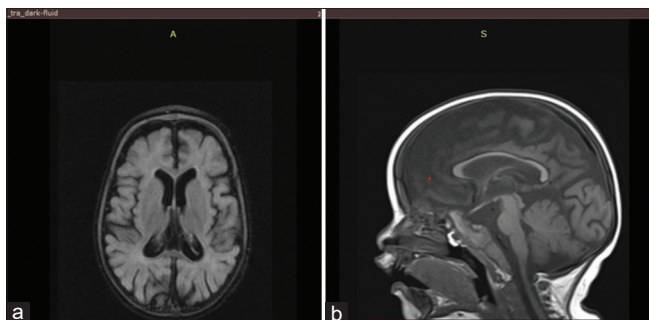


Figure 2: MRI-Brain with contrast showed (a) Cerebral atrophy and (b) Corpus callosum thinning

be seizures, and thus other diagnoses should always be kept in mind. Peripheral smear and Vitamin B12 levels should be considered in such cases. CNS findings do not necessarily mean seizures, and hence, one should not load on anti-epileptics. Blood findings should be carefully studied in all circumstances. More broadly, a standard operating protocol is followed which allows for the detection of rare diseases through a study of multiple data points from disparate sources.

## REFERENCES

1. Gupta R, Rawat AK, Singh P, Gupta J, Pathak A. Infantile tremor syndrome: Current perspectives. *Res Rep Trop Med* 2019;10:103-8.
2. Inamdar SZ, Kumari V, Nandikol S, Londe S, Kulkarni R, Patil M. Infantile tremor syndrome: A case report. *Indian J Pharm Pract* 2022;15:57-60.
3. Gupte S, Pal M, Gupta SK, Sangra KR. Infantile tremor syndrome (ITS). *Indian J Pediatr* 2007;74:88.
4. Gupte S, editor. *Textbook of Pediatric Nutrition*. New Delhi: Peepee Publishers and Distributors; 2006.
5. Avci Z, Turul T, Aysun S, Unal I. Involuntary movements and magnetic resonance imaging findings in infantile cobalamin (Vitamin B12) deficiency. *Pediatrics* 2003;112:684-6.
6. Goraya JS, Kaur S. Infantile tremor syndrome: A review and critical appraisal of its etiology. *J Pediatr Neurosci* 2016;11:298-304.
7. Jain R, Singh A, Mittal M, Talukdar B. Vitamin B12 deficiency in children: A treatable cause of neurodevelopmental delay. *J Child Neurol* 2015;30:641-3.
8. Goraya JS, Kaur S. Infantile tremor syndrome--down but not out. *Indian Pediatr* 2015;52:249-50.
9. Gupte S. *The Short Textbook of Pediatrics*. London: JP Medical Ltd.; 2016.
10. Gourie-Devi M. Neurological practice: An Indian perspective. *Ann Indian Acad Neurol* 2006;9:129.

*Funding: Nil; Conflicts of interest: Nil.*

**How to cite this article:** Sarpangala MK, Jain R. Infantile tremor syndrome: Case report. *Indian J Case Reports*. 2023;9(6):165-167.