

A rare diagnosis has no certainty, but still they occur: A case report

Megha Marthandan¹, Nithya Geetha², Susy Joseph³, Ajithkrishnan A S⁴, N Kiran⁵

From ¹Postgraduate, ²Junior Resident, ³Associate Professor, ⁴Professor and HOD, ⁵Assistant Professor, Department of Paediatrics, SAT Hospital, Government Medical College Trivandrum, Kerala, India

ABSTRACT

Pain and swelling are among the most frequently encountered complaints in an orthopedics outpatient department (OPD) relatively less common in a pediatric OPD. A high level of suspicion is required to diagnose bone diseases. Common conditions such as rickets, septic arthritis, and tuberculosis must be ruled out. Treatment such as antibiotics, anti-inflammatory drugs, or steroids may mask an underlying serious condition in which if left untreated can cause significant morbidity and mortality to the person. Here, we discuss a case of a young infant 11 months of age who had symptoms suggestive of septic arthritis and was later found to have Brodie's abscess which is a type of subacute osteomyelitis on further evaluation which is usually mistaken as a tumor. This age at presentation is rare.

Key words: Brodie's abscess, Vitamin D, Subacute osteomyelitis, Septic arthritis

Septic osteomyelitis is a hematogenous bacterial bone infection. The acute presentation is the most common; the subacute one is less frequent. Subacute osteomyelitis may have deceptive features which can delay the diagnosis. Benjamin Brodie was the one who first described a localized collection of pus in the tibia in an amputated limb that did not produce systemic signs and developed without prior febrile illness [1]. As stated by Foster *et al.* (2019), around 5 in 100,000 children/year are recorded with incidents of subacute osteomyelitis in high-income countries. The presence can be higher in low- and medium-income countries as well; however, the lack of proper surveys and recording of incidents limits the ability for an accurate global assessment [2]. Due to its location in the bone, it can mimic benign and malignant diseases. The disease has an indolent course due to the interplay of host resistance combined with the low virulence of the infecting organism. Brodie's abscess which is a type of subacute osteomyelitis has a protean radiological appearance and can occur at any age and any location [3]. Moreover, the association between Brodie's abscess and subacute osteomyelitis is seldom mentioned in the literature.

The aim of the case report is to highlight the serial radiological findings and management as the condition is uncommon and is usually mistaken for being a bone tumor.

CASE REPORT


An 11-month-old male child with no significant past history or trauma presented with swelling over the right knee for 6 weeks for which he has been treated with oral antibiotics in a local hospital and symptoms improved during treatment. Later, the child was taken to the pediatric outpatient department as he was unable to bear weight when he was made to stand and the mother also noticed a paucity of movement of the right lower limb for the past 6 weeks.

On examination, the child was well nourished and had pain over the right knee when made to stand. Furthermore, tenderness was present over the right knee. His pulse rate was 116/min and respiratory rate was 38/min and was afebrile. There was a limb length discrepancy of 2 cm between both lower limbs and mild edema present over the right knee. There was no local rise in temperature but tenderness was present. Examination of the hip and other system examination was normal. There was no other swelling. His neurological examination was normal. He could not bear weight on his right leg.

His blood reports revealed elevated total leukocyte counts of 12,500 cells/cumm, erythrocyte sedimentation rate of 49 mm/h, and C-reactive protein was non-reactive. X-ray knee (Fig. 1) taken on May 14, 2020 was normal. His serum calcium, phosphorus, and vitamin D level were within normal limits. Orthopedic consultation was done and was prescribed calcium and multivitamin syrup and advised to review after 1 week. On

Correspondence to: Megha Marthandan, 'Meghadoot', Kunnumpuram, Vivekananda Road, VRRR No. 36, North Edappally, Ernakulam - 682 041, Kerala, India. E-mail: megham2222@gmail.com

© 2023 Creative Commons Attribution-NonCommercial 4.0 International License (CC BY-NC-ND 4.0).

Access this article online	
Received - 23 March 2023 Initial Review - 04 April 2023 Accepted - 13 April 2023	Quick Response code 
DOI: 10.32677/ijcr.v9i4.3954	

further follow-up, the child got improved on supportive treatment with calcium and multivitamin supplementation and was able to bear weight on his right leg.

A repeat X-ray (Figs. 2 and 3) was taken revealing a lytic lesion in the metaphyseal region of the right distal femur following which, the child was further evaluated. Total count and inflammatory markers repeated were within normal limits. His magnetic resonance imaging (MRI) (Fig. 4) showed an intramedullary abscess. A probable diagnosis of Brodie's abscess was considered.

The child was started on treatment with IV cloxacillin (200 mg/kg/day) followed by oral cloxacillin (150 mg/kg/day) for a total duration of 6 weeks. A repeat X-ray (Fig. 5) on follow-up was taken which showed no residual lesion. No surgical intervention was required for treatment. The child's growth, development, and locomotion are normal now for the past 18 months.

DISCUSSION

Subacute osteomyelitis is a distinct form of osteomyelitis and Brodie's abscess is one type of subacute osteomyelitis. Subacute osteomyelitis is difficult to diagnose as the characteristic signs and symptoms of the acute form of the disease are absent. Brodie's abscess is an intraosseous abscess related to a focus of subacute or chronic pyogenic osteomyelitis. Unfortunately, there is no reliable way to radiographically exclude a focus of osteomyelitis. It has a protean radiographic appearance and can occur at any location and in a patient of any age. It might or might not be expansile, have

a sclerotic or non-sclerotic border, or have associated periostitis. It is an uncommon condition, usually mistaken for a bone tumor, and has been frequently observed to involve the metaphysis of bones (especially the tibia) [4]. Making an accurate and timely diagnosis is usually a challenge as pain or swelling are generally the most stereotypical and vague complaints at presentation [5].

Subacute osteomyelitis is characterized by mild-to-moderate pain, usually described as a persistent ache with intermittent symptoms and of insidious onset and there is often a long delay between the onset of pain (the most common presenting symptom) and the diagnosis. Usually, symptoms are present for 2 weeks or longer. The course is generally marked by few or no constitutional symptoms and no known previous acute disease. A systemic reaction is absent, and supportive laboratory data are inconsistent. Most case reports and series in the literature describe *Staphylococcus aureus* as the primary pathogen causing Brodie's abscess. According to various studies, an increase in the use of antibiotics decreased the incidence of the acute form but increases the incidence of the subacute form of osteomyelitis [6-8].

Brodie's abscess is more common in children than in adults. They appear commonly in the metaphysis, particularly that of the distal or proximal portions of the tibia. Less frequently, they occur in other tubular, flat, or irregular bones, including the vertebral bodies, and are diaphyseal in location. Rarely, do they traverse the growth plate, affecting the epiphysis, although such extension does not commonly result in growth disturbance [9].

The various differential diagnoses of Brodie's abscess are eosinophilic granuloma, osteogenic sarcoma, osteoid osteoma, osteoblastoma, enchondroma, non-ossifying fibroma, chondrosarcoma, intraosseous lipoma, ewing sarcoma, and Langerhans cell histiocytosis [10,11].

The various radiologic techniques involved in the diagnosis of subacute osteomyelitis are important and radiologic osseous changes are often present, even in patients with a short history of symptoms. Typically, a localized destructive lesion of bone is present, with surrounding sclerosis in the metaphysis. It is best detected by the combination of standard X-rays and MRI [12]. MRI is the gold standard in diagnosis. MRI finding that supports the diagnosis of subacute osteomyelitis and helps to exclude the presence of a tumor is the penumbra sign [10]. The penumbra sign is characteristically seen on T1-weighted MRI (2- to 5-mm thickness). It is due to a thick layer of highly vascularized granulation tissue. The presence of a layer of granulation tissue

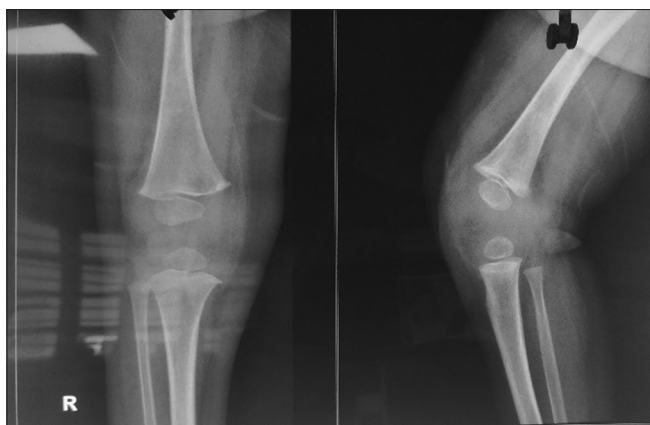

Figure 1: Radiograph of the right leg taken on May 14, 2021

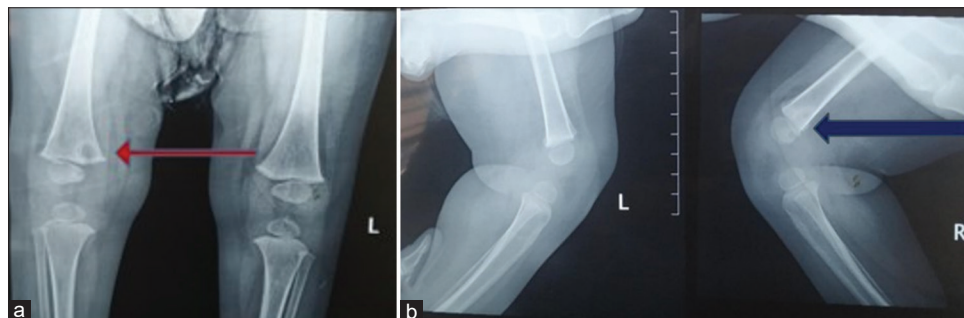


Figure 2: (a) Repeat radiograph of the right leg taken after 3 weeks (June 7, 2021) showing a lytic lesion in the metaphysis of the right femur; (b) lateral radiograph of the right knee showing sclerosis of bone around lytic lesion taken on (June 7, 2021)

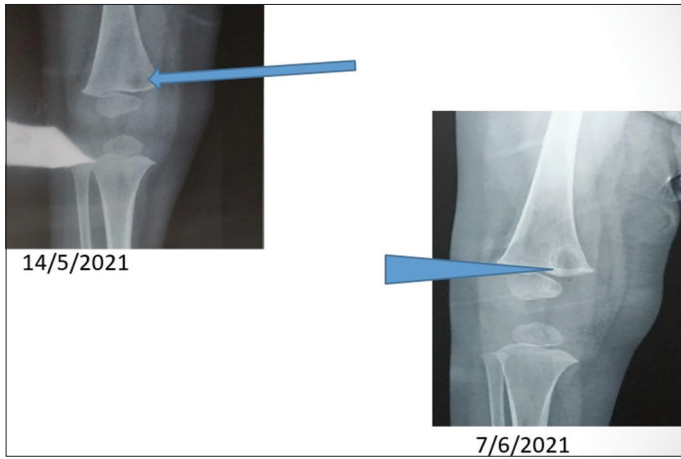


Figure 3: A comparison between two radiographs of the right leg taken 3 weeks apart

lining a cavity is important in the differentiation of an abscess from a tumor. The fluid in the abscess may be purulent or mucoid. Abscess mass consists of cellular debris and neutrophils, a surrounding fibrotic reaction, and peripheral eburnated bone. Other imaging modalities include plain radiograph which shows lytic lesions in an oval configuration that is oriented along the long axis of the bone, surrounded by a thick dense rim of reactive sclerosis that fades imperceptibly into the surrounding bone, the lucent tortuous channel extending toward the growth plate before physeal closure (pathognomonic), along with periosteal new bone formation and adjacent soft-tissue swelling. These findings may persist for many months. The computed tomography (CT) findings include a central intramedullary hypodense cystic lesion with thick rim ossification and extensive thick well-circumscribed periosteal reaction and bone sclerosis around the

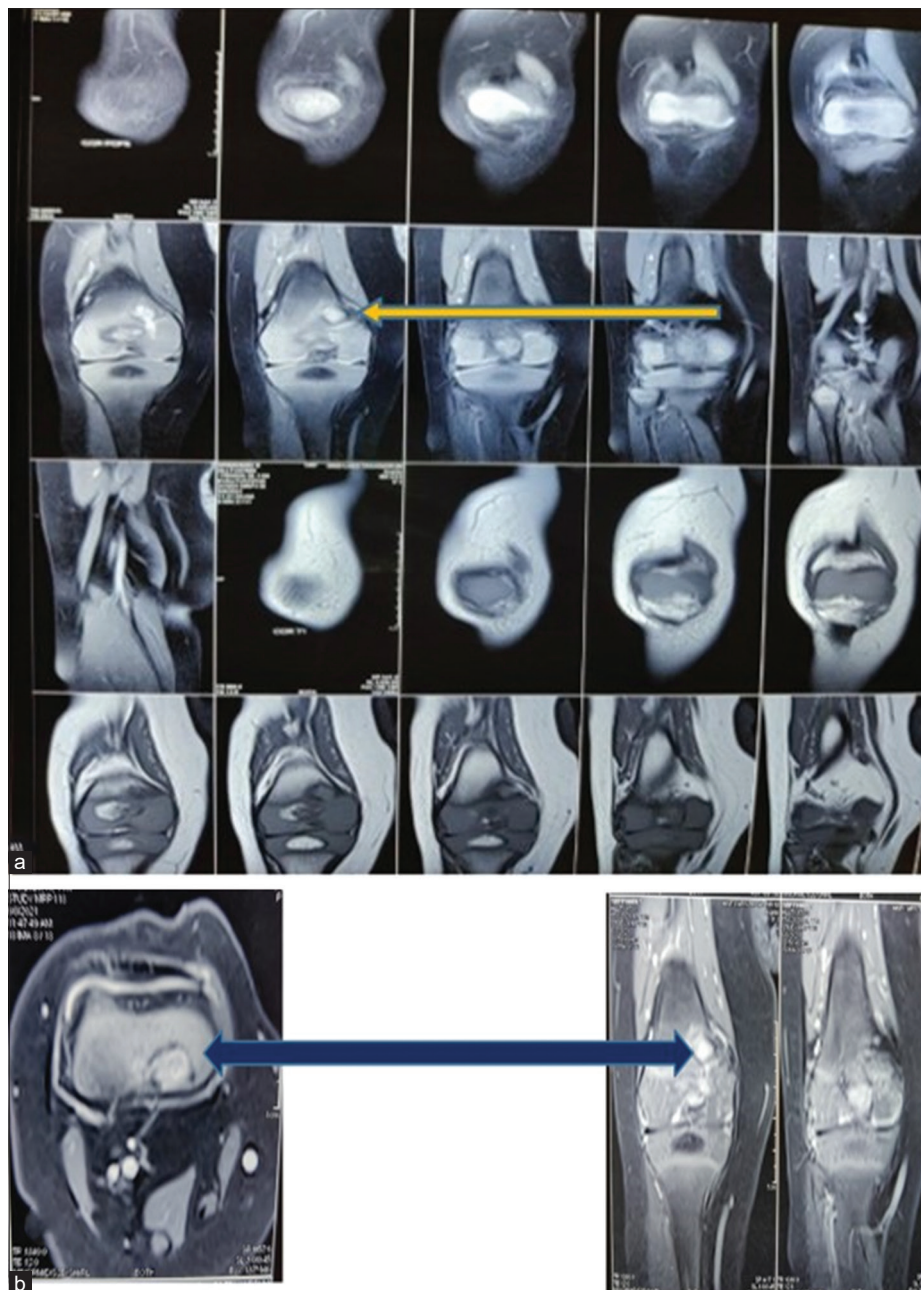


Figure 4: Magnetic resonance imaging showing an intramedullary abscess of distal femur

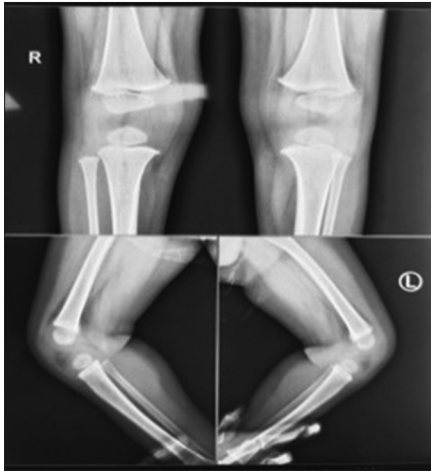

Figure 5: Repeat radiograph of the right leg showing complete resolution of the lytic lesion taken after 6 months on December 13, 2021

lesion. CT is useful in defining the extent of the lesion but is less useful for defining an inflammatory process. CT is excellent at detecting cortical destruction and periosteal reaction, although is not a first-line imaging modality. MRI is an excellent modality to visualize and define inflammatory processes, particularly early in the course of illness. MRI has a high sensitivity in detecting the pathology of bone and soft tissue and can define the extent of a pathologic process. Availability and the possible need for sedation may limit immediate use.

The treatment consists of two important modalities: one medical and the other orthopedic. The medical treatment consists of empiric antibiotic therapy adjusted to the antibiogram. The blood culture is positive only 30–50% of the time and will likely be negative soon after antibiotics are administered, even if treatment is not progressing satisfactorily. In a case series by Mohit *et al.*, they reported all blood cultures to be negative [13]. Treatment is begun with empiric antibiotic therapy generally, nafcillin or cloxacillin, unless high local prevalence of Methicillin-resistant *S. aureus* (then use clindamycin or vancomycin) if Gram-stain shows Gram-negative bacilli, a third-generation cephalosporin is also added and later converted to organism-specific antibiotics if organism identified. Antibiotic therapy alone is indicated in case of the early disease with no subperiosteal abscess or abscess within the bone or when surgery is not indicated as clinical improvement was obtained within 48 h. Concerning the diaphysis location, antibiotics duration varies from 3 to 12 months. In this case, the child improved without much complication on a course of antibiotics for a period of 6 weeks duration. Surgical drainage is necessary as antibiotics will not penetrate the abscess cavity. Primary curettage and closure of the wound are necessary. Surgical intervention is needed in case of a deep or subperiosteal abscess, failure to respond to antibiotics, and chronic infection. It is not always necessary to perform wide excision or saucerization of the lesion. Surgery is always indicated if

large cortical sequestra or discharging sinuses are present. Regular follow-up is important as it can affect growth. The consequences of missing this diagnosis include permanent disability and potential amputation, but excellent outcomes can be expected for those who undergo timely treatment [14].

CONCLUSION

Brodie's abscess has an infrequent presentation. For a pediatric population, it very essential to rule out malignancy. The importance of ruling out the differential diagnosis of subacute osteomyelitis far outweighs the diagnosis of the same. Early identification and management are very important to prevent long-term disability.

REFERENCES

1. Brodie BC. An account of some cases of chronic abscess of the tibia. *Med Chir Trans* 1832;17:239-49.
2. Foster CE, Taylor M, Schallert EK, Rosenfeld S, King KY. Brodie abscess in children: A 10-year single institution retrospective review. *Pediatr Infect Dis J* 2019;38:e32-e34.
3. Gaillard F, Bickle I, Ibrahim D. Brodie Abscess. Available from: <https://www.radiopaedia.org> [Last accessed on 2023 Mar 21].
4. Lindsetmo RO, Due J, Singh K, Stalsberg H. Brodie's abscess. *Tidsskr Nor Laegeforen* 1993;113:2257-8.
5. Brodie Abscess; 2021. Available from: <https://radiopaedia.org/articles/brodie-abscess-1?lang=gb> [Last accessed on 2021 Apr 25].
6. Van der Naald N, Smeeing DP, Houwert RM, Hietbrink F, Govaert GA, van der Velde D. Brodie's abscess: A systematic review of reported cases. *J Bone Jt Infect* 2019;4:33-9.
7. Olasinde AA, Oluwadiya KS, Adegbehingbe OO. Treatment of Brodie's abscess: Excellent results from curettage, bone grafting and antibiotics. *Singapore Med J* 2011;52:436-9.
8. Letts RM. Subacute osteomyelitis and the growth plate. In: Uthoff HK, Wiley JJ, editors. *Behavior of the Growth Plate*. New York: Raven Press; 1988. p. 331-8.
9. Jones NS, Anderson DJ, Stiles PJ. Osteomyelitis in a general hospital. A five-year study showing an increase in subacute osteomyelitis. *J Bone Joint Surg Br* 1987;69:779-83.
10. Salik M, Mir MH, Philip D, Verma S. Brodie's abscess: A diagnostic conundrum. *Cureus* 2021;13:e16426.
11. Bohndorf K. Infection of the appendicular skeleton. *Eur Radiol* 2004;14 Suppl 3:E53-63.
12. Zairi M, Boussetta R, Msakni A, Mohseni AA, Nessib MN. Subacute osteomyelitis of the tibial diaphysis associated with Brodie's abscess: A rare case report of a four-year-old child. *Int J Surg Case Rep* 2021;89:106453.
13. Jain MJ, Shenava VR. Brodie abscess: Case series of 15 pediatric patients treated surgically. *Pediatrics* 2019;144:810.
14. Lowe J, Bridwell RE, Matlock AG, Cibrario A, Oliver J. A case of Brodie's abscess with tibial erosion and extravasation into surrounding soft tissue. *Cureus* 2020;12:e8592.

Funding: Nil; Conflicts of interest: Nil.

How to cite this article: Marthandan M, Geetha N, Joseph S, Ajithkrishnan AS, Kiran N. A rare diagnosis has no certainty, but still they occur: A case report. *Indian J Case Reports*. 2023;9(4):102-105.