

Arsenic toxicity following Ayurvedic medication

Devyani Shinde¹, Suhrith Bhattaram², Varsha Shinde³, Sandeep Bhavsar⁴

From ¹Intern, ⁴Senior Consultant, Department of Medicine, Aditya Birla Hospital, Thergaon, ²Senior Resident, ³Professor, Department of Emergency Medicine, Dr. D. Y. Patil Medical College, D.Y. Patil Vidyapeeth, Pune, Maharashtra, India

ABSTRACT

Alternative forms of medicine like Ayurveda have witnessed a rise in global popularity over the recent decades. Drugs used in Ayurveda, particularly those of mineral origin can lead to toxic effects due to heavy metal overdose. Here, we report the case of a 53-year-old woman who presented with glove-and-stocking paresthesia and scaly plaques following the institution of Ayurvedic drugs containing arsenic for dermatitis. She also had a loss of distal proprioception and a hyperesthetic response to pinprick. Her blood analysis showed elevated arsenic levels; 12 times the acceptable upper limit, with normal lead, cadmium, mercury, and chromium levels. The drug was immediately stopped and there was a gradual but incomplete resolution of the paresthesia and distal weakness over the next several months. The risk of heavy metal toxicity should be briefed to the patient before the start of mineral Ayurvedic drugs. Monitoring serum levels while on these medications might help identify toxicities early and can result in the commencement of therapy at an early stage.

Key words: Arsenic toxicity, Arsenicosis, Ayurvedic medication, Heavy metal toxicity, Peripheral neuropathy

Ayurveda is an ancient system of medicine that has its roots in India. With the rise in global popularity over the last few decades, Ayurveda is being accepted as a complementary and alternative form of medicine. However, with increasing usage, there has also been an unfortunate increase in side effects.

Ayurveda's pharmacological section consists of medicines of herbal, mineral, and animal origin [1]. Drugs derived from herbal sources are generally considered safe, whereas, those of a mineral origin can lead to toxic effects and several cases of heavy metal toxicity, especially lead, have been reported [2]. Mercury and arsenic have also been implicated in a few cases.

We report a case of chronic arsenic toxicity following a course of Ayurvedic medication for eczematous dermatitis. Suspecting arsenic toxicity is of key importance as several chronic complications are not amenable to treatment. Identification of risk factors and early discerning of symptoms by physicians play a key role in the effective management of this toxicity.

CASE REPORT

A 53-year-old woman presented to the emergency department with chief complaints of gradual onset of diminished sensation and limb paresthesias over the past 2 months. She had been diagnosed


with chronic eczematous dermatitis about 1 year ago for which she had initially been prescribed topical steroids but an inadequate response and the risk of side effects convinced her to switch to a more traditional form of medicine. She started treatment with the Ayurvedic medication "Talkeshwar Ras" which consisted of "Manashila" (Arsenic Disulphide) and "Harital" (Arsenic Trioxide).

On arrival, she was vitally stable with a heart rate of 74/min, blood pressure of 136/90 mmHg, and SpO₂ of 98%. Following the development of sensory symptoms, she also noticed a loss of dexterity about 1 month ago, which initially manifested as difficulty in buttoning-unbuttoning a shirt. Over the next 2 weeks, this progressed to an inability to pick up small objects. She also began experiencing slippage of sandals while walking. In addition, she also suffered from multiple episodes of loose stools per day and abdominal pain along with significant weight loss. Neurologic examination revealed a diminished sensation in a symmetric "glove-and-stocking" fashion. There was also loss of proprioception in the hands and feet, with a hyperesthetic response to pinprick sensation.

Romberg's test was positive. Gait, coordination, and cranial nerve functions were intact. Muscle bulk and tone were normal and deep tendon reflexes were absent at the knees and ankles. She had no dysphagia, visual symptoms, or bladder and bowel incontinence. The examination of the skin revealed dark patches of hyperpigmentation, with hyperkeratotic scaly plaques on the extensor aspects of the forearms and legs (Fig. 1).

Correspondence to: Suhrith Bhattaram, Department of Emergency Medicine, Dr. D. Y. Patil Medical College, Pune - 411 018, Maharashtra, India. E-mail: bsk1694@gmail.com

© 2022 Creative Commons Attribution-NonCommercial 4.0 International License (CC BY-NC-ND 4.0).

Access this article online	
Received - 22 October 2022 Initial Review - 05 November 2022 Accepted - 24 November 2022	Quick Response code 
DOI: 10.32677/ijcr.v8i11.3677	

Nerve conduction studies of the median, ulnar, common peroneal, tibial, and sural nerves revealed axonal sensorimotor polyneuropathy. A heavy metals profile revealed elevated blood arsenic levels with normal lead and mercury levels (Table 1). She was a vegetarian and had no history of consuming meat or seafood.

The patient was diagnosed to have chronic arsenic toxicity and was advised to immediately stop the offending drug. Hyperkeratosis and scaling of the limbs showed complete regression 3 months after the stoppage of arsenic (Fig. 2). However, neuropathy showed steady but incomplete improvement. She has currently regained complete strength in her upper limbs but there is still residual weakness and tingling in the lower limbs. Blood arsenic returned to acceptable levels 6 months after cessation of

the drug. She has been now followed up for more than a year and is doing well.

DISCUSSION

Arsenic is one of the four most hazardous toxicants, along with cadmium, lead, and mercury [3]. It is ubiquitous in the environment and has been used for ages past as a potent poison and for various medicinal purposes. Until the mid-1900s, arsenicals (Anti-psoriatic Fowler's solution and Salvarsan) were widely used in the treatment of various diseases such as syphilis and psoriasis [2]. Currently, its major role in medicine is its use in the treatment of acute promyelocytic leukemia [1].

In Ayurveda, certain drugs called "bhasmas" are derived from minerals and undergo an extensive purification process to render them non-toxic before they are used [1]. Although many of these drugs are used safely, a lack of stringent quality control has resulted in an increasing number of these drugs being implicated in a variety of heavy metal poisoning, notably lead, mercury, and occasionally arsenic [1,4]. Saper and colleagues measured lead, mercury, and arsenic in Ayurvedic medications and found one-fifth of these had levels above permissible limits [5]. In our case, the patient was prescribed "Talkeshwar Ras" which consisted of "Manashila" (Arsenic Disulphide) and "Haritala" (Arsenic Trioxide). Arsenic is also labeled as a toxin in Ayurveda and at present arsenicosis can be confirmed by high serum or tissue total arsenic by atomic absorption spectrometry and high urinary total arsenic [6].

Once the diagnosis of arsenic toxicity is confirmed, the source must be quickly identified and removed. The aim of treatment is the relief of symptoms, and reduction of body stores of arsenic and its associated complications. Treatment is effective if started early in the course of the toxicity. Treatment is not successful in severe manifestations of polyneuropathy, and chronic liver and lung disease. Penicillamine, Dimercaptosuccinic acid, or British Anti Lewisite have been used as chelating agents for arsenic toxicity. These drugs are expensive and not so readily available in India. Further, they are toxic, and patients receiving these drugs should be monitored for side effects [6].

Peripheral neuropathy may be the first sign of chronic arsenic toxicity. It is predominantly due to axonal destruction or axonopathy. Early electrodiagnostic features are indistinguishable from Guillain-Barre syndrome and it later evolves into a more classic sensorimotor distal axonopathy. Moderate poisoning often presents with painful dysesthesias and other sensory effects, whereas, severe poisoning presents with ascending weakness and paralysis. There is rarely any involvement of cranial nerves even in severe poisoning. Hyperpigmentation and hyperkeratosis are delayed hallmarks of chronic arsenic exposure. This is often accompanied by anemia. Lung cancer and skin cancer are serious long-term complications among cases of chronic arsenic poisoning [2]. Recovery from neuropathy induced by chronic exposure to arsenic compounds is generally slow, sometimes taking years, and complete recovery may not occur. Studies suggest that the use of Vitamin A analogs (retinoids) may be

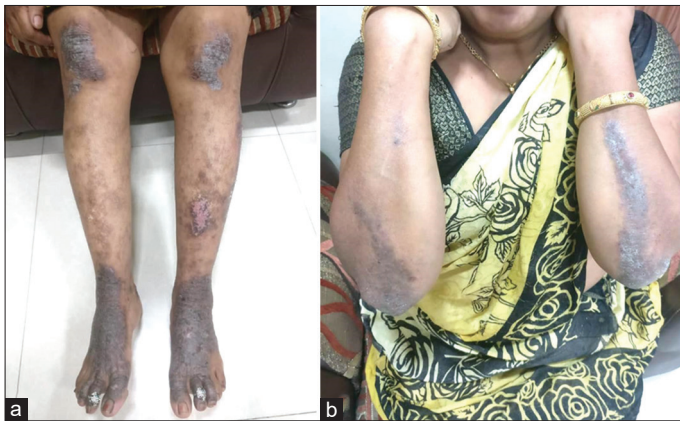

Figure 1: Dark patches of hyperpigmentation, with hyperkeratotic scaly plaques on the extensor aspects of the (a) forearms and (b) legs 2 months after starting arsenic

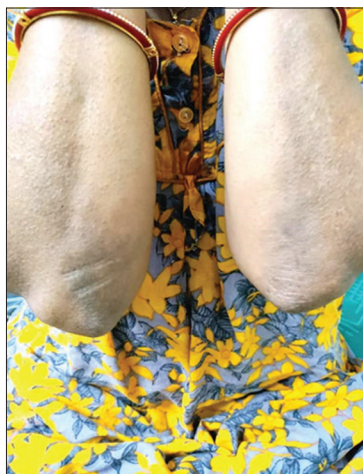

Figure 2: Resolution of hyperkeratotic plaques 3 months after stopping medication

Table 1: Serum heavy metal profile

S. No.	Metal	Blood level	Biological reference interval
1	Mercury	3.09 ug/L	0.46–7.5 ug/L
2	Arsenic	145 ug/L	0.4–11.9 ug/L
3	Lead	1.29 ug/dL	0–9 ug/dL
4	Cadmium	0.05 ug/L	0–0.5 ug/L
5	Chromium	2.32 ug/L	0.7–28 ug/L

useful in treating precancerous arsenical dermatoses. The value of chelation therapy in preventing incipient neuropathy has been suggested but not adequately demonstrated [2]. Murphy *et al.* reported two cases of neuropathy treated with DPA. In both these patients, urinary excretion of arsenic increased and they improved though residual neuropathy persisted [1]. Available evidence does not support the routine use of chelation therapy for patients with an established arsenic neuropathy, though it can be considered in life-threatening cases [2,7,8]. A recent study by Mishra *et al.* shows that native and indigenous plant-based active biomolecules appear to mitigate arsenic-induced toxicity with an acceptable safety profile. Various phytochemicals such as flavonoids and stilbenoids have antioxidant and chelation effects, which may facilitate the removal of arsenic from the body more effectively and safely as compared to conventional approaches [9].

CONCLUSION

It is prudent that all clinicians be aware of the risk of chronic heavy metal toxicity following ingestion of mineral Ayurvedic drugs. Monitoring serum levels of heavy metals can help in the early identification of toxicity and appropriate withdrawal of the drug can reduce mortality and morbidity.

Our patient improved with the cessation of the offending drug. The role of chelators in chronic toxicity is not well established and further research is needed to establish their effectiveness, dose, and duration of treatment.

REFERENCES

1. Pinto B, Goyal P, Flora SJ, Gill KD, Singh S. Chronic arsenic poisoning following ayurvedic medication. *J Med Toxicol* 2014;10:395-8.
2. Rall DP, Pope AM. *Environmental Medicine: Integrating a Missing Element into Medical Education*; 1995. p. 139-57. Available from: <https://www.nap.nationalacademies.org/read/4795/chapter/13#156> [Last accessed on 2022 Aug 25].
3. Correia N, Carvalho C, Friões F, Araújo JP, Almeida J, Azevedo A. Haemolytic anaemia secondary to arsenic poisoning: A case report. *Cases J* 2009;2:7768.
4. Lynch E, Braithwaite R. A review of the clinical and toxicological aspects of “traditional” (herbal) medicines adulterated with heavy metals. *Expert Opin Drug Saf* 2005;4:769-78.
5. Saper RB, Phillips RS, Sehgal A, Khouri N, Davis RB, Paquin J, *et al.* Lead, mercury, and arsenic in US- and Indian-manufactured Ayurvedic medicines sold via the internet. *JAMA* 2008;300:1652.
6. Pimparkar BD, Bhave A. Arsenicosis: Review of recent advances. *J Assoc Physicians India* 2010;58:617-24.
7. Murphy MJ, Lyon LW, Taylor JW. Subacute arsenic neuropathy: Clinical and electrophysiological observations. *J Neurol Neurosurg Psychiatry* 1981;44:896-900.
8. Nurchi VM, Djordjevic AB, Crisponi G, Alexander J, Bjørklund G, Aaseth J. Arsenic toxicity: Molecular targets and therapeutic agents. *Biomolecules* 2020;10:235.
9. Mishra A, Oliinyk P, Lysiuk R. Flavonoids and stilbenoids as a promising arsenal for the management of chronic arsenic toxicity. *Environ Toxicol Pharmacol* 2022;95:103970.

Funding: Nil; Conflicts of interest: Nil.

How to cite this article: Shinde D, Bhattaram S, Shinde V, Bhavsar S. Arsenic toxicity following Ayurvedic medication. *Indian J Case Reports*. 2022;8(11):351-353.