

Subacute invasive pulmonary aspergillosis misdiagnosed as tuberculosis in a Nigerian man: A case report

Bassey E Ekeng¹, Bernard B Akpu², Chidimma A Ahaneku², Ubong A Udoh³, Okokon I Ita³, David E Elem², Linda N Okorafor¹, Bernard E Monjol¹, Chibueze H Njoku², Rita O Oladele⁴

From ¹Department of Medical Microbiology and Parasitology, University of Calabar Teaching Hospital, Calabar, Nigeria, ²Department of Internal Medicine, University of Calabar Teaching Hospital, Calabar, Nigeria, ³Department of Medical Microbiology and Parasitology, Faculty of Basic Clinical Sciences, College of Medical Sciences, University of Calabar, Calabar, Nigeria, ⁴Department of Medical Microbiology and Parasitology, Faculty of Basic Medical Sciences, College of Medicine, University of Lagos, Lagos, Nigeria

ABSTRACT

Subacute invasive pulmonary aspergillosis is a form of chronic pulmonary aspergillosis (CPA) with rapid progression. The clinical features of CPA mimic tuberculosis (TB) and may lead to delayed and/or misdiagnosis. We report a 39-year-old Nigerian previously managed in a peripheral hospital as a case of TB despite negative Gene-X pert results with no resolution of symptoms. Chest X-ray and computer tomography findings were suggestive of CPA and galactomannan assay positive. Symptoms resolved 2 months into itraconazole treatment. There is a dire need to drive awareness of CPA among clinicians, especially in our primary and secondary healthcare facilities where the knowledge base and expertise in the management of fungal infections is still at a rudimentary level or perhaps not available at all.

Key words: *Aspergillus* galactomannan, Pulmonary aspergillosis, Tuberculosis

Chronic pulmonary aspergillosis (CPA) is a progressive pulmonary disease that can complicate several other respiratory disorders such as tuberculosis (TB), due to existing lung cavities [1]. CPA also directly leads to cavity formation. It affects an estimated three million people worldwide [1,2]. Even when treated, CPA has a case fatality rate of 20–33% in the short term and 50% over a span of 5 years [3]. The spectrum of CPA ranges from simple aspergilloma, chronic cavitary pulmonary aspergillosis (CCPA) to chronic fibrosing pulmonary aspergillosis (CFPA) when left untreated, and subacute invasive pulmonary aspergillosis (SAIA), formerly called chronic necrotizing pulmonary aspergillosis [2]. SAIA is a more rapidly progressive infection (<3 months) usually found in mildly immunocompromised patients and has similar clinical and radiological features to CCPA [4]. Unlike invasive aspergillosis, CPA occurs in immunocompetent patients and often presents with cough, chest pain or discomfort, weight loss, profound fatigue, severe shortness of breath, and life-threatening hemoptysis, features which are not uncommon in


TB patients and may lead to misdiagnosis, especially in areas endemic for TB [2,3].

We report a case of SAIA in a male Nigerian who was previously being managed as a case of TB despite a negative Gene-X pert result.

CASE REPORT

A 39-year-old male with productive cough, hemoptysis, low-grade fever, breathlessness, loss of appetite, and weight loss of 18 months duration presented at the emergency room of the University of Calabar Teaching Hospital, Calabar, Nigeria. There was associated generalized body weakness but no chest pain or drenching night sweats. He had completed treatment for pulmonary TB the previous year in a peripheral Center, in spite of a negative sputum Gene-X pert with no improvement of symptoms.

Physical examination revealed a chronically-ill looking man in mild respiratory distress (flaring of alae nasi), afebrile (temperature: 37°C), not pale, not cyanosed, with no peripheral lymphadenopathy, or pedal edema. His respiratory rate was 22 cycles per minute and oxygen saturation was

Access this article online	
Received - 23 September 2022 Initial Review - 10 October 2022 Accepted - 08 December 2022	Quick Response code 
DOI: 10.32677/ijcr.v8i11.3644	

Correspondence to: Bassey E Ekeng, Department of Medical Microbiology and Parasitology, University of Calabar Teaching Hospital, Nigeria. E-mail: basseyewaekeng@gmail.com

© 2022 Creative Commons Attribution-NonCommercial 4.0 International License (CC BY-NC-ND 4.0).

92%. The trachea was slightly deviated to the right with widespread coarse crepitation in both lung fields. The pulse rate was 88 beats/min and the blood pressure was 110/80 mmHg. The abdominal and neurological examinations were unremarkable.

An assessment of post-TB bronchiectasis to rule out TB reinfection was made by the admitting physician. A sputum sample was collected for acid fast bacilli (AFB), Gene-X pert, and culture. The patient was commenced on intravenous amoxicillin-clavulanic acid and oral azithromycin. The physician also requested for Chest X-ray, full blood count, and human immunodeficiency virus 1 and 11 screening.

Laboratory results were obtained as smear-negative for sputum AFB and *Mycobacterium tuberculosis* negative for sputum Gene-X pert. Sputum culture yielded normal flora of the upper respiratory tract. His full blood count showed leukocytosis, neutrophilia, eosinophilia, and a raised erythrocyte sedimentation rate (ESR) of 120 mm/h (Table 1).

Chest X-ray findings showed widespread bilateral reticulonodular changes bilaterally with cavitary lesions in the right upper lung zone in keeping with pneumonic changes seen in PTB (Fig. 1). Additional findings were prominent vascular markings in the hilar region and blunting of the right costophrenic angle suggestive of pleural effusion. The patient was subsequently referred to the Respiratory/Infectious disease team who requested a High-Resolution Computed Tomography (HRCT) scan of the chest. HRCT of the chest showed dilated airspaces and diffuse pulmonary fibrosis with cavitary lesions containing oval soft tissue structures suggestive of fungal balls in the upper lung zones (Fig. 2). Based on the clinical features and the radiological finding of fungal balls on the HRCT scan of the chest, a diagnosis of CPA was made and the microbiology team was invited to do a serum galactomannan assay which subsequently showed a very high value of 18.03. A definitive diagnosis of CPA; clinical phenotype-subacute invasive aspergillosis in an adult male was made based on his positive serum galactomannan result, clinical presentation, and radiological findings. His liver function test parameters were within the reference interval (Table 1) and he

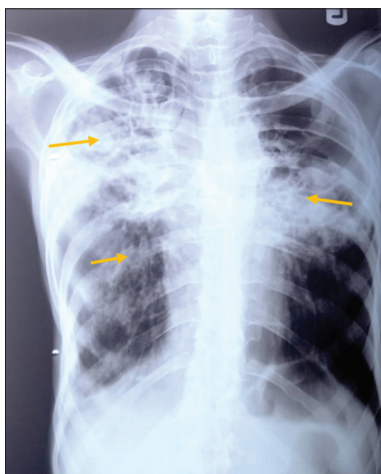


Figure 1: Chest x-ray showing widespread bilateral reticulonodular changes and cavitary lesions in the upper lung zones

was subsequently placed on the tablet itraconazole 200 mg twice daily for 6 months.

One month after the commencement of itraconazole, he reported a resolution of fever and reduced episodes of hemoptysis but a persistent cough; he was encouraged to continue therapy. Two months into itraconazole treatment, he reported a resolution of hemoptysis, subsiding cough, improved appetite, and some weight gain. His LFT values remained within the reference interval and he did not report any adverse events related to itraconazole therapy. At 5 months follow-up, the patient has maintained improvement in his clinical symptoms and quality of life.

DISCUSSION

The European Society for clinical microbiology and infectious diseases (ESCMID) and the European respiratory society rationale and clinical guidelines for diagnosis and management of CPA define SAIA as invasive aspergillosis, usually in mildly immunocompromised patients, occurring over 1–3 months, with variable radiological features including cavitation, nodules, progressive consolidation with “abscess formation.” Biopsy shows hyphae in invading lung tissue and microbiological investigations reflect those in invasive aspergillosis, notably positive Aspergillus Galactomannan antigen in the blood (or respiratory fluids) [4]. Our index patient meets this diagnostic criterion (galactomannan positive, suggestive findings from chest X-ray and computed tomography [CT]) as previously narrated in the case summary and was mildly immunocompromised as evidenced by an elevated plasma glucose level (Table 1) although not a known diabetic. Further investigations including fasting plasma glucose and glycated hemoglobin to ascertain whether he was diabetic or not were not done as the patient repeatedly declined follow-up visits probably because of

Table 1: Laboratory findings of the patient

Test	Value	Reference range
Hemoglobin (g/dl)	12.2	11–17.5
Random blood sugar (mmol/L)	11.4	>11.1
Erythrocyte sedimentation rate (ESR) (mm/h)	120	1–13
White-cell count (per mm ³)	16,100	4,000–10,000
Neutrophils (per mm ³)	10.3	2–8
Lymphocytes (per mm ³)	4	1–5
Eosinophils (per mm ³)	0.5	0–0.4
Platelet count (per mm ³)	299,000	150,000–400,000
Serum Galactomannan assay	18.03	≥0.5 is positive
HIV 1 and 11	Negative	
Total bilirubin (umol/l)	10	2–17
Conjugated bilirubin	3.5	2–17
Aspartate aminotransferase (iu/L)	29	Up to 40
Alanine aminotransferase (iu/l)	15	Up to 40
Alkaline phosphatase	267	Up to 270

HIV: Human immunodeficiency virus

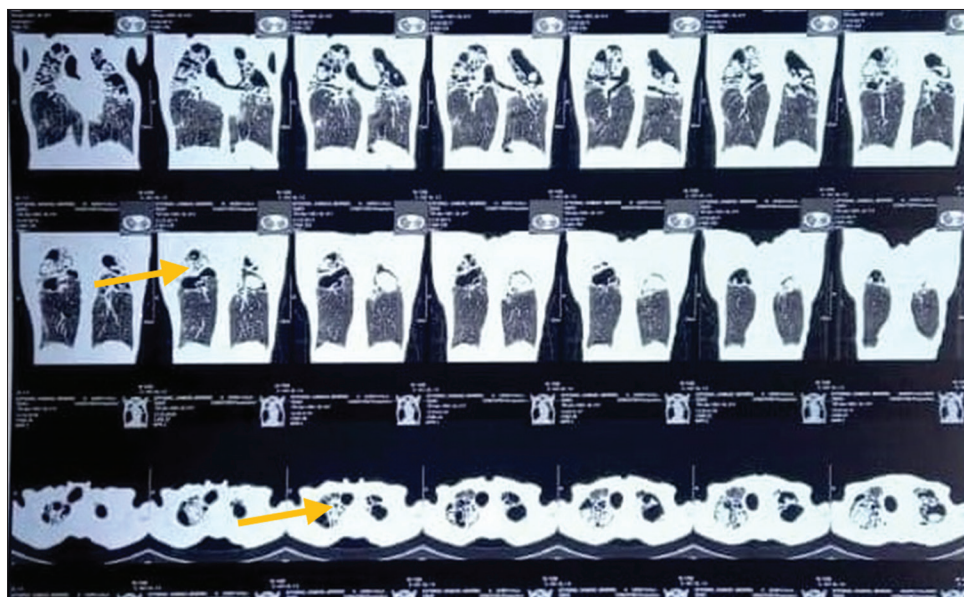


Figure 2: High-resolution computed tomography scan of the chest showing cavity with fungal balls and fibrosis in the right upper lung zone

financial constraints. Moreover, with itraconazole therapy, the patient completely recovered and engaged in his usual routine activities. His follow-up chest CT and X-ray could not be done due to similar reasons. The duration of his clinical presentation (1 year and 6 months) was well over the expected, as outlined by the ESCMID and ESR guidelines. This brings to the fore the several challenges impeding the diagnosis of CPA in our setting including poor awareness and a low index of suspicion on the part of attending clinicians as seen in our index case, which often results in misdiagnosis, delayed diagnosis, prolonged hospital stays, and economic losses [2]. This is despite studies done on CPA and case reports in Nigeria. Oladele *et al.* reported a CPA prevalence of 8.7% in Nigerian patients who were being managed as smear-negative TB and/or TB treatment failure [1]. Davies *et al.*, Gbajabiamila *et al.*, Garko *et al.*, and Ekwueme *et al.* have also documented case reports on CPA in Nigeria [5-8]. In addition, the lack of infrastructure, manpower, and diagnostic capacity particularly in the specialty of medical mycology are obstacles to the diagnosis of CPA in our region [1,9]. Our patient was however fortunate to have the correct diagnosis of CPA made on his condition which was possible due to the fungal diseases surveillance programs driven by the Medical Mycology Society of Nigeria.

CONCLUSION

CPA is not uncommon among patients presenting with pulmonary symptoms in Nigeria. A lot still has to be done to improve prompt diagnosis of CPA in our setting by driving awareness of CPA among clinicians, so they are able to recognize signs and symptoms and know the appropriate investigations to request. In addition, the need to ensure capacity building and infrastructure in the area of diagnostics cannot be overemphasized.

ACKNOWLEDGMENT

Many thanks to the Medical Mycology Society of Nigeria and her President, Associate Professor Rita Oladele for driving the fungal diseases surveillance program across several health institutions in Nigeria. This beautiful story may have been a tragedy without your efforts. God bless you.

AUTHORS' CONTRIBUTIONS

BEE Conceptualization, literature review and writing-original draft, review, and editing, CAA and DEE conceptualization, literature review participated in writing, LNO and BEM laboratory procedure, BBA, UAU, OII, CHN, and ROO constructive review and editing. All authors have agreed to the final version of this manuscript.

REFERENCES

1. Oladele RO, Irurhe NK, Foden P, Akanmu AS, Gbaja-Biamila T, Nwosu A, *et al.* Chronic pulmonary aspergillosis as a cause of smear-negative TB and/or TB treatment failure in Nigerians. *Int J Tuberc Lung Dis* 2017;21:1056-61.
2. Ekeng BE, Davies AA, Osaigbovo II, Warris A, Oladele RO, Denning DW. Pulmonary and extrapulmonary manifestations of fungal infections misdiagnosed as tuberculosis: The need for prompt diagnosis and management. *J Fungi* 2022;8:460.
3. Denning DW, Pleuvry A, Cole DC. Global burden of chronic pulmonary aspergillosis as a sequel to pulmonary tuberculosis. *Bull World Health Organ* 2011;89:864-72.
4. Denning DW, Cadranel J, Beigelman-Aubry C, Ader F, Chakrabarti A, Blot S, *et al.* Chronic pulmonary aspergillosis: Rationale and clinical guidelines for diagnosis and management. *Eur Respir J* 2016;47:45-68.
5. Gbajabiamila T, Bongomin F, Irurhe N, Nwosu AO, Oladele RO. Chronic pulmonary aspergillosis misdiagnosed as smear-negative pulmonary tuberculosis in a TB clinic in Nigeria. *J Adv Med Med Res* 2018;26:41816.
6. Davies AA, Adegbite IA, Akintan PE, Ibrahim UO, Adekoya AO, Oladele RO. Chronic cavitary pulmonary aspergillosis in an immunocompetent child. *Med Mycol Case Rep* 2022;37:33-6.
7. Ekwueme C, Otu AA, Chinenye S, Unachukwu C, Oputa RN, Korubo I, *et al.* Haemoptysis in a female with diabetes mellitus: A unique presentation

of chronic pulmonary aspergillosis, pulmonary tuberculosis, and *Klebsiella pneumoniae* co-infection. Clin Case Rep 2016;4:432-6.

8. Garko SB, Ekweani CN, Okpe IO. Pulmonary aspergillosis presenting as cor-pulmonale in an immunocompetent Nigerian man: A case report. Ann Afr Med 2002;1:112-5.
9. Osaigbovo II, Oladele RO, Orefuwa E, Akanbi OA, Ihekweazu C. Laboratory diagnostic capacity for fungal infections in Nigerian tertiary hospitals: A gap analysis survey. West Afr J Med 2021;38:1065-71.

Funding: Nil; Conflicts of interest: Nil.

How to cite this article: Ekeng BE, Akpu BB, Ahaneku CA, Udoh UA, Ita OI, Elem DE, *et al.* Subacute invasive pulmonary aspergillosis misdiagnosed as tuberculosis in a Nigerian man: A case report. Indian J Case Reports. 2022;8(11):369-372.