

## Complete response in metastatic breast cancer with visceral crisis using a combination of cyclin-dependent kinase 4/6 inhibitor and aromatase inhibitor: A case report from the eastern region of India

Sk Soel Ahmed<sup>1</sup>, Saroj Kumar Das Majumdar<sup>2</sup>, Sovan Sarang Dhar<sup>3</sup>, Bikash Ranjan Mahapatra<sup>4</sup>, Anupam Muraleedharan<sup>1</sup>, Sandip Kumar Barik<sup>5</sup>, Dillip Kumar Parida<sup>6</sup>

From <sup>1</sup>Junior Resident, <sup>2</sup>Additional professor, <sup>3</sup>Senior Research Associate, <sup>4</sup>Senior Resident, <sup>5</sup>Assistant Professor, <sup>6</sup>HOD, Department of Radiotherapy, All India Institute of Medical Sciences, Bhubaneswar, Odisha, India

### ABSTRACT

Patients with metastatic breast cancer (MBC) in visceral crisis require systemic chemotherapy. However, a coexisting cardiac failure that contradicts the use of systemic chemotherapy often demands an alternative treatment. Here, we report a case of hormone-receptor-positive MBC with cardiometabolic comorbidities. She was treated with a combination treatment of tablet Ribociclib (600 mg once daily for 21 days followed by 7 days gap) and tablet Letrozole (2.5 mg once daily). The patient had a complete metabolic response in 18-Fluorodeoxyglucose Positron Emission tomography-Computed Tomography (18F-FDG PET/CT), after 6 months of treatment. Combination treatment with Ribociclib and Letrozole is beneficial in postmenopausal females with hormone receptor-positive and human epidermal growth factor receptor 2 neu-negative MBC in visceral crisis who have a contraindication to chemotherapy.

**Key words:** 18F-FDG PET/CT, Case report, CDK 4/6 inhibitor, Complete metabolic response, Metastatic breast cancer


**B**reast cancer is the most commonly diagnosed malignancy as well as the leading cause of cancer-related mortality among females worldwide [1]. In India, breast cancer contributed 13.5% of cases to diagnosed malignancies and 10.6% to death due to malignancies during the year 2020 making it the most common cancer by incidence as well as mortality [2]. The prognosis of breast cancer is guarded in metastatic cases, in which over the years have invited extensive therapeutic research. Hormone-receptor-positive and human epidermal growth factor receptor (HER2/neu) negative metastatic breast cancer (MBC) patients have experienced better outcomes when treated with CDK 4/6 inhibitor in combination with a non-steroidal aromatase inhibitor (NSAI) as found out in multiple phase 3 randomized trials [2].

### CASE REPORT

A 44-year-old female who was diagnosed and treated with definitive intent for localized Stage II cancer of the left breast origin 5 years back, who presented with a complaint of progressive breathlessness. She is a known hypertensive, diagnosed for

4 years, and is on regular medication, and her breast primary at the time of diagnosis was infiltrating ductal carcinoma not otherwise specified, estrogen receptor/progesterone receptor both strongly positive (each with Allred scores 7/8), and HER2/neu-negative. She underwent left breast-conserving surgery, followed by adjuvant combination chemotherapy (Anthracycline based for six cycles), and external beam radiotherapy (EBRT). She had received whole breast EBRT to a dose of 50Gy/25 Fractions, 2Gy per fraction over 5 weeks followed by a boost to tumor bed of 10Gy in 5 fractions. After that, she was on tablet tamoxifen 20 mg once daily for 5 years and was on a regular 3 monthly follow-up. Three months before the precipitation of this breathlessness episode, the patient had undergone total abdominal hysterectomy and bilateral salpingo-oophorectomy for the diagnosis of dysfunctional uterine bleeding.

When evaluated for breathlessness, she was found to have bilateral pleural effusion, pulmonary artery thrombus, pericardial effusion, cardiomegaly, and moderate ascites. Hence, she was having poor performance status (Karnofsky Performance Score [KPS]-60). Cytological analysis of pleural effusion confirmed the presence of metastatic adenocarcinoma and staging 18F-FDG PET/CT revealed increased uptake in the left post-surgical bed (0.9 × 1.2 cm Standard Uptake Value [SUV] max-3.09),

Access this article online	
Received- -26 July 2022 Initial Review-17 Aug 2022 Accepted- 03 September 2022	Quick Response code 
DOI: 10.32677/ijcr.v8i9.3590	

**Correspondence to:** Sovan Sarang Dhar, Senior Research Associate, Department of Radiotherapy, All India Institute of Medical Sciences, Bhubaneswar - 751019, Odisha, India. E-mail: sovan.sarangdhar@gmail.com

© 2022 Creative Commons Attribution-NonCommercial 4.0 International License (CC BY-NC-ND 4.0).

bilateral pleural effusion, low-grade FDG uptake in the right inferior pulmonary vein thrombus, minimal pericardial effusion with cardiomegaly, and low-grade FDG avid para-aortic node ( $0.9 \times 0.7$  cm, SUVmax-3.85) (Fig. 1).

Laboratory investigations showed anemia (hemoglobin-10 mg/dl) with leukocytosis (white blood cell count- 11700/cumm), normal kidney function test (urea -30, creatinine-0.6), and slightly raised D-dimer value (548 ng/ml), while the tumor markers carcinoembryonic antigen (CEA) and Cancer Antigen 15-3 (CA15-3) were not raised (CEA - 1.2 ng/ml, CA 15-3-5 U/ml). Electrocardiogram (ECG) was within normal limits, but the echocardiogram suggested a low left ventricular ejection fraction of 44%, which invited caution against the use of chemotherapy, especially a combination regimen from the cardiology team. The final clinical impression was hormone-receptor-positive and HER2/neu-negative MBC with compromised cardiac function.

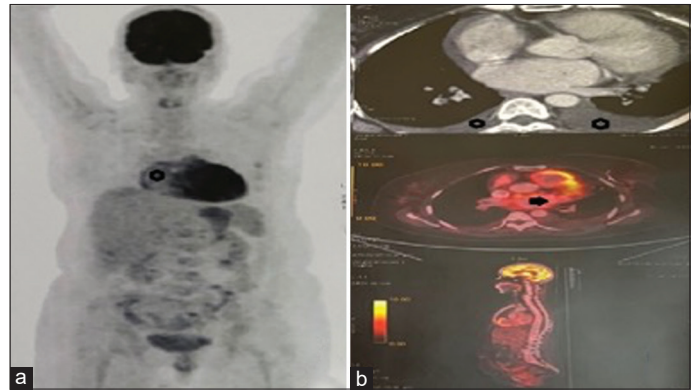
The patient was advised for treatment with Tablet Ribociclib (600 mg orally once daily for 21 days followed by seven days gap) and Tablet Letrozole (2.5 mg orally once daily). Complete blood cell count, liver function test, renal function test, and ECG were repeated every month, and following normal report, the patient was continued on the above treatment schedule. There was a significant subjective response after 1 month. Assessment 18F-FDG PET/CT at the end of 6 months of combined Ribociclib and Letrozole suggested complete metabolic response at all metastatic sites (Fig. 2). The patient tolerated well without any grade 3/4 adverse events.

## DISCUSSION

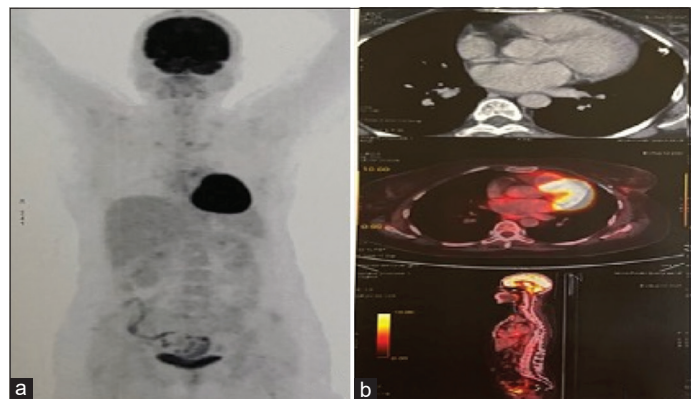
Breast cancer is the leading cause of cancer as well as cancer-associated deaths in India [2]. Its incidence is steadily increasing and poses a significant challenge for cancer care in the country [3].

The prognosis of breast cancer is dependent on multiple factors (patient, tumor, and treatment-related). Among them, tumor, nodes, and metastases staging hold the highest ground. In the Western world, the median overall survival [OS] and 5-year cause-specific survival in MBC patients are 3 years and 30%, respectively [4,5]. The outcome in MBC depends on the biological subtype too. Moreover, the prognosis of the “hormone receptor (HR)-positive/HER2/neu” negative variety is better than others [5].

The management of MBC comprises systemic treatments and local treatments to palliate symptoms and prolong survival. The local treatment options include radiotherapy and limited surgery. The systemic treatment in MBC has been evolving continuously, a highlight of which has been target-oriented drug development and delivery. The anti-HER2neu drugs such as Trastuzumab, Pertuzumab, Lapatinib, Ado-trastuzumab emtansine (T-DM1), and fam-trastuzumab deruxtecan-nxki are in vogue. They are used alone or in combination with chemotherapeutic drugs and, thus, have increased survival in HER2/neu receptor overexpressing MBC [6]. Selective reversible CDK 4/6 inhibitors such as Palbociclib, Ribociclib, and Abemaciclib interact and prevent the inactivation of tumor suppressor retinoblastoma gene and thus prevent tumor growth [7]. Results of available randomized



**Figure 1:** (a-b) 18F-FDG PET/CT revealed increased uptake in the left post-surgical bed ( $0.9 \times 1.2$  cm standard uptake value [SUV] max-3.09), bilateral pleural effusion, low-grade FDG uptake in the right inferior pulmonary vein thrombus, minimal pericardial effusion with cardiomegaly, and low-grade FDG avid para-aortic node ( $0.9 \times 0.7$  cm, SUVmax-3.85)



**Figure 2:** (a-b) Assessment 18F-FDG PET/CT at the end of 6 months of combined Ribociclib and Letrozole that showed complete metabolic response at all metastatic sites

control trials involving CDK 4/6 inhibitors in combination with NSAI in postmenopausal MBC patients who have positive hormone receptor and negative HER2neu receptor benefit in terms of progression-free survival [8-11]. OS benefit was noted in pre/perimenopausal MBC patient population receiving Ribociclib and NSAI/Tamoxifen at 3.5 years of follow-up (70% vs. 40%, hazard ratio 0.71, 95% confidence interval 0.54–0.95) in MONALEESA 7 trial [12].

The diagnosis of local recurrence and distant metastasis with a visceral crisis in the case of breast cancer was based on clinical features, FDG-PET/CT assessment, laboratory values, and cytopathological confirmation [4]. The progressive breathlessness on presentation was attributed to bilateral malignant pleural effusion, pericardial effusion, decreased left ventricular systolic function, malignant pulmonary artery thrombus, and ascites. The first line of therapy in such scenarios is combination chemotherapy. The response rate using taxane-based and anthracycline-based chemotherapy regimens in MBC as the first line of treatment ranges from 47% to 55% [13-15]. An ejection fraction of 44% in this patient was a strict caution against the usage of combination chemotherapy. The overall response rate of CDK 4/6 inhibitor in combination with NSAI/Fulvestrant is

approximately 42% in HR+/Her2neu – MBC patients [9,16]. Even though prospective phase 2/3 data using CDK 4/6 inhibitor-based regimen for the management of HR-positive HER2neu-negative MBC in visceral disease is available for the drug Abemaciclib (MONARCH-1/3) [10,17], it was unavailable for patient use at the time of decision making, pending approval from the relevant authority in India. After a multispecialty tumor board meeting followed by a discussion with the patient and family members, she was started on tablet Ribociclib in combination with tablet Letrozole. The response in terms of improvement in symptoms as well as clinical parameters was noticeable within 2 weeks of the start of treatment. The KPS recovered steadily to become 80 by the end of the 2<sup>nd</sup> month of treatment. At the end of 6 months of assessment, the patient was asymptomatic and FDG PET-CT suggested a complete clinical response both in measurable as well as non-measurable disease. No dose-limiting hematological toxicity, serum transaminase elevation, or QT prolongation were noted during treatment.

The encouraging response to the combination of drugs (tablet Ribociclib and tablet Letrozole), in addition to the ease of oral administration, in such a difficult clinical situation, is worthy of documentation.

## CONCLUSION

The combination of CDK 4/6 inhibitor and NSAI can be a viable option in a patient of HR+/Her2/neu – MBC with contraindication for chemotherapy. Complete response at 6 months from the start of therapy is encouraging and invites response assessment studies in similar situations that can pave way for practice-changing studies in the future.

## REFERENCES

- Sung H, Ferlay J, Siegel RL. Global cancer statistics 2020: GLOBOCAN estimates of incidence and mortality worldwide for 36 cancers in 185 countries. *CA Cancer J Clin* 2021;71:209-49.
- IARC Inc. GLOBOCAN India Fact Sheet 2020. Vol. 361. Lyon, France: IARC Inc.; 2020.
- Mathur P, Sathishkumar K, Chaturvedi M. Cancer statistics, 2020: Report from national cancer registry programme, India. *JCO Glob Oncol* 2020;6:1063-75.
- Cardoso F, Senkus E, Costa A. 4<sup>th</sup> ESO-ESMO international consensus guidelines for advanced breast cancer (ABC 4). *Ann Oncol* 2018;29:1634-57.
- Shumway DA, Sabolch A, Jaggi R. Breast cancer. In: Lo S, Teh B, Jiang GL, Mayr N, editors. *Controversies in Radiation Oncology*. Cham: Springer; 2016.
- Macdonald S, Oncology R, General M. Breast cancer breast cancer. *J R Soc Med* 2016;70:515-7. Available from: <https://www2.tri-kobe.org/nccn/guideline/breast/english/breast.pdf> [Last accessed on 2022 Feb 28].
- Laderian B, Fojo T. CDK4/6 Inhibition as a therapeutic strategy in breast cancer: Palbociclib, ribociclib, and abemaciclib. *Semin Oncol* 2017;44:395-403.
- Finn RS, Martin M, Rugo HS, Jones S, Seock-Ah Im, Gelmon K, *et al.* Palbociclib and letrozole in advanced breast cancer. *N Engl J Med* 2016;375:1925-36.
- Hortobagyi GN, Stemmer SM, Burris HA, Yap YS, Sonke GS, Paluch-Shimon S, *et al.* Updated results from MONALEESA-2, a phase III trial of first-line ribociclib plus letrozole versus placebo plus letrozole in hormone receptor-positive, HER2-negative advanced breast cancer. *Ann Oncol* 2018;29:1541-7.
- Dickler MN, Tolaney SM, Rugo HS, Cortés J, Diéras V, Patt D, *et al.* MONARCH 1, a phase II study of abemaciclib, a CDK4 and CDK6 inhibitor, as a single agent, in patients with refractory HR+/HER2 metastatic breast cancer. *Clin Cancer Res* 2017;23:5218-24.
- Sledge GW, Toi M, Neven P, Sohn J, Inoue K, Pivrot X, *et al.* The effect of abemaciclib plus fulvestrant on overall survival in hormone receptor-positive, ERBB2-negative breast cancer that progressed on endocrine therapy MONARCH 2: A randomized clinical trial. *JAMA Oncol* 2020;6:116-24.
- Im SA, Lu YS, Bardia A, Harbeck N, Colleoni M, Franke F, *et al.* Overall survival with ribociclib plus endocrine therapy in breast cancer. *N Engl J Med* 2019;381:307-16.
- Nabholtz JM, Falkson C, Campos D. Docetaxel and doxorubicin compared with doxorubicin and cyclophosphamide as first-line chemotherapy for metastatic breast cancer: Results of a randomized, multicenter, phase III trial. *J Clin Oncol* 2003;21:968-75.
- Biganzoli L, Cufer T, Bruning P, Coleman R, Duchateau L, Calvert AH, *et al.* Doxorubicin and paclitaxel versus doxorubicin and cyclophosphamide as first-line chemotherapy in metastatic breast cancer: The european organization for research and treatment of cancer 10961 multicenter phase III trial. *J Clin Oncol* 2002;20:3114-21.
- Langley RE, Carmichael J, Jones AL, Cameron DA, Qian W, Uscinska B, *et al.* Phase III trial of epirubicin plus paclitaxel compared with epirubicin plus cyclophosphamide as first-line chemotherapy for metastatic breast cancer: United Kingdom national cancer research institute trial AB01. *J Clin Oncol* 2005;23:8322-30.
- Finn RS, Crown JP, Ettl J, Schmidt M, Bondarenko IM, Lang I, *et al.* Efficacy and safety of palbociclib in combination with letrozole as first-line treatment of ER-positive, HER2-negative, advanced breast cancer: Expanded analyses of subgroups from the randomized pivotal trial PALOMA-1/TRIO-18. *Breast Cancer Res* 2016;18:1-14.
- Johnston S, Martin M, Di Leo A, Seock-Ah Im, Awada A, Forrester T, *et al.* MONARCH 3 final PFS: A randomized study of abemaciclib as initial therapy for advanced breast cancer. *NPJ Breast Cancer* 2019;5:5.

*Funding: Nil; Conflicts of interest: Nil.*

**How to cite this article:** Ahmed SS, Majumdar SK, Dhar SS, Mahapatra BR, Muraleedharam A, Barik SK, *et al.* Complete response in metastatic breast cancer with visceral crisis using a combination of cyclin-dependent kinase 4/6 inhibitor and aromatase inhibitor: A case report from the Eastern region of India. *Indian J Case Reports*. 2022;8(9):288-290.