

Role of cardiac rehabilitation in patient with pulmonary hypertension on functional capacity and quality of life

Ronaldo Simamora¹, Christian Rendy Chandra², Ade Meidian Ambrari³, Renan Sukmawan⁴

From ¹MD, Resident Physician, ²MD, BMedSci, ³MD, FIHA, ⁴MD, PhD, FIHA, FACC, Department of Cardiology and Vascular Medicine, Universitas Indonesia, National Cardiovascular Centre Harapan Kita, West Jakarta, Indonesia

ABSTRACT

Patients with pulmonary hypertension (PH) continue to develop significant exertional symptoms and reduced quality of life despite receiving pharmacological therapy. Guidelines highlighted the importance of rehabilitation as part of management in PH. However, the cardiac rehabilitation program is still underused. We present a case of functional capacity improvement in patients with surgically corrected secundum atrial septal defect (ASD) with PH who underwent cardiac rehabilitation program. A 30-year-old female with a previous history of surgically corrected ASD went to our rehabilitation program in our hospital. She had a 3-weeks program of rehabilitation, and there were improvements in symptoms, clinical parameters, and quality of life after completion of the cardiac rehabilitation program. Rehabilitation can be an adjuvant for pharmacological therapy for PH that has been proven to improve the quality of life in patients with PH.

Key words: Pulmonary hypertension, Quality of life, Rehabilitation, Secundum atrial septal defect

Pulmonary hypertension (PH) is a severe and devastating condition that may lead to high morbidity and mortality [1]. It is characterized by progressive increases in pulmonary artery pressure and pulmonary vascular resistance that may eventually lead to right heart failure. It was reported that patients with PH generally had a worse prognosis than patients with advanced disease [2]. Pharmacotherapy for PH has been established for years to improve the prognosis of patients with PH; yet, the impact of pharmacotherapy remains unsatisfactory [3]. There are three well-known pathways for PH pathophysiology and drugs targeting this pathway that has been well-established in clinical practice, such as PDE-5 inhibitors, prostanoid, and endothelin receptor antagonist. However, patients continue to develop significant exertional symptoms and reduced quality of life [4]. The European Society of Cardiology (ESC) has mentioned that exercise testing is associated with the prognosis of patients with PH. It suggested that prognosis can be improved by improving functional capacity. This can be achieved by cardiac rehabilitation [5].

We present an interesting case of functional capacity improvement in a patient with surgically corrected secundum atrial septal defect (ASD) with PH who underwent cardiac rehabilitation program.

CASE REPORT

A 30-year-old female was referred to our hospital to undergo surgical secundum ASD correction. Before surgical time, she complained of orthopnea and dyspnea during activity for 3 months, so the patient's activity was limited. She had a history of normal labor of a child 5 months before the surgical correction. There were no symptoms during pregnancy. There was no significant previous family or other disease histories.

Before the surgery, her vital sign was normal, with a blood pressure of 100/62 mmHg, heart rate (HR) of 70 bpm, respiratory rate of 17 times/min, and SaO₂ of 97%. Her basal metabolic rate (BMI) was 16.7 kg/m². On cardiac auscultation, no murmur or gallop was found, but there was the accentuation of S2 sound without any split. Lung examination showed vesicular breathing with no rales or wheezing and other findings within normal limits.

The electrocardiography showed sinus rhythm, HR of 85 beats/min, right axis deviation, and right ventricular hypertrophy. Chest X-ray showed a cardiothoracic ratio of 61%, normal aortic segment, prominent pulmonic segment, downward apex, and pruning pulmonary vasculature. Echocardiography showed normal left ventricle size and thickness with an ejection fraction of 66%, dilated left atrium, right atrium, and right ventricle. There was an interatrial septum gap with a diameter of 18–27 mm,

Access this article online

Received- 08 July 2022
Initial Review- 27 July 2022
Accepted- 12 aug 2022

DOI: 10.32677/ijcr.v8i8.3566

Quick Response code



Correspondence to: Ronaldo Simamora, MD, Resident Physician, Department of Cardiology and Vascular Medicine, Universitas Indonesia, National Cardiovascular Centre Harapan Kita, West Jakarta, Indonesia. E-mail: mamoraonald09@gmail.com

© 2022 Creative Commons Attribution-NonCommercial 4.0 International License (CC BY-NC-ND 4.0).

left to right shunt, mild tricuspid regurgitation (TR), and a high probability of PH. There were inadequate rims; hence, the patient was not a candidate for device closure of secundum ASD. Right heart catheterization showed bidirectional shunt secundum ASD with TR severe and PH with high flow high resistance.

After the surgical secundum ASD closure, she was planned for cardiac rehabilitation phase II to improve her quality of life. It was expected that cardiac rehabilitation might improve the patient's VO₂ max and quality of life. We prescribed 12 sessions of cardiac exercise training to the patient, and we compared symptoms and clinical parameters such as echocardiography, NT pro-BNP, and 6 min walk test between pre- and post-cardiac rehabilitation. Before rehabilitation interventions, the patient completed the Self-Reported Functional Status questionnaire to assess the quality of life before and after the rehabilitation [6]. The exercise was administered and supervised 7 days/week, and intensity was individually adjusted according to subjective physical exertion and safety measures peak HR <120 bpm and oxygen saturation >90%. Moreover, training consists of guided walks for 60 min, dumbbell training of single muscle groups with low weights for 30 min, and respiratory therapy for 30 min for at least 5 days a week. Mental gait training was introduced to patients to improve the estimation of their physical abilities and limitations.

After rehabilitation, we found several improvements, such as a functional class from class III to class II, reduced NT pro-BNP, and improved PH measured from echocardiography (Table 1 and Fig. 1). We also performed the treadmill test with Bruce protocol at the end of cardiac rehabilitation, and the test duration was 06:01 min with an aerobic capacity of 6,11 METS.

DISCUSSION

Cardiac rehabilitation in PH is part of a recommended management plan for patients with PH. It is proven to improve exercise tolerance and quality of life. A study by Talwar *et al.* in 2017 showed that cardiac rehabilitation improved exercise capacity in 18 patients with PH who received optimal medical therapy [7].

The precise mechanism in which exercise training contributes to improvement in PH is unclear. However, there was growing evidence on the mechanism of exercise training in P, such as the role of H₂O₂-induced angiogenesis that increases pulmonary vascular reserve during exercise. Furthermore, there was a role of vascular endothelial growth factor gene expression facilitated by exercise training that also induced angiogenesis [8]. In our patient, after 3 weeks of the training program, we observed the same result as previous studies mentioned, such as improvement in exercise capacity, reduced symptoms, and increased quality of life (based on the SF-36 questionnaire). There was an increased 6MWD from 390 m to 450 m, an improvement of the echocardiography profile.

Our rehabilitation program was based on Keusch *et al.*, which consisted of (a) aerobic exercise training such as low interval bicycle ergometer training (average workloads only 5–40 watts)

Table 1: Several parameters before and after the cardiac rehabilitation program

	Pre-cardiac rehabilitation	Post-cardiac rehabilitation
Clinical Sign	Present	Absent
Progression of symptom	Slow	No
Syncope	Absent	Absent
WHO functional class	III	II
6 MWD	390 m	450 m
NT Pro BNP	1462	1081
Echocardiography	TR Vmax 3.64 m/s TVG 53 mmHg	TR Vmax 2.8 m/s TVG 31 mmHg
Hemodynamic (echo)	RAP 10 CI 2.4	RAP 8 CI 2.9
SF 36	1540	3345

6MWD: 6-minute walk distance, WHO: World health organization, NT pro BNP: n terminal pro-brain natriuretic peptide, RAP: Right atrial pressure, CI: Cardiac index, SF 36: The self-reported functional status, TR: Tricuspid regurgitation, TVG: Tricuspid valve gradient

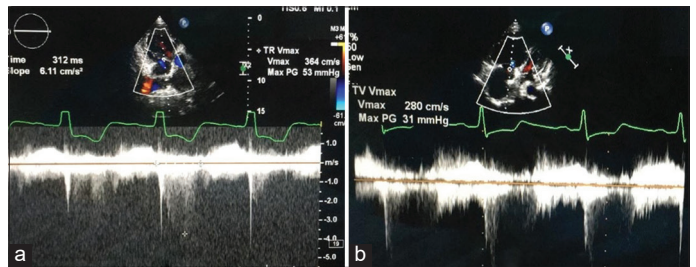


Figure 1: Echocardiography parameters before (a) and after (b) cardiac rehabilitation program

for 10–25 min in a supervised and monitored setting daily, (b) resistance training using low dose dumbbell training of single muscle groups with low weights (5 times/week), (c) respiratory therapy (patients taught perception of breathing and methods to relieve dyspnea (5 times/week), and (d) mental walking training, in which patients educated in perceiving their physical limitation (several times/week) [9].

Improving the quality of life should be considered in patients with PH. A recent meta-analysis published by Zhao *et al.* showed that exercise training significantly enhances the quality of life evaluated from the SF-36 questionnaire in patients with PH [10]. We observed a significant improvement in quality of life that the SF-36 score was improved from 1540 to 3345. Based on a recommendation from ESC, patients with PH were suggested to have an exercise program as an adjuvant therapy to maintain their functional capacity and improve their quality of life [5]. Based on the ESC risk assessment of patients with PH, our patient was categorized as a high-risk patient (to have >10% estimated 1-year mortality) before the surgical correction [5]. After the cardiac rehabilitation program, our patient showed improvement in low to intermediate risk (to have <5% estimated 1-year mortality).

CONCLUSION

We present a case of secundum ASD with PH post-surgically corrected ASD closure that improved clinical signs, functional status, and quality of life after cardiac rehabilitation. Exercise training has been proven safe and beneficial as add-on therapy in patients with PH.

AUTHORS' CONTRIBUTIONS

- Ronaldo Simamora: Conception of the work, design of the work, acquisition of data, analysis and interpretation of data, drafting the article, revising it critically for important intellectual content, final approval of the version to be published, agreement to be accountable for all aspects of the work in ensuring that questions related to the accuracy or integrity of any part of the work are appropriately investigated and resolved.
- Christian Rendy Chandra: Conception the work, design of the work, revising it critically for important intellectual content, final approval of the version to be published, and agreement to be accountable for all aspects of the work in ensuring that questions related to the accuracy or integrity of any part of the work are appropriately investigated and resolved.
- Ade Meidian Ambrari: Design of the work, interpretation of data, revising it critically for important intellectual content, final approval of the version to be published, and agreement to be accountable for all aspects of the work in ensuring that questions related to the accuracy or integrity of any part of the work are appropriately investigated and resolved.
- Renan Sukmawan: Design of the work, interpretation of data, revising it critically for important intellectual content, final approval of the version to be published, and agreement to be accountable for all aspects of the work in ensuring that questions related to the accuracy or integrity of any part of the work are appropriately investigated and resolved.

ACKNOWLEDGMENT

We thank Mr. Nurdin (National Cardiovascular Centre Harapan Kita, Indonesia) for providing technical aspect during cardiac rehabilitation program.

REFERENCES

1. Simonneau G, Montani D, Celermajer DS, Denton CP, Gatzoulis MA, Krowka M, *et al.* Haemodynamic definitions and updated clinical classification of pulmonary hypertension. *Eur Respir J* 2019;53:1801913.
2. Farber HW, Miller DP, Poms AD, Badesch DB, Frost AE, Rouzic EM, *et al.* Five-year outcomes of patients enrolled in the REVEAL registry. *Chest* 2015;148:1043-54.
3. Vecchia LA, Bussotti M. Exercise training in pulmonary arterial hypertension. *J Thorac Dis* 2018;10:508-21.
4. Arena R, Cahalin LP, Borghi-Silva A, Myers J. The effect of exercise training on the pulmonary arterial system in patients with pulmonary hypertension. *Prog Cardiovasc Dis* 2015;57:480-8.
5. Galiè N, Humbert M, Vachiery JL, Gibbs S, Lang I, Torbicki A, *et al.* 2015 ESC/ERS Guidelines for the diagnosis and treatment of pulmonary hypertension. *Eur Heart J* 2016;37:67-119.
6. Murphy M, Hollinghurst S, Salisbury C. Identification, description and appraisal of generic PROMs for primary care: A systematic review. *BMC Fam Pract* 2018;19:41.
7. Talwar A, Sahni S, Verma S, Khan SZ, Dhar S, Kohn N. Exercise tolerance improves after pulmonary rehabilitation in pulmonary hypertension patients. *J Exerc Rehabil* 2017;13:214-7.
8. Galiè N, Corris PA, Frost A, Giris RE, Granton J, Jing ZC, *et al.* Updated treatment algorithm of pulmonary arterial hypertension. *J Am Coll Cardiol* 2013;62:D60-72.
9. Keusch S, Turk A, Saxer S, Ehlken N, Grunig E, Ulrich S. Rehabilitation in patients with pulmonary arterial hypertension. *Swiss Med Wkly* 2017;147:1-5.
10. Zhao YL, Yuan P, Zhao QH, Gong SG, Zhang R, He J, *et al.* Comparative effectiveness of exercise training for patients with chronic thromboembolic pulmonary hypertension after pulmonary endarterectomy: A systematic review and meta-analysis. *Front Cardiovasc Med* 2021;8:1-11.

Funding: None; Conflicts of Interest: None Stated.

How to cite this article: Simamora R, Chandra CR, Ambrari AM, Sukmawan R. Role of cardiac rehabilitation in patient with pulmonary hypertension on functional capacity and quality of life. *Indian J Case Reports*. 2022;8(8):259-261.