Case Report

Pregnancy with COVID-19-related severe ARDS: A case report from rural critical care unit in India

Harish Handyal[1], Gopi Kumar Gouni[2], Anna Gangadhar Reddy[3], Jyothi Suchithra[4]

From [1]Chief Intensivist, [2]Consultant Intensivist, Department of Critical Care Unit, [3]Consultant Anesthesiologist, Department of Anesthesiology, [4]HOD, Department of Obstetrics and Gynaecology, RDT Hospital, Anantapur, Andhra Pradesh, India

ABSTRACT

Acute Respiratory Distress Syndrome (ARDS) can frequently occur as a complication of Coronavirus Disease 19 (COVID-19). As a result of the increasing number of COVID-19 cases around the world, it is inevitable that ARDS will complicate some pregnancies with COVID-19. At present, there are scarce data to guide decision-making on the timing of delivery for these patients. We present a case of a pregnant woman at 30 weeks gestation with COVID-19-related ARDS, who was successfully managed with lung protective strategies for mechanical ventilation and early delivery by cesarean section in the rural critical care setting.

Key words: Acute respiratory distress syndrome, Coronavirus disease 19, Mechanical ventilation, Pregnancy

The COVID-19 pandemic became the most threatening global health crisis of our time. The causative virus, Severe acute respiratory syndrome coronavirus 2 (SARS-CoV-2), affects a wide spectrum of people, ranging from the healthy to those with multiple comorbid conditions. Management protocols are variable within and between institutions and change frequently as more data and evidence accumulates [1]. In the absence of any definitive therapy, the cornerstone of COVID-19 treatment varies from symptomatic care management to intensive care treatment. The mechanical, immunological, and hormonal changes of pregnancy contribute to this higher risk and thereby increasing mortality rates in this population [2]. There has been no uniform approach in managing critically ill pregnant women with COVID-19 and the unique physiological and anatomical changes present an unprecedented challenge in managing this vulnerable population. During this outbreak period, pregnant women and their newborns were also afflicted significantly. The current evidence demonstrates that 0.1–0.2% of all pregnancies are complicated by respiratory failure [3]. However, little contemporary data are available to guide the multidisciplinary team through decisions regarding intensive care strategies, optimal maternal-fetal surveillance, route, and timing of delivery.

We present a case of a woman at 30 weeks gestation who had a rapid clinical deterioration from COVID-19-related acute respiratory distress syndrome (ARDS) and was successfully managed through a multidisciplinary team approach to optimize both maternal and neonatal outcomes.

Access this article online	
Received - 19 June 2022 Initial Review - 07 July 2022 Accepted - 18 July 2022	Quick Response code
DOI: 10.32677/ijcr.v8i7.3526	

CASE REPORT

A 26-year-old lady with 30 weeks of pregnancy was admitted to our intensive care unit with complaints of fever and cold and cough for 7 days and breathless for 2 days. Her nasopharyngeal and throat swabs confirmed positive for SARS-CoV-2 infection after recent known exposure to a positive household contact.

On examination, she was conscious with severe tachypnea (respiratory rate: 40/min), dyspnea, and tachycardia (heart rate: 126/min). Her oxygen saturation was 78% on 15 l of O2 support. Examination of the chest revealed extensive rales and bronchophony in both lungs.

The chest radiograph demonstrated bilateral non-homogeneous opacities consistent with ARDS (Fig. 1). Her arterial blood gas analysis showed severe hypoxemia with a PaO_2/FiO_2 ratio of 96. On investigation, her hemoglobin was 9.1 g %, white blood count was 14400, and platelet count was within normal limits. Renal function tests, liver function tests, blood sugar levels, and serum electrolytes were within normal limits. Her C-reactive protein and lactate dehydrogenase levels were high (19.9 mg/dl and 686 IU/L respectively). 2D echo (FATE: focused assessed transthoracic echo) examination revealed mild pulmonary hypertension (PASP: Pulmonary artery systolic pressure: 30) with mild left ventricular dysfunction

Correspondence to: Dr. Harish Handyal, Door No 06, RDT Hospital campus, Kadri Road, Anantapur - 515 661, Andhra Pradesh, India. E-mail: drharry69@gmail.com

© 2022 Creative Commons Attribution-NonCommercial 4.0 International License (CC BY-NC-ND 4.0).

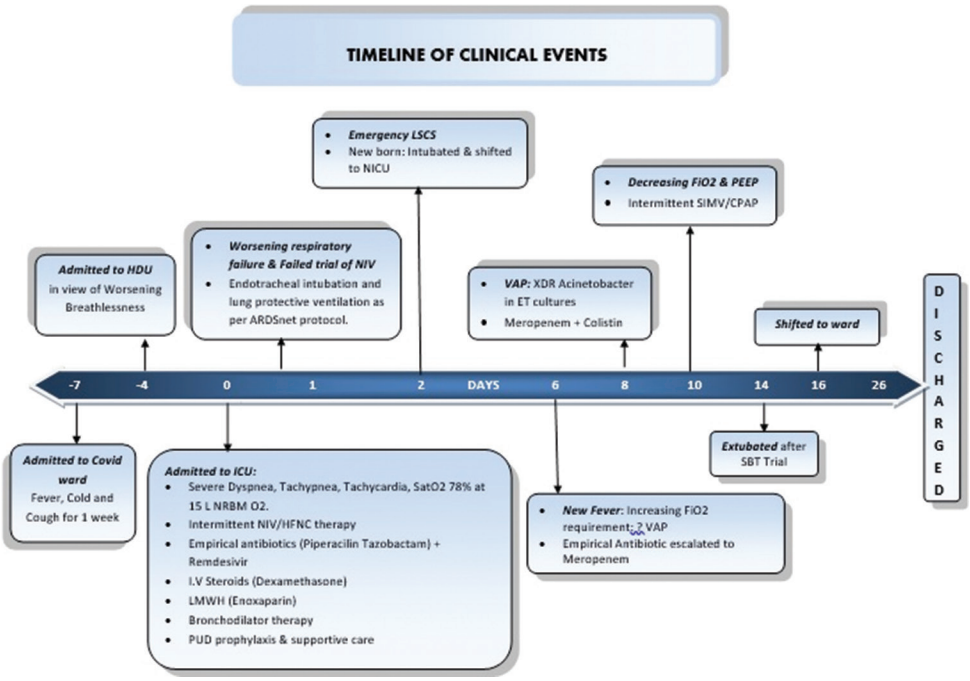

Figure 1: Timeline of clinical events

(Ejection fraction: 45–50%). She was provisionally diagnosed as primigravida with febrile illness (COVID: Stage 3) in respiratory failure suggestive of bilateral severe pneumonia in ARDS.

She was started on a trial of intermittent non-invasive ventilation (NIV)/HFNC therapy, empirical antibiotics (Piperacillin Tazobactam: 3.375gm IV 6th hourly), antivirals (Remdesivir 200 mg stat followed by 100 mg IV per day), intravenous steroids (Dexamethasone: 6 mg once daily), low molecular weight heparin (Enoxaparin: 40 mg s/c once daily), bronchodilator therapy, peptic ulcer disease prophylaxis, and supportive care as per protocol.

Eight hours after the admission to ICU, her respiratory status declined rapidly and was maintaining SpO2 of 80% on NIV with FiO_2 of 100%. In view of worsening respiratory failure and failed trial of NIV, she was intubated and mechanically ventilated as per the ARDSnet protocol (Fig. 2).

The next day, she was sedated and paralyzed on pressure regulated volume controlled mode. Her gas exchange was still poor (PaO_2/FiO_2 ratio: 69), Ppeak and Pplat pressures were high and hypercarbia was persistent. The case was discussed with the obstetrician regarding the benefits of terminating the pregnancy for better ventilation dynamics. Hence, induction of labor started (Misoprostol) for the termination of pregnancy. On day 2 morning, in view of the failure of medical termination of pregnancy and rapidly declining respiratory status, emergent bedside preterm cesarean delivery was performed. The preterm male infant, weighing 1400 g was intubated and shifted to NICU for further management. Postoperatively, her gas exchange was improving, peak and plateau pressures were decreasing, and hypercarbia was resolving. From day 5 evening, she developed two spikes of fever followed by a gradual increase in FiO_2 requirement and a chest X-ray (Fig. 1) revealed new bilateral infiltrates

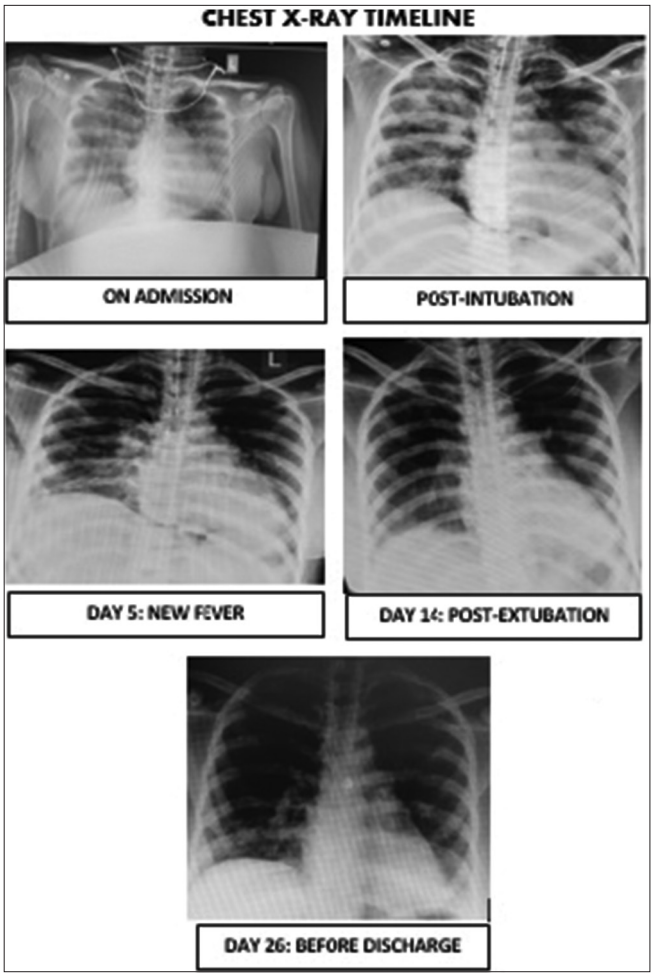

Figure 2: Chest X-ray timeline

(ventilator-associated pneumonia). Hence, antibiotic therapy escalated to Meropenem after sending appropriate cultures. On day 8 morning, ET cultures grew *Acinetobacter baumanii* (XDR:

Extensively drug-resistant); hence, Colistin was added as per the sensitivity report.

Over the next several days, oxygenation continued to improve, peak and plateau pressures were decreasing and FiO_2 and PEEP were gradually weaned. On day 14, the patient was successfully liberated from mechanical ventilation after a trial of Spontaneous breathing trial. Post-extubation, her chest X-ray showed marked improvement (Fig. 1). Subsequently, she was shifted to the ward on 1L O2 support for further management on day 16. Eventually, both mother and child recovered and were discharged from the hospital on day 26.

DISCUSSION

As the COVID-19 pandemic continues to spread, pregnant patients will continue to be affected as well. Although the incidence of critical illness in pregnancy appears to be low [4], a myriad of physiologic changes occur in pregnancy, including elevation of the diaphragm, decrease in total lung capacity, and lung compliance. Despite these changes, the management of ARDS in pregnancy does not significantly vary from that of the non-pregnant patient [5]. Acute respiratory failure due to COVID-19 in pregnancy is not very common. In one review, only 1.6% of more than 400,000 women hospitalized for childbirth had COVID-19, and of these, only 86 needed mechanical ventilation [6].

Lung protective strategies must be followed which include lower tidal volume (6 ml/kg) and increasing the respiratory rate to achieve adequate minute ventilation appropriate for the physiological changes in pregnancy as much as possible. Adjust or increase the positive-end expiratory pressure (PEEP) and decrease the fraction of inspired oxygen (FiO_2) by following the PEEP: FiO_2 table and plateau pressure should be kept ≤30 cm H2O. More recently, driving pressure (plateau pressure-PEEP) is considered to be more important than tidal volume and plateau pressure and is worth monitoring [7].

For pregnant ARDS patients, both fetal and maternal life-threatening distress are a challenge for intensivists. This study suggests that early delivery combined with a lung-protective ventilation strategy may provide significantly better fetal and maternal outcomes [8]. Although mechanical ventilation alone should not be an indication for delivery, it is reasonable to consider delivery in the setting of worsening critical illness [9]. At present, it is recommended that the decision for delivery should be individualized, taking into account gestational age, maternal status, and fetal status. Potential indications for delivery include cardiopulmonary arrest, severe ARDS, or barotrauma [10,11].

Delivery in respiratory-compromised pregnant patients has previously been seen to improve oxygen requirements. However, the effect was neither dramatic nor uniform enough to routinely recommend it [12]. Similarly, in a recent retrospective and observational study performed on pregnant women with COVID-19, four out of seven non-intubated patients in respiratory distress had an improvement in oxygenation within hours to days after delivery. Although the possibility of uterine decompression improving respiratory status was mentioned, no specific mechanism was proposed nor a recommendation given [13]

In our case, the pregnant patient was critically ill with ARDS from COVID-19. We followed lung protective strategies for mechanical ventilation, plateau pressure was kept below 30 cmH2o and driving pressures were monitored. Although dexamethasone was administered early in the course, the dramatic improvement in her oxygenation and plateau pressures after delivery of the baby suggests that uterine decompression may have been a significant contributing factor in her recovery.

CONCLUSION

Our experience suggests that pregnant women are at high risk of complications such as ARDS requiring mechanical ventilation from COVID-19. We also recommend to follow lung-protective strategies as per ARDSnet ventilation protocol as necessary for patients in ARDS. Early delivery of a pregnant patient with worsening critical illness may result in the improvement in the mother's condition. The timing to terminate a pregnancy is a critical decision necessitating proper cooperation with the obstetric and neonatology departments. Institution of appropriate therapy without delay results in better maternal and fetal outcomes, even in a rural critical care setting.

REFERENCES

1. Chong J, Ahmed S, Hill K. Acute respiratory distress syndrome in a pregnant patient with COVID-19 improved after delivery: A case report and brief review. Respir Med Case Rep 2020;31:101171.
2. Huang C, Wang Y, Li X. Clinical features of patients infected with 2019 novel coronavirus in Wuhan, China. Lancet 2020;395:497-506.
3. Vale P, Fernandes AC, Guzen FP, Pinheiro FI, de Azevedo EP, Cobucci RN. Susceptibility to COVID-19 in pregnancy, labor, and postpartum period: Immune system, vertical transmission, and breastfeeding. Front Glob Womens Health 2021;2:602572.
4. Huntley BJ, Huntley ES, Mascio DD, Chen T, Berghella V, Chauhan SP. Rates of maternal and perinatal mortality and vertical transmission in pregnancies complicated by severe acute respiratory syndrome coronavirus 2 (SARS-Co-V-2) infection: A systematic review. Obstet Gynecol 2020;136:303-12.
5. Fan E, Sorbo LD, Goligher EC, Hodgson CL, Munshi L, Walkey AJ, *et al*. An official American thoracic society European society of intensive care medicine/society of critical care medicine clinical practice guideline: Mechanical ventilation in adult patients with acute respiratory distress syndrome. Am J Respir Crit Care Med 2017;195:1253-63.
6. Jering, KS, Claggett BL, Cunningham JW, Rosenthal SD, Vardeny O, Greene MF, *et al*. Clinical characteristics and outcomes of hospitalized women giving birth with and without COVID-19. JAMA Intern Med 2021;181:714-7.
7. Shaikh N, Tharayil AM, Chanda AH, Ganaw A, Riaz MS, Hubertus S, *et al*. Acute respiratory distress syndrome in pregnancy and peripartum: Facts and figures. Ind J Respir Care 2020;9:12-9.
8. Hung C, Hu H, Chang C, Huang CC, Kao KC. Outcomes of early delivery in pregnant patients with acute respiratory distress syndrome. Crit Care 2012;16:P112.
9. Halscott T, Vaught J. SMFM COVID-19 Task Force. Society for Maternal-fetal Medicine: Management Considerations for Pregnant Patients with COVID-19. Society for Maternal-fetal Medicine; 2022.
10. Stephens AJ, Barton JR, Bentum NA, Blackwell SC, Sibai BM. General guidelines in the management of an obstetrical patient on the labor and delivery unit during the COVID-19 pandemic. Am J Perinatol 2020;37:829-36.
11. Schnettler WT, Ahwel YA, Suhag A. Severe ARDS in COVID-19-infected

pregnancy: Obstetric and intensive care considerations. Am J Obstet Gynecol MFM 2020;2:100120.
12. Tomlinson MW, Caruthers TJ, Whitty TJ, Gonik B. Does delivery improve maternal condition in the respiratory-compromised gravida? Obstet Gynecol 1998;91:108-11.
13. McLaren RA Jr., London V, Atallah F, McCalla S, Haberman S, Fisher N, *et al*. Delivery for respiratory compromise among pregnant women with COVID-19. Am J Obstet Gynecol 2020;223:451-3.

Funding: None; Conflicts of Interest: None Stated.

How to cite this article: Handyal H, Gouni GK, Reddy AG, Suchithra J. Pregnancy with COVID-19-related severe ARDS: A case report from rural critical care unit in India. Indian J Case Reports. 2022;8(7):228-231.