

## A case of significant weight loss and severe malnutrition caused by achalasia

Reeju Maharjan<sup>1,2</sup>, Abhinav Sinha<sup>2</sup>

From <sup>1</sup>Post-Medical Graduate, Department of Internal Medicine, V. N. Karazin Kharkiv National University, Kharkiv, Ukraine, <sup>2</sup>Post-Medical Graduate and Chief of Internal Medicine, Department of Internal Medicine, North Vista Hospital, North Las Vegas, Nevada

### ABSTRACT

Achalasia is caused by chronic degeneration of ganglionic cells in the myenteric plexus that leads to failure of relaxation of the lower esophageal sphincter (LES). This leads to aperistalsis of the distal esophagus and eventually led to dilation of the lower esophagus. We present the case of a 37-year-old man who initially presented with dysphagia for solid food and then slowly developed dysphagia for liquid over the past 6 months. He had significant weight loss, and his esophagogastroduodenoscopy (EGD) showed esophagitis and gastritis. The imaging of computed tomography (CT) with oral contrast showed dilation of the distal esophagus and mild circumferential thickening at the gastroesophageal junction. After the failure of response to BoTox-infiltration in the LES, the patient was taken for Heller's myotomy. He showed immediate improvement in dysphagia after surgical intervention. This case study includes findings from CT scan, X-ray, and EGD with biopsies in this patient. This paper also summarizes the therapeutic options of BoTox-injection and surgical myotomy.

**Key words:** Achalasia, Esophagogastroduodenoscopy, Malnutrition, Weight loss

The word achalasia comes from the Greek word a-khalasis, which means "lack of relaxation." Achalasia is a dysphagia-causing neurodegenerative condition characterized by impaired esophageal motor function and a lack of lower esophageal sphincter (LES) relaxation. Achalasia is a relatively uncommon condition, with an annual incidence of 0.03–1.63/100,000 people and a prevalence of 10/100,000 [1]. Achalasia's specific pathophysiology is unknown at this time. Nonetheless, the study findings suggest that a viral infection triggers an autoimmune response, which then triggers a damaging inflammatory cascade that results in the loss of nitric oxide-releasing neurons in the myenteric plexus [2]. Dysphagia, chest discomfort, vomiting, and weight loss are the most common symptoms [3]. Dysphagia is a warning sign that necessitates an esophagogastroduodenoscopy (EGD) as a first-line diagnostic tool to rule out structural or mucosal abnormalities in the esophagus or stomach cardia [4]. The most accurate investigative approach when endoscopic and radiologic modalities fail to diagnose upper gastrointestinal symptoms such as dysphagia is high-resolution manometry [5].

The purpose of this case report is to understand the etiology, pathophysiology, diagnosis, and treatment modalities of achalasia.

### CASE REPORT


A 37-year-old man with no significant medical history presents with 9 months of progressive weight loss associated with intractable vomiting and difficulty swallowing. Vomiting usually occurs after meals with dysphagia, which has been progressively worsening for 2 months. He is unable to keep food down, and his vomitus contains undigested food particles. He admits to losing 42 pounds in the past 6 months. He is also experiencing a progressive increase in weakness and fatigability. He has had bouts of intermittent coughing and a sore throat, but he denies having a fever or chills. He denies abdominal pain, chills, cough, diarrhea, fever, and headaches. He denies any abdominal pain, chest pain, shortness of breath, cough, fever, chills, or rectal bleeding. He does not have any significant family history. There was no history of tobacco and alcohol intake or substance abuse.

The patient was alert and oriented. He was nontoxic in appearance but looked fatigued. Eye, head, and nose examinations were normal. However, his mucous membrane was dry. His oropharynx was clear. He was tachycardic with normal heart sounds. His lungs had decreased breath sounds in the base with no wheezing or respiratory distress. His abdomen was soft and non-tender and he had bowel sounds. The examination of other organs was normal.

The chemistry test result showed hypokalemia and an increased chloride level. The electrolytes were Na-154 mmol/L, K-3.2 mmol/L, and Cl-113 mmol/L. His laboratory investigations

**Correspondence to:** Reeju Maharjan, V. N. Karazin Kharkiv National University, Kharkiv, Ukraine. E-mail: dr.reeju1@gmail.com

© 2022 Creative Commons Attribution-NonCommercial 4.0 International License (CC BY-NC-ND 4.0).

Access this article online	
Received - 18 June 2022 Initial Review - 20 June 2022 Accepted - 14 July 2022	Quick Response code 
DOI: 10.32677/ijcr.v8i7.3522	

showed acute kidney injury with blood urea nitrogen 90 mg/dl and creatinine (2.7 mg/dl). Within the 8-month period, body mass index (BMI) dropped from 26.23 kg/m<sup>2</sup> to 16.13 Kg/m<sup>2</sup>. His albumin showed a consistent downward trend, with the lowest being 2.7. The low albumin and BMI point toward malnutrition. His hemogram revealed decreased hemoglobin – 11.4 g/dl, mean corpuscular hemoglobin (MCH) – 26.7 pg, and red blood cell distribution width was 15.9%. Platelets and white blood cells were normal. Urinalysis showed a hyaline cast.

The patient chest X-ray was unremarkable. Compared to a 7-month prior study, the computed tomography (CT) impression of his soft tissue with contrast showed increased dilatation of the proximal esophagus with debris (Fig. 1). His CT chest with contrast also revealed diffuse esophageal dilatation with fluid and debris in the esophageal wall thickening. There was wall thickening at the gastroesophageal junction and gastric wall thickening. After these findings, EGD was done. The findings of EGD showed a dilated esophagus with esophagitis and a tight lower LES suggestive of achalasia. Antral and esophageal biopsies were taken during EGD, which showed chronic inactive gastritis and moderate acute esophagitis. Negative EGD biopsy from antrum for *Helicobacter pylori* and intestinal metaplasia.

This patient was initially treated with pantoprazole for esophagitis which was not beneficial. One hundred International Unit (IU) botox were injected in LES after failed medical intervention, but he states that it worked for 2–3 days and symptoms returned. As the patient was a good surgical candidate, he was presented with the option of Laparoscopic Heller's myotomy. It was performed by dividing longitudinal circular layers. He immediately felt improvement in his swallowing. He was discharged 2 days later with a drain and was advised to follow-up 2 weeks later.

The patient returns to the emergency department after 2 weeks for a Jackson-Pratt drain to be removed. The drain was dry for 4 days. The patient had significant improvement in swallowing. He was recommended for follow-up in the office for the wound.

## DISCUSSION

The most prevalent symptoms of achalasia are dysphagia and regurgitation. At first, dysphagia may be noted only for solids,

but 70–97% of patients with achalasia have dysphagia for both liquids and solids at the time of diagnosis. In roughly 75% of these patients, regurgitation of undigested and retained food occurs. Due to impaired esophageal emptying and reduced or modified food intake, about 60% of achalasia patients may have some weight loss at presentation [6].

The primary aim of the EGD procedure is to rule out esophageal cancer or the development of premalignant or malignant lesions as a result of prolonged stasis [7]. Achalasia is a significant risk factor for esophageal cancer, with an incidence of up to 9% of cancer developing in achalasia patients, which is 10–50 times greater than the general population [8]. A barium swallow is necessary to determine the esophageal morphology (diameter and axis) as well as accompanying diseases such as epiphrenic diverticula or malignancy. Distal esophageal tapering in a “bird's beak” form with proximal esophageal dilatation, occasionally with an air-fluid level, and absence of intragastric air are classic findings. Severe dilatation with food stasis and a sigmoid-like appearance can occur in more advanced cases [9]. Esophageal manometry determines the disease's diagnosis with a high degree of certainty, even in the early stages of the disease. The failure of the lower LES to relax during swallowing and aperistalsis characterizes the manometric image of achalasia [10]. Around 70–80% of patients will have absent or partial LES relaxation, while the remaining patients will have a nadir pressure within acceptable ranges but with short-duration relaxation (6s) [6] had high amplitude concurrent waves.

A typical treatment botox regimen involves injecting 100 units of reconstituted Botox into the LES in four quadrants, divided into four aliquots. Botox is a safe, reasonably successful (80% early dysphagia alleviation) and less intrusive treatment, but it has two key limitations that keep it from becoming a first-line treatment [11]. The first is that it is only effective for a short period of time. Despite positive early outcomes, the effect fades over time, with 60% of patients experiencing recurrent dysphagia after a year and 80% after 2 years. Intramuscular Botox injections create submucosal fibrosis, which makes definitive therapies more difficult [12]. A five-laparoscopic port approach is used, with mobilization of at least the anterior 180° of the gastroesophageal junction and distal esophagus (360° if a Toupet is planned), followed by fundoplication. A prospective study by Oelschlager *et al.* challenged the usual 2-cm extension of the myotomy onto the anterior stomach wall, finding that a 3-cm extension resulted in superior outcomes [13]. Richards *et al.* from Vanderbilt University verified the requirement for a partial fundoplication to be added to the myotomy to reduce the risk of iatrogenic gastroesophageal reflux disease (GERD) [14].

## CONCLUSION

The etiology of achalasia is not known yet. The patient's chief complaint remains dysphagia and weight loss. The diagnosis was made without manometry. There are other procedures such as pneumatic dilation and per-oral endoscopic myotomy but laparoscopic Heller's myotomy remains the standard management

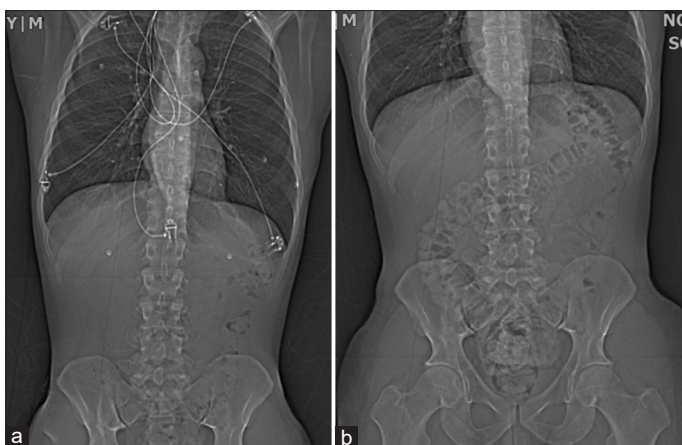


Figure 1: Computed tomography abdomen (a) without contrast and (b) with oral contrast

plan followed by a partial fundoplication to the myotomy to minimize the incidence of iatrogenic GERD.

## REFERENCES

- Mari A, Baker FA, Pellicano R, Khoury T. Diagnosis and management of achalasia: Updates of the last two years. *J Clin Med* 2021;10:3607.
- Gockel I, Becker J, Wouters MM, Niebisch S, Gockel HR, Hess T, *et al.* Common variants in the HLA-DQ region confer susceptibility to idiopathic achalasia. *Nat Genet* 2014;46:901-4.
- Dumic I, Nordin T, Jecmenica M, Lalosevic MS, Milosavljevic T, Milovanovic T. Gastrointestinal tract disorders in older age. *Can J Gastroenterol Hepatol* 2019;2019:6757524.
- Mari A, Patel K, Mahamid M, Khoury T, Pesce M. Achalasia: Insights into diagnostic and therapeutic advances for an ancient disease. *Rambam Maimonides Med J* 2019;10:e0008.
- Mari A, Sweis R. Assessment and management of dysphagia and achalasia. *Clin Med (Lond)* 2021;21:119-23.
- Vaezi MF, Richter JE. Diagnosis and management of achalasia. American college of gastroenterology practice parameter committee. *AM J Gastroenterol* 1999;94:3406-12.
- Van Dam J, Falk GW, Sivak MV, Achkar E, Rice TW. Endosonographic evaluation of the patient with achalasia: Appearance of the esophagus using the echoendoscope. *Endoscopy* 1995;27:185-90.
- Herbella FA, Oliveira DR, Del Grande JC. Are idiopathic and chagasic achalasia two different diseases? *Dig Dis Sci* 2004;49:353-60.
- Moonen A, Boeckxstaens G. Current diagnosis and management of achalasia. *J Clin Gastroenterol* 2014;48:484-90.
- Patti MG, Herbella FA. Achalasia and other esophageal motility disorders. *J Gastrointest Surg* 2011;15:703-7.
- Zaninotto G, Vergadoro V, Annese V, Costantini M, Costantino M, Molena D, *et al.* Botulinum toxin injection versus laparoscopic myotomy for the treatment of esophageal achalasia: Economic analysis of a randomized trial. *Surg Endosc* 2004;18:691-5.
- Horgan S, Hudda K, Eubanks T, McAllister J, Pellegrini CA. Does botulinum toxin injection make esophagomyotomy a more difficult operation? *Surg Endosc* 1999;13:576-9.
- Oelschlagel BK, Chang L, Pellegrini CA. Improved outcome after extended gastric myotomy for achalasia. *Arch Surg* 2003;138:490-5.
- Richards WO, Torquati A, Holzman MD, Khaitan L, Byrne D, Lutfi R, *et al.* Heller myotomy versus Heller myotomy with dor fundoplication for achalasia: A prospective randomized double-blind clinical trial. *Ann Surg* 2004;240:405-12.

*Funding: None; Conflicts of Interest: None Stated.*

**How to cite this article:** Maharjan R, Sinha A. A case of significant weight loss and severe malnutrition caused by achalasia. *Indian J Case Reports*. 2022;8(7):225-227.