

A perplexing case report of an imaging negative acute ischemic stroke

D Chandrashekar¹, Divij Sharma², Mehul Desai³, Nirmal Surya⁴

From ¹Resident, ²Resident, ³Clinical Associate, ⁴Associate Professor and President, Department of Neurology, Bombay Hospital and Medical Research, Mumbai, Maharashtra, India

ABSTRACT

Magnetic resonance imaging (MRI) is often seen as the gold standard when dealing with an acute ischemic stroke. Despite its unique ability to quickly diagnose acute stroke with diffusion-weighted imaging, there is enough evidence to suggest that MRI has failed to diagnose acute ischemic stroke in a minority of patients. We, hereby, present a case of a 55-year-old gentleman who presented with symptoms consistent with an acute ischemic event, but concurrent computed tomography and MRI were normal. However, the treatment regime for stroke was commenced despite normal imaging. It was only on the 3rd day of admission when the MRI revealed a significant finding which consolidated our diagnosis of ischemic stroke. Through this case report, we aim to help clinicians avoid misdiagnosis or delay in the treatment strategies, especially intravenous thrombolysis in patients with a clinical diagnosis of acute stroke with normal neuroradiological imaging. This is a testament to the fact that clinical assessment still retains priority until a diagnostic tool offers 100% sensitivity and specificity.

Key words: Magnetic resource angiography, Perfusion-weighted image, Stroke, Transient ischemic attack

Ischemic stroke is one of the major causes of death and disability. An array of efforts has been made to improve the outcome of acute ischemic stroke diagnosis and management [1]. Magnetic resonance angiography (MRA) is crucial for diagnosing ischemic stroke and for determining treatment modalities, especially when the patient presents within the window period [2,3]. Despite yielding favorable outcomes in the majority of cases, practical issues exist limiting the use of basic MRA in the acute stage of ischemic stroke. In the early stage, prompt diagnosis of ischemic stroke and its differentiation from stroke-mimics is important to identify patients eligible for revascularization therapy rapidly and accurately [4,5]. In present clinical practice, time is dominant over pathophysiology on imaging for decisions related to implementing therapy.

Here, we report an interesting case of a 55-year-old gentleman with acute hemiparesis whose initial magnetic resonance imaging (MRI) within 24 h did not reveal any abnormalities, only for a subsequent MRI to reveal unilateral thalami infarct on follow-up imaging. However, this clinic-radiological mismatch did not affect our clinical judgment and the patient was treated without any delay for an acute ischemic event.

CASE REPORT


A 55-year-old gentleman with no comorbidities presented at our hospital with a history of lightheadedness, discomfort, and unsteady gait lasting for >30 min which resolved on its own at home. A day later (day 2), he developed a pins and needles sensation on the entire right side of the face accompanied by heaviness and tingling felt in the right upper and lower limbs which rendered him incapable to lift his limbs with ease and to be bedridden. Following this episode, he sought admission to our hospital. Family members had noticed slight imbalance and swaying on both sides while walking for the past 2 days. He was a non-smoker and an occasional drinker.

However, there was no history of headache, photophobia, nausea, vomiting, altered sensorium, vision issues, drooping of eyelids, swallowing difficulty, or bowel bladder incontinence. There was no history of Lhermitte's symptoms or the Uhthoff phenomenon. There was no significant past trauma history, medical history, or travel history. The patient's vitals were within normal limits with blood pressure between 130 and 80 mm Hg.

On neurological examination, the patient was, conscious, oriented, the speech was normal, and the pupils were reacting with no restriction of extraocular movements. We elicited a pronator drift of the right upper limb. Cranial nerve examination revealed moderate lower motor neuron seventh nerve deficit on

Correspondence to: Dr. Nirmal Surya, Department of Neurology, Bombay Hospital and Medical Research, Indian Academy of Neurology, Mumbai, Maharashtra, India. E-mail: nirmal_surya@yahoo.com

© 2022 Creative Commons Attribution-NonCommercial 4.0 International License (CC BY-NC-ND 4.0).

Access this article online	
Received - 22 March 2022 Initial Review - 09 April 2022 Accepted - 18 April 2022	Quick Response code 
DOI: 10.32677/ijcr.v8i4.3399	

the right side. Muscle tone and bulk were tested normal. Power was 2/5 on the right upper and lower limbs and 5/5 on the left limbs. The National Institutes of Health Stroke Scale at the time of admission was 12.

Deep tendon reflexes were brisk in both upper and lower limbs, plantar extensor bilaterally, the sensory system revealed reduced vibration and proprioception on the right lower limbs, extrapyramidal system, and peripheral nerves were normal. There were no signs of meningeal irritation, and no involuntary movements; ataxia was only evident on tandem gait with subtle swaying on heel shin testing. With a differential diagnosis of stroke in mind, a computed tomography (CT) was done which was normal. MRA was unremarkable (Fig. 1).

Laboratory tests revealed high low-density lipoprotein level and an elevated homocysteine level of 28.2 (4–15 $\mu\text{mol/L}$). The complete blood work including lipid profile and cardiac markers was normal and so was the 24-h Holter. With normal imaging, our index of suspicion shifted toward conversion disorder, MRI negative multiple sclerosis (MS), and hemiplegic migraine, but there was no identifiable stressor or relevant medical or psychiatric history on interviewing the patient again.

Given this mismatch between clinical and radiological findings and based on acute clinical symptomatology, we started the patient on low molecular weight heparin, aspirin, statin therapy, multivitamin injections, and Inj. Citicoline on day 1 of admission in line with the presumptive diagnosis of a resolving Transient Ischemic Attack (TIA). The plan for thrombolysis therapy was shunned as the patient presented outside the required time window. Physiotherapy and speech therapy were initiated. On day 3, a repeat MRA was done which showed a diffusion-weighted image (DWI) showing evidence of restricted diffusion in the left thalamus and adjacent posterior limb of the internal capsule with corresponding T2/FLAIR hyperintensity (Fig. 2). The treatment modality remained the same. From day 4, the patient showed dramatic improvement. Facial weakness had ebbed and demonstrated improvement in limbs with the return of power to 3/5 on the right side and the ability to mobilize to the edge of the bed by self.

Following the same regime of the treatment, the patient's clumsiness and heaviness of hands resolved completely and power improved to 4/5 on the right limbs soon, after which he was able to walk with support and clutches. He was discharged with the NIHSS score of 5 on day 9 on oral anti-platelets,

statins, multivitamin tablets, and home-based physiotherapy and rehabilitation.

DISCUSSION

As per 2019 data from Lancet, there were 12.2 million (95% UI 11.0–13.6) incident strokes and 101 million (93.2–111) prevalent strokes, and 6.55 million (6.00–7.02) deaths from stroke. Globally, stroke was the second-leading cause of death after ischemic heart disease [6].

The diagnosis of stroke largely depends on clinical presentation. Conditions mimicking stroke account for 19–30% of suspected stroke presentations, with diverse underlying causes [7]. Physicians need to consider a broad differential diagnosis such as syncope, primary headache disorder, functionally or medically unexplained disorder, metabolic cause, peripheral vestibular disorder, dementia, or confusional state, and drug abuse when evaluating a patient presenting with a focal neurological deficit.

In accordance with our case who was being treated for TIA, there have been cases of patients stricken with TIA with a normal MRA finding and without significant arterial abnormality. Hence, to address this, there is a need to do perfusion-weighted imaging (PWI) in addition to the DWI which will reveal the only objective indication of ischemic etiology. In various studies, perfusion abnormalities have been found in between 3% and 25% of TIA patients who have no DWI abnormality [8–10]. There is emerging evidence that DWI fails to identify acute ischemic stroke in a substantial minority of patients. The 2010 American Academy of Nursing guidelines for physicians reported that “the sensitivity of DWI for the diagnosis of ischemic stroke in a general sample of patients with possible acute stroke is not perfect” [11].

Moreover, PWI which includes gadolinium-based techniques and arterial-spin-labeled technique can identify ischemic penumbral tissue which is the surrounding part of core infarction that still exhibits minimal blood flow supplied by collateral circulation when the neuronal function has been suspended [12]. Therefore, there is an utmost need for multimodal MRI encompassing PWI that can provide prudent information for accurate diagnosis of stroke evaluation which can, in turn, help us evaluate the risks and benefits of thrombolysis and predict post-stroke outcomes.

In our patient, the early stage of MS was also being considered although for a brief period, as there has been documented literature

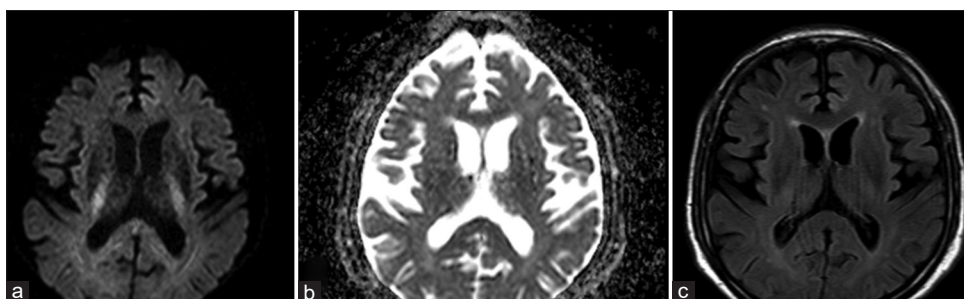


Figure 1: Diffusion-weighted image, apparent diffusion coefficient, and T2/fluid-attenuated inversion recovery imaging showing normal magnetic resonance imaging

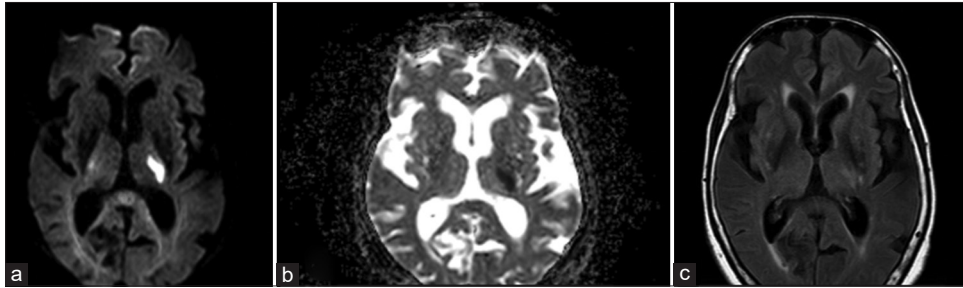


Figure 2: (a) Diffusion-weighted image revealing area of restricted diffusion on the left thalamus region; (b) Corresponding apparent diffusion coefficient (ADC) image revealing hypointensity on the left thalamus region suggestive of ADC drop; (c) Axial T2/fluid-attenuated inversion recovery imaging image showing area of hyperintensity in the left thalamus and adjacent posterior limb of internal capsule

on frequent false-negative and normal MRI findings reports in patients with the early MS and these patients with normal MRI findings developed lesions detectable on MRI scans when the disease became established [13]. Our case serves as a reminder that clinical assessment still retains priority until a diagnostic modality offering 100% sensitivity and specificity is discovered. A limitation of this case was that no subsequent imaging follow-up of this patient was done to discern the resolution of this infarct after an appropriate treatment modality was in place.

CONCLUSION

Considering clinical presentation consistent with an acute ischemic event, a crucial point to address is to perform follow-up MRI images which may be more demonstrative for establishing a clear diagnosis and management. In addition to this, there is an imperative need to consider the application of PWI MRI in tertiary care hospital settings to improve outcomes and address treatment dilemmas in cases of strokes and TIA. It is also essential that clinicians not exclusively depend on neuroimaging and instead comprehensively combine the clinical information available in terms of history and examination in taking clinical decisions for the treatment of patients with established or evolving stroke. This way, a patient will not be deprived of a potentially lifesaving admission and management for an acute ischemic event.

REFERENCES

1. The National Institute of Neurological Disorders and Stroke rt-PA Stroke Study Group. Tissue plasminogen activator for acute ischemic stroke. *N Engl J Med* 1995;333:1581-7.
2. Baird AE, Warach S. Magnetic resonance imaging of acute stroke. *J Cereb Blood Flow Metab* 1998;18:583-609.
3. Campbell BC, Tu HT, Christensen S, Desmond PM, Levi CR, Bladin CF, *et al.* Assessing response to stroke thrombolysis: Validation of 24-hour multimodal magnetic resonance imaging. *Arch Neurol* 2012;69:46-50.
4. Lovblad KO, Laubach HJ, Baird AE, Curtin F, Schlaug G, Edelman RR, *et al.* Clinical experience with diffusion-weighted MR in patients with acute stroke. *Am J Neuroradiol* 1998;19:1061-6.
5. Chalela JA, Kang DW, Luby M, Ezzeddine M, Latour LL, Todd JW, *et al.* Early magnetic resonance imaging findings in patients receiving tissue plasminogen activator predict outcome: Insights into the pathophysiology of acute stroke in the thrombolysis era. *Ann Neurol* 2004;55:105-12.
6. Feigin V, Stark B, Johnson C, Roth G, Bisignano C, Abady G, *et al.* Global, regional, and national burden of stroke and its risk factors, 1990-2019: A systematic analysis for the global burden of disease study 2019. *Lancet Neurol* 2021;20:795-820.
7. Gibson LM, Whiteley W. The differential diagnosis of suspected stroke: A systematic review. *J R Coll Physicians Edinb* 2013;43:114-8.
8. Restrepo L, Jacobs MA, Barker PB, Wityk RJ. Assessment of transient ischemic attack with diffusion and perfusion-weighted imaging. *AJNR Am J Neuroradiol* 2004;25:1645-52.
9. Krol AL, Coutts SB, Simon JE, Hill MD, Sohn CH, Demchuk AM, *et al.* Perfusion MRI abnormalities in speech or motor transient ischemic attack patients. *Stroke* 2005;36:2487-9.
10. Mlynash M, Olivot JM, Tong DC, Lansberg MG, Eyngorn I, Kemp S, *et al.* Yield of combined perfusion and diffusion MR imaging in hemispheric TIA. *Neurology* 2009;72:1127-33.
11. Lefkowitz D, LaBenz M, Nudo SR, Steg RE, Bertoni JM. Hyperacute ischemic stroke missed by diffusion-weighted imaging. *AJNR Am J Neuroradiol* 1999;20:1871-5.
12. Banerjee RK, Back LH, Back MR, Cho YI. Physiological flow analysis in significant human coronary artery stenoses. *Biorheology* 2003;40:451-76.
13. O'Riordan JI, Thompson AJ, Kingsley DP. The prognostic value of brain MRI in clinically isolated syndromes of the CNS. A 10-year follow-up. *Brain* 1998;121 Pt 3:495-503.

Funding: None; Conflicts of Interest: None Stated.

How to cite this article: Chandrashekar D, Sharma D, Desai M, Surya N. A perplexing case report of an imaging negative acute ischemic stroke. *Indian J Case Reports*. 2022;8(4):115-117.