

A rare case report of strangulated spigelian hernia mimicking an abdominal mass

Geeta Sundar¹, Sunil Kumar Shetty²

From ¹Junior Resident, ²Professor and Head of Unit, General Surgery, Kasturba Medical College, Mangaluru, Karnataka, India

ABSTRACT

A Spigelian hernia, an infrequent occurrence, is an abdominal wall hernia that occurs through the Spigelian fascia, an aponeurotic sheet located medially by rectus muscles and laterally by the semilunar line. The hernial sac lies either deep to the internal oblique muscles or between the oblique muscles. A Spigelian hernia requires repair due to the risk of incarceration with its relatively narrow neck. The below case report provided shows a 67-year-old female patient, who came with an abdominal mass that was diagnosed as a strangulated Spigelian hernia and managed with emergency surgery.

Key words: Abdominal wall, Hernia, Hernia, Laparotomy, Spigelian, Surgery

Spigelian hernia, also referred to as lateral abdominal hernia, represents the projection of, peritoneal sac, preperitoneal fat, or organs through a congenital or acquired deficiency in the Spigelian fascia that lies along the semilunar line [1,2]. Spigelian hernia is considered to occur in <1% of all hernias and is frequently intraparietal, with the sac discovered posterior to the external oblique aponeurosis. They tend to occur in the later part of life and are usually asymptomatic, or with vague abdominal symptoms, which if left untreated, can cause incarceration, strangulation, or bowel perforation [1]. Pain abdomen is the prominent finding, but the clinical diagnosis of Spigelian hernia is difficult as many do not present with a hernia but a vague abdominal mass or pain over the Spigelian fascia [2,3]. Contrast-enhanced computed tomography (CECT) and ultrasonography (USG) of the abdomen are tools used for diagnosis with the CECT helping in confirming the diagnosis and also describing the hernia's topography [3]. The mainstay of treatment is prompt surgical management and repair involves either an open approach or laparoscopic technique with the use of mesh if the defect is large, to decrease the risk of recurrence [4].

Our case report involves a 67-year-old elderly woman from Mangalore, India, who presented with an abdominal mass that was diagnosed as strangulated Spigelian hernia. The hernia sac was reduced, the bowel was resected, and the defect was repaired.

CASE REPORT

A 67-year-old female patient, hypertensive (since 3 years) and diabetic (since 2 years) on oral medications, presented with a swelling in the left lower abdomen for 8 days that occurred spontaneously and had no progression in size.


On general examination, the patient appeared toxic, dehydrated, with a heart rate of 110 bpm, blood pressure of 100/60 mm Hg, SpO₂ 98% on room air, and respiratory rate of 20 cpm. She had associated nausea and vomiting for an equal duration. There was no history of the previous abdominal surgeries. On abdominal examination, a single, near-midline, almost spherical 8 × 6 cm, hard, non-tender, and irreducible swelling was present in the left iliac fossa, seemingly arising from the abdominal valve, with restricted mobility, associated with local erythema, and absent bowel sounds. Cough impulse was negative (Fig. 1a). Given the above clinical findings, differential diagnoses of a desmoid tumor, an unexpected hematoma, and a strangulated hernia were considered.

USG abdomen done revealed an abdominal wall defect of around 16 mm with a hernia sac containing omentum and bowel and no uptake of color on Doppler, features suggestive of strangulated hernia.

As the patient was in a toxic dehydrated state with intestinal obstruction/obstipation and the fact that the patient was managed conservatively and referred to our hospital for further care, a decision was taken to post the patient for an emergency laparotomy once consent was taken. Intraoperatively, an elliptical incision was placed around the hernia (Fig. 1b). The hernial sac was dissected

Correspondence to: Dr. Geeta Sundar, Junior Resident, Professor and Head of Unit, General Surgery, Kasturba Medical College, Mangaluru, Karnataka, India. E-mail: harry_geeta@yahoo.co.in

© 2022 Creative Commons Attribution-NonCommercial 4.0 International License (CC BY-NC-ND 4.0).

Access this article online	
Received - 08 February 2022 Initial Review - 18 February 2022 Accepted - 12 March 2022	Quick Response code 
DOI: 10.32677/ijcr.v8i3.3314	

all around and opened. Strangulated omentum with gangrenous small bowel was noted (Fig. 2a). A partial omentectomy was done. Gangrenous bowel was resected and anastomosed in a primary closure in a double layered fashion and the contents were reduced through the defect (Fig. 2b and c). Mesh repair was not carried out due to the possibility of bacterial translocation in the underlying setting of bowel gangrene warranting resection. The peritoneal defect and rectus closed and a subcutaneous suction drain was placed.

The post-operative period was uneventful. Blood pressure and sugars were in normal limits with medications. On follow-up at 3 months, the patient was fit, had no recurrence and the incision had healed well.

DISCUSSION

The name Spigelian is given after Adrian van der Spiegel, a Belgian, who first demonstrated the anatomy of the semilunar line in the 1700's [1]. Spigelian hernia is a hernia that arises through the Spigelian aponeurosis, which is created by the fusion of the transversus abdominis and internal oblique muscles and whose borders are composed of the semilunar line and the rectus muscle. Its expanse is from the eighth rib to the pubic symphysis. Above the umbilicus, it's reinforced by the rectus muscle, whereas, infraumbilically, it is weak and amenable to the protrusion of peritoneal contents. Many of the Spigelian hernia develops in the "Spigelian hernia belt," an area positioned 6 cm below the umbilicus and arcuate line - possibly due to the deficiency of the posterior rectus fascia; and superior to the inferior epigastric vessels [5].

Spigelian hernia, a unique occurrence, however under-reported has an estimated incidence ranging from 0.1% to 2% of all ventral hernias [4,5]. Spigelian hernia could be acquired

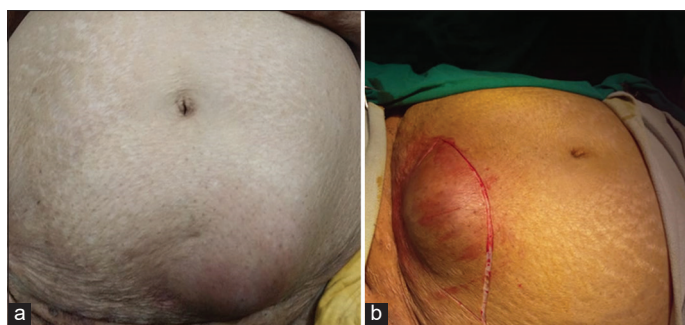


Figure 1: (a) Depicts mass per abdomen, (b) depicts the elliptical abdominal incision

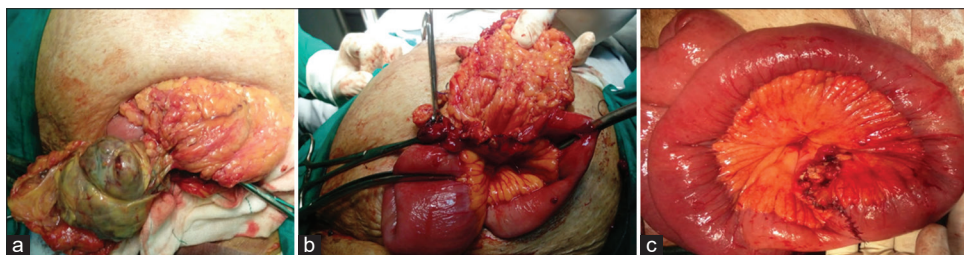


Figure 2: (a) Depicts the presence of gangrenous bowel, (b) after resection of the gangrenous bowel, (c) depicts the primary anastomosis

or congenital, generally emerging in the fifth decade, and found to be more frequent in women [4]. The risk factors for Spigelian hernia include causes with increased intra-abdominal pressure, increasing age, obesity, multiparity, chronic lung diseases, previous abdominal operations, connective tissue disorders, iatrogenic reasons, rapid weight reduction, and congenital causes [5].

The typical symptom of Spigelian hernia is pain abdomen and in up to 35% of cases, the mass abdomen is regularly encountered. These hernias have a narrow neck and hence very likely to incarcerate, strangulate or cause obstruction and perforation if immediate surgical intervention is not taken [5]. The contents of the hernia can encompass intestine, colon, stomach, pelvic organs, appendix, ovary, testis, and endometrial tissue; however, the greater omentum is by far the most common one, but a loop of small bowel is the most commonly expected organ found in these hernias. Very infrequently, these can be bilateral, contain Meckel's Diverticulum, or be Richter's type in nature [6]. In our case also, as described above, the Strangulated hernia contained omentum with gangrenous small bowel intraoperatively. This concurs with what is commonly mentioned in the literature.

Spigelian hernia simulates many other conditions of the abdominal wall such as rectus sheath abscess, hematoma, or seroma, and only half the cases can be diagnosed preoperatively. It is for that reason; a need for radiographic evidence is paramount. Abdominal radiography only shows specific stark features of obstruction [6]. USG of the abdomen is advocated as the cardinal basic imaging in suspected cases. CECT of the abdomen and pelvis is the best dependable investigation and provides information about the contents, abdominal wall layers, bowel obstruction, soft-tissue changes and informs on the location of the defect, the size, and aids in pre-operative planning. In doubtful cases, MRI might be considered for diagnosis [7].

Surgery is the definitive treatment, which can be done through open technique – done traditionally with a transverse incision and primary repair of the defect; or laparoscopically [8]. Laparoscopic approaches are gaining wide acceptance due to smaller incisions, decreased length of hospital stay, however, the open approach is still a favorite since it is more practical in emergency situations with features of strangulation or incarceration and reduces chances of ischemic complications. The placement of mesh is found to be advantageous in lowering recurrence [7,9]. Laparoscopic surgery of Spigelian hernia includes transabdominal pre-peritoneal, total extra-peritoneal (TEP), and intraperitoneal on-lay mesh (IPOM) approaches. Literature shows that IPOM is commonly performed

owing to its easier technique and better visualization. However, a small risk of adhesions exists in IPOM, which can be reduced using an expensive composite mesh with both non-absorbable and absorbable components [8,9]. TEP, on the other hand, has a longer learning curve, more dissection and extra-peritoneal placement of a less expensive simple basic polypropylene mesh, and decreased rates of intraperitoneal adhesions [8]. The mesh can be anchored with sutures, staples, or tacks. A novel method is to use fibrin sealing material to hold the mesh, and is regarded to decrease post-operative complications of pain and nerve injuries [7,9]. Recent studies have demonstrated the use of robotic surgery in Spigelian hernia, where robotic surgery gives an added advantage over the laparoscopic approach in enhanced view and dexterity with 3D imaging, augmented ergonomics and better precision, lowered rate of pain, and improved recovery [10].

CONCLUSION

The study tries to bring to light the fact, that sometimes Spigelian hernia can masquerade as an abdominal mass, and hence increased vigilance toward a strangulated/obstructed hernia can play an important role in its management.

AUTHORS CONTRIBUTIONS

Geeta Sundar and Sunil Kumar Shetty: Concept and design of study or acquisition of data or analysis and interpretation of data, Drafting the article or revising it critically for important

intellectual content, Final approval of the version to be published, Geeta Sundar: Guarantor.

REFERENCES

1. Polistina FA, Garbo G, Trevisan P, Frego M. Twelve years of experience treating Spigelian hernia. *Surgery* 2015;157:547-50.
2. Light D, Chattopadhyay D, Bawa S. Radiological and clinical examination in the diagnosis of Spigelian hernias. *Ann R Coll Surg Engl* 2013;95:98-100.
3. Ferris M, Diegidio P, Loflin C, Nottingham J. Laparoscopic management of the spigelian hernia. *Am Surg* 2014;80:E329-30.
4. Rankin A, Kostusiak M, Sokker A. Spigelian hernia: Case series and review of the literature. *Visc Med* 2019;35:133-6.
5. Perrakis A, Velimezis G, Kapogiannatos G. Spiegel hernia: A single center experience in a rare hernia entity. *Hernia* 2012;16:439-444.
6. Igwe PO, Ibrahim NA. Strangulated sliding spigelian hernia: A case report. *Int J Surg* 2018;53:475-8.
7. Mederos R, Lamas JR, Alvarado J, Matos M, Padron I, Ramos I. Laparoscopic diagnosis and repair of Spigelian hernia: A case report and literature review. *Int J Surg Case Rep* 2017;31:184-7.
8. Law TT, Ng KK, Ng L, Wong KY. Elective laparoscopic totally extraperitoneal repair for Spigelian hernia: A case series of four patients. *Asian J Endosc Surg* 2018;3:1-5.
9. Zaki W, Alawad AA. Spigelian hernia: A rare case report. *Ann Clin Case Rep Surg* 2017;2:1288.
10. Jamshidian M, Stanek S, Sferra J. Robotic repair of symptomatic Spigelian hernias: A series of three cases and surgical technique review. *J Robotic Surg* 2018;12:557-60.

Funding: None; Conflicts of Interest: None Stated.

How to cite this article: Sundar G, Shetty SK. A rare case report of strangulated spigelian hernia mimicking an abdominal mass. *Indian J Case Reports*. 2022; March 19 [Epub ahead of print].