

Air embolism in an infarct: Unveiling the etiology of a new infarct

Meghna Sivji¹, Vidya M V², Thara Pratap², Muhammed Jasim Abdul Jalal³

From ¹Registrar, Department of Internal Medicine, Pushpagiri Institute of Medical Sciences and Research Centre, Thiruvalla, ²Senior Consultant, Department of Neurology, ³Consultant, Internal Medicine and Rheumatology, VPS Lakeshore Hospital, Kochi, Kerala, India

A 57-year-old critically ill (post-renal allograft recipient) female with the right anterior cerebral artery infarct (Fig. 1a-c) had a seizure. On examination, she was hemodynamically stable with a heart rate of 80/min and blood pressure of 140/80 mmHg. The patient was stabilized and an arterial line was put. Computed tomography (CT) brain taken within 30 min of inserting an arterial line revealed multiple hypodense areas with density that of air in the infarcted brain, which was characteristic of cerebral air embolism (Fig. 1d-f). Repeat CT brain taken 48 h later revealed disappearance of those lesions

and there were few scattered areas of new infarcts seen in the left frontoparietal region (Fig. 1g-i). It is difficult to get images of air in CT as air entering the vessels will be rapidly absorbed into the normal tissues. In contrast, air trapped in the dead tissue like an infarcted brain will not be diffusing into the surrounding tissue rapidly and can be detected on CT done up to 48 h later. Arterial air in cerebral circulation will remain in the vascular system for 30 min, whereas, venous air persists up to 7–38 h [1]. She was given supportive care with ventilation and oxygenation. Infections with gas-forming organisms were considered and she

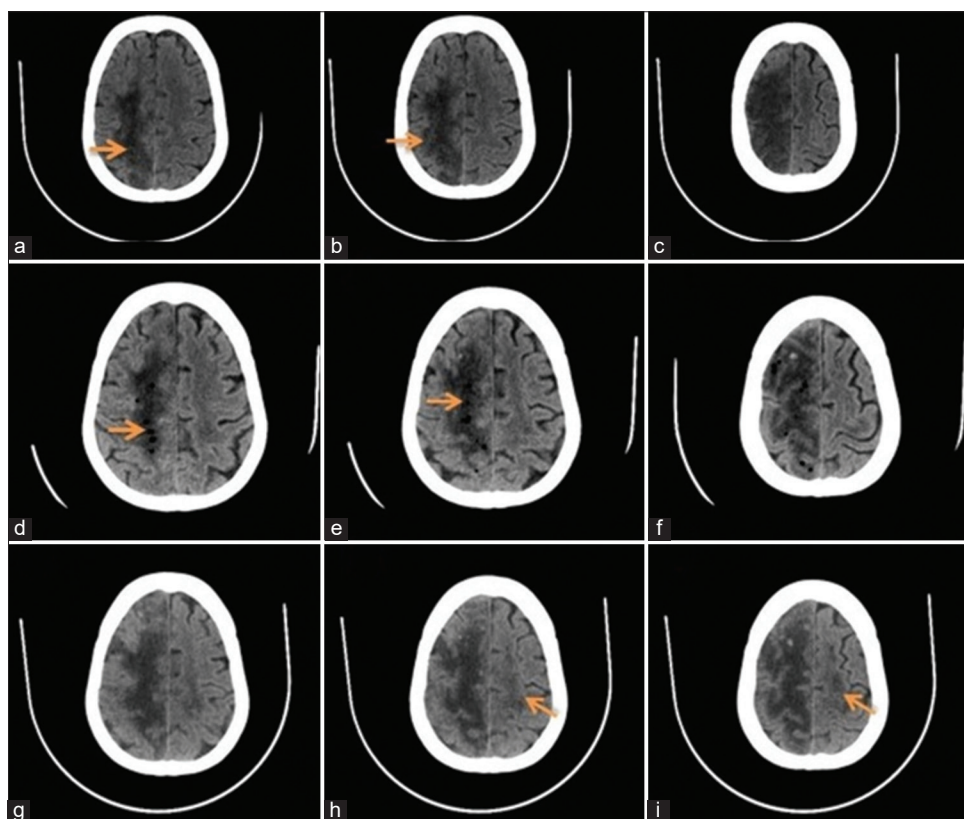


Figure 1: Computed tomography Brain. (a-c) Cerebral images showing the right anterior cerebral artery infarct (orange arrows); (d-f) Cerebral images taken within 30 min of inserting an arterial line showing multiple foci of air (orange arrows) noted within area of infarct and scattered areas of hemorrhage; (g-i) cerebral images taken 48 h later showing total resolution of air. New areas of infarct noted on the left fronto-parietal regions (orange arrows)

Access this article online

Received - 06 February 2022
Initial Review - 17 February 2022
Accepted - 03 March 2022

DOI: 10.32677/ijcr.v8i3.3313

Quick Response code



Correspondence to: Muhammed Jasim Abdul Jalal, Department of Internal Medicine and Rheumatology; VPS Lakeshore Hospital, Nettor. P. O, Kochi, Kerala, 682 040, India. E-mail: jasimabduljalal@yahoo.com

© 2022 Creative Commons Attribution-NonCommercial 4.0 International License (CC BY-NC-ND 4.0).

was started on prophylactic antibiotics which were stopped once CT revealed resolution of air embolism.

REFERENCE

1. Chuang DY, Sundararajan S, Sundararajan VA, Feldman DI, Xiong W. Accidental air embolism: An uncommon cause of iatrogenic stroke. *Stroke* 2019;50:e183-6.

Funding: None; Conflicts of Interest: None Stated.

How to cite this article: Sivji M, Vidya MV, Pratap T, Jalal MJ. Air embolism in an infarct: Unveiling the etiology of a new infarct. *Indian J Case Reports*. 2022; March 10 [Epub ahead of print].