Letter to Editor

Pathological laughter in a patient with recent stroke: An interesting cause

Meghna Sivji[1], M V Vidya[2], Thara Pratap[3], Muhammed Jasim Abdul Jalal[4]

From [1]Registrar, Department of Internal Medicine, Pushpagiri Institute of Medical Sciences and Research Centre, Thiruvalla, [2]Senior Consultant, Department of Neurology, [3]Senior Consultant, Department of Radiology, [4]Consultant, Department of Internal Medicine and Rheumatology, VPS Lakeshore Hospital, Kochi, Kerala, India

A 53-year-old hypertensive female was found to be unresponsive in her bed early in the morning. She was unconscious with fluctuating blood pressure and normal oxygen saturation. She was noted to have dense right hemiplegia. Computed tomography (CT) brain showed evidence of an old infarct. Electroencephalogram revealed evidence of diffuse encephalopathy. Echocardiogram, Holter study, coronary angiogram, and CT pulmonary angiogram were normal. She had acute onset right hemiplegia a week back and was detected to have acute infarct involving corona radiata on the left side (Fig. 1). She recovered fully in 3 days and was discharged on the 5th day. Her cardiac evaluation and neck vessel Doppler were normal. She had a history of adrenocortical carcinoma secreting cortisol and dehydroepiandrosterone sulfate (DHEAS) with dysregulated cortisol hypersecretion. Her sensorium gradually improved. However, she continued to have cognitive problems, especially pathological laughter, and had dense right hemiplegia. She was brought to our center 6 weeks after the event.

Clinical evaluation revealed a hemodynamically stable patient with a blood pressure of 130/80 mmHg. Higher mental functions revealed emotional lability with pathological laughter and cognitive problems mainly of recent memory impairment with Mini-Mental State Examination score of 16 and Addenbrooke's Cognitive Evaluation score of 65. She had dysarthria, her pupils were reacting to light and other cranial nerves were normal. She had dense weakness of the right upper limb, power being 0/5 and right lower limb power was 3/5, and left side being normal. Deep tendon reflexes were bilaterally brisk more so on the right side. The plantar was extensor on the right. Other systems were normal.

Magnetic resonance imaging (MRI) brain revealed evidence of subacute infarct in the left periventricular region and capsuloganglionic region. There were diffuse white matter hyperintensities involving the subcortical and periventricular white matter bilaterally without much contrast enhancement and white matter diffusion restriction. MRI brain showed a pattern suggestive of delayed post-hypoxic leukoencephalopathy (Fig. 2). This MRI appearance has only limited differentials. They include toxic leukoencephalopathy (related to drugs of abuse like heroin or medications such as vigabatrin, methotrexate, and carmofur), metabolic leukoencephalopathy such as phenylketonuria, extrapontine myelinolysis, inflammatory disorders such as multiple sclerosis, acute disseminated encephalomyelitis, post-traumatic diffuse axonal injury, and fat embolism.

Her history was reviewed again. In a retrospective manner, the family recollected that she was sleeping in a closed room and as it was cold, a tray of half-burnt charcoal briquettes had been kept in her room for warming it up. At around 4:00 am, her husband heard her make some abnormal sounds, tried to wake her up, but she did not wake up and was found unresponsive. Her son who had slept in the same room also had some discomfort the next day with vomiting. He improved over the course of the day. With this background history and the MRI picture suggestive of delayed leukoencephalopathy pattern, it was well fitting with carbon monoxide poisoning. However, it was already 6 weeks post-exposure when she reached our center. At this point of time, there was no means to confirm the diagnosis.

Complete blood counts, B12, thyroid-stimulating hormone, and toxicology studies were normal. Antinuclear antibody and antiphospholipid antibody were negative. Lumbar puncture and cerebrospinal fluid evaluation were done to rule out encephalitis. It was normal including an infective panel for viruses, bacteria, or fungus, autoimmune encephalitis panel, and paraneoplastic panel. The endocrine evaluation showed a non-suppressed ONDST, LDDST, elevated 24 h free urinary cortisol, low adrenocorticotropic hormone with normal metanephrine, testosterone, and normal DHEAS. There was a heterogeneous lesion in the right adrenal gland with calcification with positron emission tomography CT showing fluoro-2-deoxy-D-glucose non-avid lesion. Hence, features were suggestive of cortisol secreting right adrenal adenoma with the possibility of adrenocortical carcinoma. Her encephalopathy was in no way associated with the adrenal lesion.

She was started on cognitive enhancers and drugs to improve mitochondrial function. She was also started on escitalopram for her pathological laughter and emotional lability. Meanwhile, she

Access this article online

Received - 06 February 2022
Initial Review - 17 February 2022
Accepted - 02 March 2022

DOI: 10.32677/ijcr.v8i3.3312

Quick Response code

Correspondence to: Muhammed Jasim Abdul Jalal, Department of Internal Medicine and Rheumatology; VPS Lakeshore Hospital, Nettor, P.O., Kochi, Kerala - 682040, India. E-mail: jasimabduljalal@yahoo.com

© 2022 Creative Commons Attribution-NonCommercial 4.0 International License (CC BY-NC-ND 4.0).

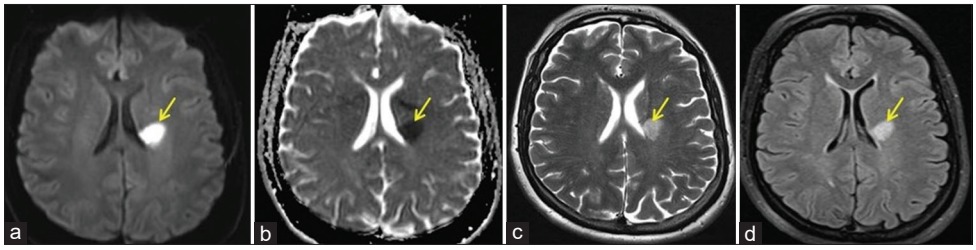

Figure 1: (a and b) Diffusion-weighted with apparent diffusion coefficient showing acute diffusion restricting infarct in the left corona radiata. (c) T2W and (d) fluid-attenuated inversion recovery sequences showing hyperintensity in the diffusion restricting areas

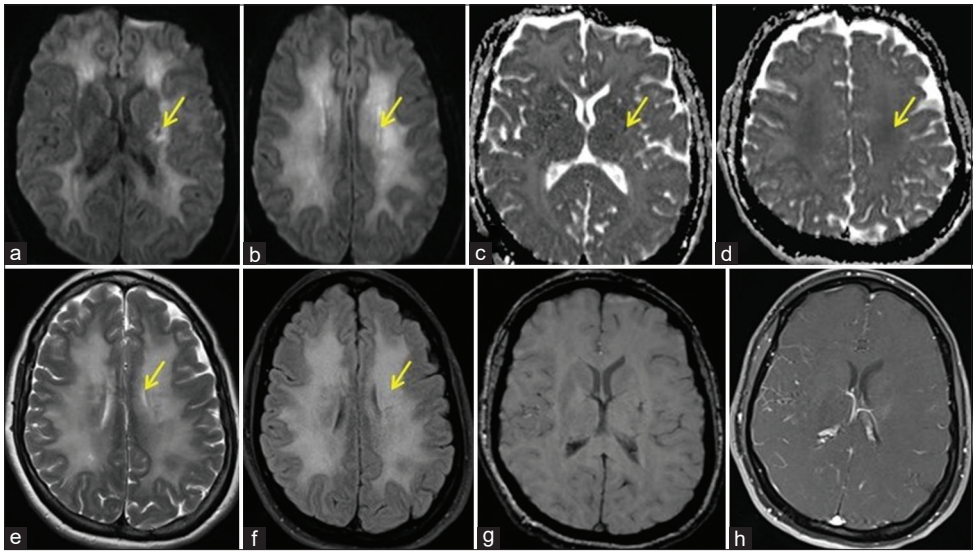

Figure 2: (a and b) Diffusion weighted; (c and d) apparent diffusion coefficient showing subacute infarct in the left corona radiata with periventricular hyperintensities showing mild diffusion restriction. (e) T2, W and (f) fluid-attenuated inversion recovery sequences showing periventricular hyperintensities. (g) Susceptibility-weighted showing no microhemorrhage. (h) Post-contrast showing no contrast enhancement

was given good cognitive and speech therapy and physiotherapy. Her cognitive functions improved significantly over the next 2 weeks. She was advised to follow-up after 2 months but due to COVID-19 travel restrictions, she could not make it physically. However, she remains in touch with us and her neurological status has improved except for her right upper limb weakness.

Delayed post-hypoxic leukoencephalopathy (DPHL) is a demyelinating syndrome characterized by acute onset of neuropsychiatric symptoms days to weeks following apparent recovery from coma after a period of prolonged cerebral hypo-oxygenation. The diagnosis can be supported by neuroimaging evidence of diffuse hemispheric demyelination sparing cerebellar and brainstem tracts, or by an elevated cerebrospinal fluid myelin basic protein. The earliest and most extensively described cases of DPHL were caused by carbon monoxide (CO) poisoning. A case series by Plum and Posner demonstrated a remarkably similar presentation in association with surgical anesthesia complications, cardiac arrest, or asphyxial gas poisoning. Subsequently, delayed leukoencephalopathy has been described in the setting of strangulation, hemorrhagic shock, and overdoses of opiates and/or benzodiazepines. All of these events fit into one of three main categories defined by Plum and Posner: Anoxic anoxia (oxygen fails to reach the blood due to low environmental tension or pulmonary function), anemic anoxia (low oxygen-carrying capacity of blood as in CO poisoning), or ischemic anoxia (failure of cerebral blood flow).

Carbon monoxide has a 210 times greater affinity for hemoglobin than oxygen. A small environmental concentration, therefore, can cause toxic levels of carboxyhemoglobin. Carbon monoxide has a predilection for watershed areas of the brain where there is a meager blood supply. The basal ganglia with their high oxygen consumption are most often affected. Other commonly affected areas are the cerebral white matter hippocampus or cerebellum. The concentration of carbon monoxide in the atmosphere ranges between 0.05 and 0.12 ppm and the average levels in homes range between 0.5 and 8 ppm. The exhaust from a burning wood fire at home would increase it to 5000 ppm. Six to eight hours of exposure to 35 ppm CO cause headache and dizziness, whereas, it only takes 2–3 h of exposure to 100 ppm CO and 1–2 h of 400 ppm CO to produce the same symptoms. Forty-five minutes of exposure to 800 ppm CO can cause dizziness and convulsions. Exposure to 1100 ppm CO can cause death in 2 h, and at 12,800 ppm CO, death can occur in <3 min. It is well-documented that even a small quantity of burnt coal is enough to create a dangerous amount of carbon monoxide in a closed room. Delayed neurological manifestations of CO poisoning or DPHL classically conform to one of two general categories of clinical presentation: Parkinsonism or akinetic mutism [1]. In addition to characteristic parkinsonian,

motor features (masked facies, rigidity, short stepped gait, and tremor) dystonic posturing, agitation, apathy, hallucinations, or odd behaviors may also be present. They have extremely slow verbal responses with varying degrees of impaired cognition or emotional lability. Akinetic mute patients will be profoundly apathetic and can have functional bowel and bladder incontinence, minimal primitive responses to pain, and pathologic laughter or crying.

The clinical diagnosis of acute CO poisoning is essentially based on circumstantial evidence. It should be confirmed by demonstration of an elevated level of HbCO in arterial or venous blood. Analysis of HbCO requires direct spectrophotometric measurements in specific blood gas analysis. The MRI findings of DPHL are nearly pathognomonic. Diffuse hyperintensity of cerebral white matter will be present on T2-based sequences, particularly in the region of the dorsal frontal and parietal lobes known as the centrum semi-ovale. The longer duration of diffusion restriction of cerebral white matter in DPHL may be due to the trapping of water molecules within areas of defective myelin and due to oligodendrocyte apoptosis or other inflammatory changes [2,3]. The classic finding on MRS is a choline peak which indicates increased lipid turnover (as seen in acute demyelination) [4,5].

REFERENCES

1. Shprecher D, Mehta L. The syndrome of delayed post-hypoxic leukoencephalopathy. Neurorehabilitation 2010;26:65-72.
2. Keogh CF, Andrews GT, Spacey SD, Forkheim KE, Graeb DA. Neuroimaging features of heroin inhalation toxicity: Chasing the dragon. Am J Roentgenol 2003;180:847-50.
3. Chen-Plotkin AS, Pau KT, Schmahmann JD. Delayed leukoencephalopathy after hypoxic-ischemic injury. Arch Neurol 2008;65:144-5.
4. Shprecher DR, Flanigan KM, Smith AG, Smith SM, Schenkenberg T, Steffens J. Clinical and diagnostic features of delayed hypoxic leukoencephalopathy. J Neuropsychiatry Clin Neurosci 2008;20:473-7.
5. Arciniegas DB, Frey KL, Anderson CA, Brousseau KM, Harris SN. Amantadine for neurobehavioural deficits following delayed post-hypoxic encephalopathy. Brain Injury 2004;18:1309-18.

Funding: None; Conflicts of Interest: None Stated.

How to cite this article: Sivji M, Vidya MV, Pratap T, Jalal MJ. Pathological laughter in a patient with recent stroke: An interesting cause. Indian J Case Reports. 2022;March 10 [Epub ahead of print].