

Wegener's granulomatosis masquerading as Pansinusitis and Nasal Polyposis: a diagnostic Dilemma

Apoorv Giri¹, Arun P. Bakshi, Pradeep S. Umap², Anuradha V. Shrikhande

From, the Department of Pathology, Indira Gandhi Government Medical College and Hospital, Nagpur, Maharashtra, 1 Swami Ramanand Teerth Government Medical College and Hospital, Ambajogai, Beed, Maharashtra 2 Government Medical College and Hospital, Akola, Maharashtra, India

Correspondence to: Dr. Apoorv Giri, Department of Pathology, Swami Ramanand Teerth Rural Medical College and Hospital, Ambajogai, Dist. Beed, Maharashtra, Email: g.apoorv30@gmail.com

Received: 04 Feb 2017

Initial Review: 16 Mar 2017

Accepted: 28 Mar 2017

Published Online: 09 Apr 2017

ABSTRACT

Wegener's Granulomatosis is characterized by granulomas of the upper and lower respiratory tracts, glomerulonephritis and systemic vasculitis of small and medium sized vessels. A "limited" form of the disease points to the presence of clinical findings restricted to the upper respiratory tract and/or lungs. Limited sino-nasal disease is rare and, coupled with the higher incidence of tuberculosis, bacterial and fungal sinusitis, a timely diagnosis often poses a challenge. We present a case of a female patient in the seventh decade with features of pansinusitis and nasal polyps, initially diagnosed as, granulomatous lesion of infective etiology, which later turned out to be Wegener's granulomatosis.

Keywords: Wegener's granulomatosis, nose, paranasal sinuses, nasal polyps.

Wegener's granulomatosis (WG) is an uncommon primary systemic vasculitis characterized by the triad of acute necrotizing granulomas of the upper respiratory tract and/or the lower respiratory tract, necrotizing or granulomatous vasculitis involving small to medium sized vessels and necrotizing glomerulonephritis [1]. The involvement of nose and paranasal sinuses may initially be in the form of chronic non specific inflammation [2] and the radiological features often mimic other entities most notably nasal cocaine necrosis, sarcoidosis, and extranodal nasal lymphoma [3]; however, presentation with nasal polyposis is uncommon.

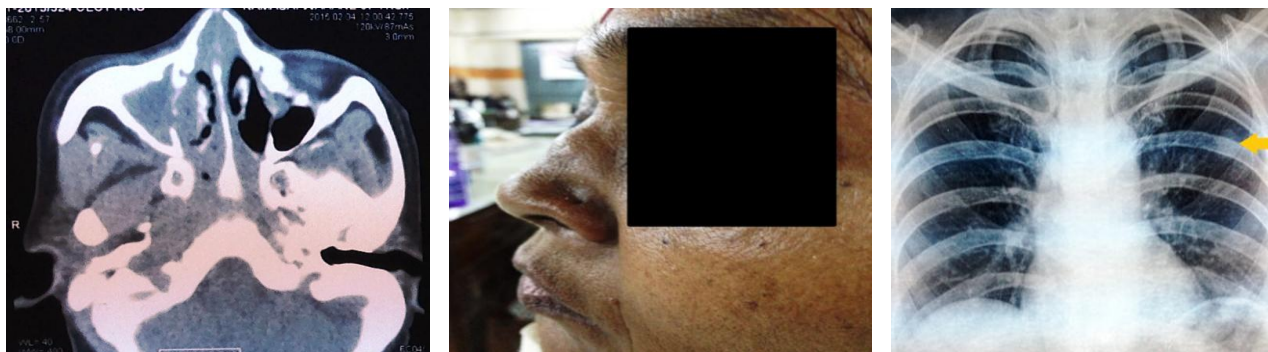CASE REPORT

A 61 year old female patient presented to the OPD with history of persistent mucoid nasal discharge, headache,

pain around nose and middle part of face, low grade fever on and off since 4 months and one or two episodes of self-limited epistaxis. The CT scan of paranasal sinuses showed pansinusitis with nasal polyp [Figure1].

She had undergone polypectomy at another medical facility where the diagnosis of granulomatous lesion, possibly of mycobacterial or fungal aetiology, was made and treatment started. However, since 1 month the discharge had turned purulent along with redness and pain in the eyes and associated with high grade fever, loss of appetite and weight and malaise.

Clinical examination revealed saddle nose deformity [Figure2], tenderness over both maxillary sinuses, crusting of nasal mucosa with polypoidal thickening, septal perforation and foul smelling discharge.



Figures: Fig. 1 - NCCT of nose and paranasal sinuses showing polypoid protrusion of the maxillary mucosa into right nasal cavity. Fig. 2 - Saddle nose deformity. Fig. 3 - Chest X-ray showing a solitary nodular opacity in the upper lobe of the left lung (arrow).

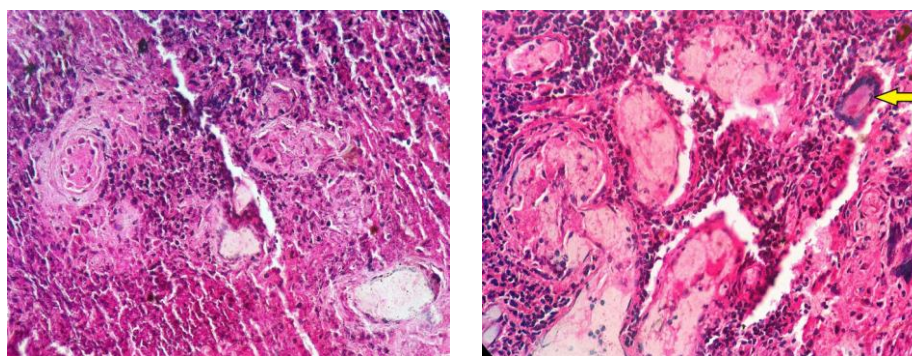


Figure 4 - Photomicrograph showing widespread necrosis with perivascular inflammatory infiltrate and fibrinoid necrosis of the vessel wall (H&E, 400X). Figure 5 - Photomicrograph showing leukocytoclastic vasculitis and fibrinoid necrosis of the vessel walls and a Langhans giant cell (arrow) (H&E, 400X)

Laboratory tests showed anemia (Hb = 8.5 gm/dL) and elevated TLC (12,450/ μ L). Kidney function tests (Sr. creatinine = 0.8mg/dL and BUN = 18 mg/dL), liver function tests and ESR (12 mm in 1st hour) were within normal limits. Her chest X-ray showed a solitary nodule in the left mid-zone [Figure 3]. A repeat nasal mucosal biopsy showed the presence of geographic, dirty necrosis with Langhans giant cells and vasculitis with fibrinoid necrosis of the blood vessels [Figures 4 and 5]. Fite-Faraco and per-iodic acid schiff (PAS) stains were non-contributory. Cytoplasmic, anti-neutrophil cytoplasmic antibody (c-ANCA) by indirect immunofluorescence (IIF) was weakly positive (1:40 titers).

Thus a diagnosis of WG was made and the patient was put on methotrexate (15mg/week) and prednisolone (40mg/day) over 4 weeks. There was an improvement in her symptoms and she was discharged after 4 weeks with tapering dose of prednisolone while maintaining methotrexate. However, the patient was lost to follow up

and presented in the emergency with hemoptysis a month later. Her kidney function tests were deranged and she died the next morning due to diffuse alveolar haemorrhage.

DISCUSSION

The American College of Rheumatology (ACR), in 1990, outlined 4 criteria [4] to define WG out of which at least 2 should be present, namely, 1) painful or painless nasal and oral ulcers or purulent or bloody nasal discharge; 2) chest radiograph showing the presence of nodules, fixed infiltrates or cavities; 3) microhaematuria (more than five red blood cells per high power field) or red cell casts in urine sediment, and 4) histological changes showing granulomatous inflammation within the wall of an artery or in the perivascular or extravascular area (artery or arteriole).

Wegener's Granulomatosis Etanercept Trial (WGET) [5,6] group defined limited disease as one which fulfilled

the ACR criteria along with the following features: 1) The patient has no red blood cell casts in the urine. 2) If hematuria is present (but no red blood cell casts), the serum creatinine is ≤ 1.4 mg/dl, no evidence of a rise in creatinine $>25\%$ above the patient's baseline level. 3) Circumscribed pulmonary involvement, such that the room air PO₂ is >70 mm Hg or the room air O₂ saturation by pulse oximetry is $>92\%$. Pulmonary hemorrhage may be treated as limited disease provided there is no evidence of progression of the process. 4) No disease may exist within any other critical organ that, without the immediate institution of maximal therapy (i.e., pulse methylprednisolone and daily oral cyclophosphamide), threatens the function of that organ and/or the patient's life.

The exact incidence and prevalence of Wegener's granulomatosis in India is not known [7]. Of the 25 cases analyzed by Kumar A et al [8], only 2 had limited disease involving the upper respiratory tract. Pradhan VD et al [9] reported limited disease in 7 out of the 28 patients studied, out of which 6 had upper respiratory tract involvement; of these cases, 71.4% showed ANCA positivity as compared to 81.2% cases of classical WG. The WGET cohort of 180 patients included 52 patients with limited disease, 88.5% of whom had ENT involvement [6]. However, none of these studies have documented nasal polyps as a presenting feature of the disease. The commonest symptoms of active sinonasal disease elucidated are nasal crusting (69%), chronic rhinosinusitis (CRS) symptoms (61%), nasal obstruction (58%), and serosanguinous nasal discharge (52%) [10]. Although few authors have reported the presence of sinonasal mass or tumour tissue at initial presentation of WG [11-14], only 1 case report of WG that demonstrated nasal polyp as one of the presenting features has been documented [15]. The imaging features of granulomatous involvement of the sinonasal compartment include osseous erosion and destruction, mucosal thickening and neoosteogenesis, which overlap with the aforementioned entities [3].

Histopathologically, WG lesions are characterized by granulomatous inflammation (scattered giant cells, poorly formed granulomas), necrosis (neutrophilic microabscesses, geographic necrosis) and angiitis (leukocytoclastic, necrotizing, granulomatous). The presence of any one or two of these traits should alert the pathologist to the possibility of WG [16]. However, these features are shared by infectious diseases (e.g.

tuberculosis, leprosy, fungal infection etc.), lymphoma and autoimmune disorders like sarcoidosis [17]. C-ANCA measurement by IIF is a sensitive marker; however it is difficult to establish a diagnosis of WG in the early stages or in the limited forms where the sensitivity of the test may fall to 67% [18].

The present case is unique because the initial symptoms were non-specific and imaging showed a rare presenting feature of WG, an uncommon disease; this was compounded by the histological attributes overlapping with those of infectious diseases (especially tuberculosis), which have a higher prevalence in this region.

CONCLUSION

The increased recognition of WG in India mandates that isolated, unresolving or worsening sinonasal lesions, including polyps, despite adequate treatment of the presumed diagnosis and in the absence of an objective evidence of chronic infection or malignancy, should raise the suspicion of limited WG. The presence of one or two of the above mentioned histological features should raise the suspicion of WG. The diagnosis should be arrived at by correlating clinical, radiological and histological features and corroborated with ANCA titers.

REFERENCES

1. Mitchell RN, Schoen FJ: Blood Vessels. In: Kumar V, Abbas AK, Fausto N, Aster JC, Editors Pathological Basis of Disease. 8th Edition. Philadelphia: Elsevier Saunders: 2010; p 516-517.
2. Mujagic S, Sarihodzic S, Huseinagic H, Karasalihovic Z. Wegener's granulomatosis of the paranasal sinuses with orbital and central nervous system involvement-diagnostic imaging. *Acta Neurologica Belgica*. 2011; 111(3): 241-4.
3. Pakalniskis MG, Berg AD, Policeni BA, Gentry LR, Sato Y, Moritani T, et al. The many faces of granulomatosis with polyangiitis: a review of the head and neck imaging manifestations. *Am J Roentgenol*. 2015; 205(6): W619-29.
4. Leavitt RY, Fauci AS, Bloch DA, Michel BA, Hunder GG, Arend WP, et al. The American College of Rheumatology 1990 criteria for the classification of Wegener's granulomatosis. *Arthritis Rheum*. 1990; 33:1101-7.
5. Stone JH. Limited versus severe Wegener's granulomatosis: baseline data on patients in the Wegener's granulomatosis etanercept trial. *Arthritis & Rheumatism*. 2003; 48(8):2299-309.

6. The WGET Research Group. Design of the Wegener's Granulomatosis Etanercept Trial (WGET). *Control Clin Trials* 2002; 23: 450–68.
7. Kaushik ML, Sinha PK, Pandey D, Pal LS, Kashyap S. Limited Wegener's granulomatosis presenting as multiple lung nodules. *Indian Journal of Chest Diseases and Allied Sciences*. 2004; 46(1): 39-42.
8. Kumar A, Pandhi A, Menon A, Sharma SK, Pande JN, Malaviya AN. Wegener's granulomatosis in India: clinical features, treatment and outcome of twenty-five patients. *Indian J Chest Dis Allied Sci*. 2001; 43(4):197-204.
9. Pradhan VD, Badakere SS, Ghosh K, Almeida A. ANCA: Serology in Wegener's granulomatosis. *Indian J Med Sci*. 2003; 59 (7): 292-300.
10. Alam DS, Seth R, Sindwani RA, Woodson EA, Rajasekaran K. Upper airway manifestations of granulomatosis with polyangiitis. *Cleveland Clinic J Med*. 2012; 79: S16-21.
11. Duggal L, Jain N. Limited Wegener's Granulomatosis. *J Indian Acad Clin Med*. 2004; 5(2):186-7.
12. Ghosh A, Bandyopadhyay D, Basu S, Majumdar A, Dutta S. ANCA-negative limited Wegener's granulomatosis. *Indian J Dermatol Venereol Leprol*. 2004; 70(2):102.
13. Zycinska K, Wardyn KA, Piotrowska E, Zielonka TM, Zycinski H, Bogaczewicz A, et al. Rhinologic and sinonasal changes in PR3 ANCA pulmonary vasculitis. *Eur J Med Res*. 2010; 15(2):241.
14. Illum P, Thorling K. Wegener's granulomatosis long-term results of treatment. *Ann Otol Rhinol Laryngol*. 1981; 90(3): 231-5.
15. Gupta A, Bhardwaj S. Wegener's Granulomatosis Presenting as Nasal Polyp. *JK Science*. 1999; 1(2): 26-28.
16. Raynaud P, Garrel R, Rigau V, Poizat F, Vic P, Cartier C, et al. How can the diagnostic value of head and neck biopsies be increased in Wegener's granulomatosis: a clinicopathologic study of 49 biopsies in 21 patients. *Annales de pathologie* 2005; 25(2): 87-93.
17. Aubry MC. Necrotizing granulomatous inflammation: what does it mean if your special stains are negative? *Modern Pathology*. 2012; 25: S31-8.
18. Nolle B, Specks U, Lüdemann J, Rohrbach MS, DeRemee RA, Gross WL. Anticytoplasmic autoantibodies: their immunodiagnostic value in Wegener granulomatosis. *Ann Internal Med*. 1989; 111(1): 28-40.

How to cite this article: Giri A, Bakshi A P, Umap P S, Shrikhande AV, Wegener's granulomatosis masquerading as Pansinusitis and Nasal Polyposis: A diagnostic Dilemma. *Indian J Case Reports*. 2017; 3(2): 70-73.

Conflict of interest: None stated, Funding: Nil