

Saving and early discharge of a neonate with severe meconium aspiration syndrome

Mrinal S Pillai¹, Archana Dinaraj², Bhavya S², Kristin Indumathi¹

From ¹Consultant Neonatologist, Sree Uthradom Thirunal Hospital, Pattom Palace, Thiruvananthapuram, Kerala, India, ²Pediatrician, Sree Uthradom Thirunal Hospital, Pattom Palace, Thiruvananthapuram, Kerala, India

ABSTRACT

Surfactant is the treatment of choice in severe respiratory distress syndrome. Intubation, administration of surfactant, extubation (INSURE) is never reported to have been used for meconium aspiration syndrome (MAS) although it is used as the standard method of delivery of surfactant for respiratory distress syndrome. This is a case report of the use of INSURE technique for severe MAS. The baby was born at term gestational age to a primigravida mother by C-section for fetal distress. The baby was vigorous with chest retractions. Hence, the baby was supported with delivery room Continuous positive airway pressure and shifted to Neonatal Intensive Care Unit (NICU). In NICU, the baby was stabilized and given surfactant using the INSURE technique. Subsequently, a chest X-ray showed clearing of lung infiltrates and drastically reduced oxygen requirement of the baby and the baby was discharged early to home.

Key words: Meconium aspiration, Neonate, Ventilation

About, 10% of cases of respiratory failure in all neonates are due to Meconium aspiration syndrome (MAS). It is associated with significant morbidity and high mortality (up to 40%) [1,2]. The most common cause of Persistent pulmonary hypertension (PPHN) is MAS. At present, the management of neonates with MAS involves only supportive care such as oxygen therapy, iv antibiotics for co-existing sepsis, assisted ventilation, inhaled nitric oxide, and if available, extracorporeal membrane oxygenation (ECMO). A recent review shows that administration of surfactant either as bolus therapy in ventilated infants or as the diluted form to lavage the lungs may be beneficial [3]. However, there is not much literature found on the use of surfactant by intubation, administration of SURfactant (INSURE) technique in MAS.

CASE REPORT

A 27-year-old pregnant female was admitted with labor pain at 38 weeks gestational age at a multi-specialty hospital.


On admission, her heart rate was 60–80 per min, the blood pressure was normal, and was afebrile. The delivery was done by emergency C-section because of fetal bradycardia. Amniotic fluid was meconium stained. The baby cried immediately after birth.

Resuscitation included oral suction, delivery room CPAP using a face mask, and T-piece resuscitator.

The baby was showing signs of severe respiratory distress such as tachypnea, continuous grunting, severe intercostal retractions, and nasal flare. Saturation by pulse oximetry was between 85 and 90% with a 100% fraction of inspired oxygen delivered by mask and T-piece resuscitator as CPAP. Heart rate was 160–170 per min. APGAR scores at 1 min and 5 min were 8 and 9, respectively. The birth weight of the baby was 3.36 kg, his head circumference was 34 cm, and the length was 48 cm.

Blood gas suggestive of respiratory acidosis: Ph 7.26, pCO₂ 72, HCO₃ 20, and BE-8. Screening Echo showed the absence of any structural heart disease. Chest X-ray revealed bilateral infiltrates completely filling the lung fields (Fig. 1a). Hence, a diagnosis of severe MAS was made.

At birth, the baby had severe respiratory distress, and pulse oximeter saturation was 85–90%, hence was shifted to the Neonatal Intensive Care Unit (NICU) with Continuous positive airway pressure (CPAP). In NICU, the baby continued to need nasal CPAP with FiO₂ of 100% to maintain saturation of 85–90%. The baby was given intravenous antibiotics as per unit policy. The baby was hemodynamically stable. The baby was intubated with a 3.5 size endotracheal tube and given positive pressure ventilation with a T-piece resuscitator. Beractant Surfactant 12 ml volume was given intratracheal at 1 h of life and the baby was supported with positive pressure ventilation. Positive pressure

Access this article online	
Received - 16 January 2022 Initial Review - 27 January 2022 Accepted - 08 February 2022	Quick Response code 
DOI: 10.32677/ijcr.v8i2.3250	

Correspondence to: Dr. Mrinal S Pillai, TC-3/629, TKD Road, Muttada P.O., Thiruvananthapuram - 695 025 Kerala, India. E-mail: mrinalhere@gmail.com

© 2022 Creative Commons Attribution-NonCommercial 4.0 International License (CC BY-NC-ND 4.0).

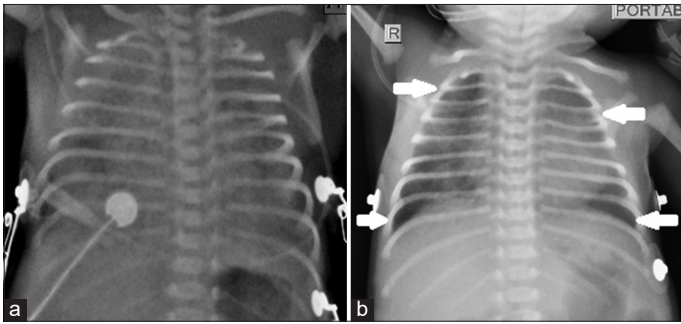


Figure 1: Chest X-ray AP view showing (a) bilateral infiltrates completely filling the lung fields; (b) clearing of infiltrates (shown by white arrows) from apical and basal regions of lung fields which were previously filled with infiltrates with persistence of fluffy infiltrates in remaining areas

delivered through the T-piece resuscitator was synchronized with the baby's inspiration by delivering positive pressure when the abdomen moved outwards with inspiration. Inspiratory time was kept very brief (Ti in newborn period should be 0.35–0.5 s) [4]. There was a drop in oxygen saturation of up to 70% and then gradually improved to 85–90% over 10 min period. Then, baby's nose was connected to nasal CPAP with 100% FiO_2 and 5 cm H_2O pressure. Oral suction was given and the baby was extubated back to CPAP 100% FiO_2 , 5 cm H_2O CPAP. The baby was nursed in the prone position. Oral secretions were minimal needing intermittent oral suction. Heart rate, respiratory rate, and saturation were continuously monitored. Blood pressure was monitored very closely at 15 min intervals. Saturation gradually improved to 99–100% and FiO_2 was gradually tapered to 60% in steps of 10% and then to 30% in steps of 5%, finally reaching 21% over 24 h period. Subsequent Chest X-ray on day 3 showed clearing of lung infiltrates (Fig. 1b).

The mother was allowed to hold the baby and she brought expressed breast milk. The baby was active with a good sucking ability. CPAP continued for 2 days followed by HFNC for two more days. Thereafter, the baby was maintaining saturation in room air and direct breastfeeds were initiated. Mild tachypnea was persisting. Empirical antibiotics were given for 5 days because of a positive sepsis screen (CRP 40 mg/L at 24 h). Blood culture was sterile. After 1 week, fast breathing improved and the baby was shifted to the mother's side. Subsequently, the baby was discharged to home. At follow-up, the baby had attained development milestones within a normal period such as social smile at 2 months, neck holding started at 3 months, and full control attained at 5 months.

DISCUSSION

MAS is defined as respiratory distress in an infant born through a meconium-stained amniotic fluid (MSAF) whose symptoms cannot be otherwise explained [5]. The severity of MAS was graded based on the requirement of respiratory support as mild MAS, requiring <40% oxygen for <48 h; moderate MAS, that requires more than 40% oxygen for more than 48 h with no air leaks, and severe MAS that requires assisted ventilation for more

than 48 h and is often associated with PPHN [6]. The baby in this case report had unstable saturation at 100% FiO_2 and the chest X-ray showed that bilateral lung fields completely filled with infiltrate suggestive of severe MAS. Surfactant replacement given within 6 h of life in such babies was shown to improve oxygenation, reduce the incidence of air leaks, the severity of pulmonary morbidity, and hospitalization time of term infants with MAS [7].

Lung lavage with dilute surfactant is an alternative to bolus therapy in MAS, which has the advantage of removing surfactant inhibitors from the alveolar space [8]. However, surfactant lavage requires giving intratracheal large volumes (20–30 ml/kg) of diluted surfactant which is practically difficult and associated with a drop in oxygen saturation which rapidly improves with continued ventilation. In a study related to the use of surfactant lavage on piglets affected by MAS, the lung injury scores, in the microscopy of histological specimens, were significantly lower in the dependent site, with better oxygenation and lung compliance, when 20 ml/kg and 30 ml/kg of diluted Beractant (5 mg/ml) were used for bronchoalveolar lavage compared to control group and intervention group where 10 ml/kg of diluted Beractant (5 mg/ml) was used [9].

Radiologically, there was a resolution of lung infiltrates, with the rapid and sustained restoration of PaO_2 , pressure-volume levels, and diminished lung inflammation, in animal studies, when 20 ml/kg of diluted KL-4 surfactant (3 times at 2 mg/ml dilution and 4th time at 15 mg/ml dilution) was used for bronchoalveolar lavage compared to control [10]. A systematic review also showed that in infants with MAS, lung lavage with a diluted surfactant may be beneficial [11].

Similarly, systematic therapy of MAS with multiple boluses surfactant therapy with continued ventilation compared to continue ventilation without surfactant therapy showed reduced severity of respiratory illness and decreased the number of infants with progressive respiratory failure requiring support with ECMO [12]. However, unlike the Randomized controlled trial (RCT) done by Findlay RD 1996 [6], in most of the later studies, the time of giving surfactant was delayed beyond the first few hours, which gives more time for meconium to damage the lung and reduced clinical improvement subsequently. Our baby received surfactant within the first 2 h. None of these studies used INSURE technique as a mode of surfactant administration. INSURE technique may be difficult due to slow recovery of saturation following administration of surfactant. However, we could maintain saturation above 85% by positive pressure ventilation with a T piece resuscitator and after extubation to CPAP. INSURE technique probably helps the baby by allowing the twin advantage of the removal of meconium/surfactant inhibitors through the laryngeal inlet which is at the dependent position in the prone position and second better alveolar recruitment. This is further supported by the clearing of lung infiltrates in the repeat Chest X-ray. We could also discharge the baby early without getting stuck with invasive ventilation.

CONCLUSION

Surfactant given by INSURE technique may be used in neonates with severe MAS similar to respiratory distress syndrome. Surfactant given by INSURE technique not only helps in alveolar recruitment but it helps in the removal of MSAF from the lungs as suggested by the clearing of infiltrates in subsequent chest X-ray. The role of early surfactant therapy of MAS (within 2 h of birth) in vigorous infants who needs intubation by INSURE technique needs to be evaluated in future RCTs. The longer the meconium stays inside the lungs, more will be the damage to the lungs due to chemical pneumonitis, hence the need for early use of surfactants.

ACKNOWLEDGMENTS

KI offered guidance. MSP was the primary physician of the neonate. MSP, AD, and BS helped in the management of the baby and writing up of the article.

REFERENCES

1. Qian L, Liu C, Zhuang W, Guo Y, Yu J, Chen H, *et al.* Neonatal respiratory failure: A 12-month clinical epidemiologic study from 2004 to 2005 in China. *Pediatrics* 2008;121:e1115-24.
2. Swarnam K, Soraisham AS, Sivanandan S. Advances in the management of meconium aspiration syndrome. *Int J Pediatr* 2012;2012:359571.
3. Natarajan CK, Sankar MJ, Jain K, Agarwal R, Paul VK. Surfactant

- therapy and antibiotics in neonates with meconium aspiration syndrome: A systematic review and meta-analysis. *J Perinatol* 2016;36:S49-54.
4. Chakkarapani AA, Adappa R, Mohammad Ali SK, Gupta S, Soni NB, Chicoine L, *et al.* Current concepts of mechanical ventilation in neonates-part 1: Basics. *Int J Pediatr Adolesc Med* 2020;7:13-8.
 5. Fanaroff AA. Meconium aspiration syndrome: Historical aspects. *J Perinatol* 2008;28:S3-7.
 6. Cleary GM, Wiswell TE. Meconium-stained amniotic fluid and the meconium aspiration syndrome. *Pediatr Clin North Am* 1998;45:511-29.
 7. Findlay RD, Taeusch HW, Walther FJ. Surfactant replacement therapy for meconium aspiration syndrome. *Pediatrics* 1996;97:48-52.
 8. Dargaville PA, Mills JF. Surfactant therapy for meconium aspiration syndrome: Current status. *Drugs* 2005;65:2569-91.
 9. Jeng MJ, Soong WJ, Lee YS. Effective lavage volume of diluted surfactant improves the outcome of meconium aspiration syndrome in newborn piglets. *Pediatr Res* 2009;66:107-12.
 10. Cochrane CG, Revak SD, Merritt TA, Schraufstatter IU, Hoch RC, Henderson C, *et al.* Bronchoalveolar lavage with KL4-surfactant in models of meconium aspiration syndrome. *Pediatr Res* 1998;44:705-15.
 11. Hahn S, Choi HJ, Soll R, Dargaville PA. Lung lavage for meconium aspiration syndrome in newborn infants. *Cochrane Database Syst Rev* 2013;4:CD003486.
 12. El Shahed AI, Dargaville PA, Ohlsson A, Soll R. Surfactant for meconium aspiration syndrome in term and late preterm infants. *Cochrane Database Syst Rev* 2014;2014:CD002054.

Funding: None; Conflicts of Interest: None Stated.

How to cite this article: Pillai MS, Dinaraja A, Bhavya S, Indumathi K. Saving and early discharge of a neonate with severe meconium aspiration syndrome. *Indian J Case Reports*. 2022;8(2):27-29.