

Hirschsprung's disease and associated syndrome and malformation: A case series of four cases

Biswanath Mukhopadhyay¹, Mandira Seal², Chhanda Das³, Madhumita Mukhopadhyay⁴

¹Senior Consultant and Former Professor, Department of Pediatric Surgery, Apollo Multispecialty Hospital, Kolkata, West Bengal, India, ²Research Scholar, ³Assistant Professor, ⁴Professor, Department of Pathology, IPGME and R, Kolkata, West Bengal, India

ABSTRACT

Hirschsprung's disease is a genetic disorder characterized by the absence of ganglion cells in different lengths of the intestine. It is one of the common causes of intestinal obstruction in neonates. We treated four cases of syndromic Hirschsprung's disease from January 2017 to January 2020 in a Tertiary care hospital. The biopsy specimens from spastic segment and colostomy or ileostomy sites were sent for evaluation of ganglion cells. Two different syndromes and one associated malformation and neoplasm were detected in patients of Hirschsprung's disease during this 3-year case study.

Key words: Ganglion cell, Hirschsprung's disease, malformation, neoplasm, syndrome


Hirschsprung's disease is a genetic disorder with a multigenic pattern of inheritance. The incidence of the disease ranges from 1 in 500 to 1 in 10,000 across the world but the Asian population has a slightly higher incidence of 2.8 in 10000 [1]. It is characterized by aganglionosis of the intestine extending up to a variable length. There is a lack of migration of neural crest cells to the myenteric and submucosal plexus resulting in a lack of peristalsis and intestinal obstruction [2]. Harald Hirschsprung, the Danish pediatrician, first identified Hirschsprung's disease in 1883 [3]. The vulnerability to Hirschsprung's disease occurs due to the alteration of multiple genes which affect the signaling pathway of RET receptor tyrosine kinase. Isolated Hirschsprung's disease has a non-Mendelian inheritance but Hirschsprung's disease with syndromes has Mendelian inheritance. In 12% of cases of isolated Hirschsprung's disease, the chromosomal abnormality was seen. In 70% of cases, Hirschsprung's disease occurs as an isolated trait, and congenital anomalies are seen in 18% of cases, and in those patients, monogenic syndromes can also be seen [2]. Malformation and neoplasm can be seen with this disease.

CASE SERIES

Case 1: The Baby with Down Syndrome

A newborn baby boy aged 2-day came to the Outpatient Department (OPD) of the tertiary care hospital with

complaints of failure to pass meconium. The patient had abdominal distension. On examination, his pulse rate was high. The general condition was also poor. Clinically, the features were suggestive of Down's syndrome. His mother was 25 years of age. She had a normal delivery. She was first gravida. The weight of the baby was 2.5 Kg. He was the first child of his mother (Fig. 1a). Her antenatal period was uneventful. After birth, the Apgar score of the baby was normal (10). Abdominal X-rays raised the suspicion of Hirschsprung's disease. His routine blood count was within normal limits and serum glucose, urea, creatinine were also in the normal range. A rectal biopsy was done and sent for a frozen section. Within half an hour, the report of the frozen section came as an absence of ganglion cells and the presence of hypertrophic nerve fiber. The residual tissue of rectal biopsy after doing frozen section was processed for formalin-fixed paraffin-embedded section. Afterward, an emergency sigmoid colostomy was done and the biopsy was taken from the colostomy site and distal part. The karyotyping of the baby was done. The karyotyping report showed the presence of Trisomy at the 21 chromosome. After getting the result of karyotyping, the same test was repeated for his parents as the baby was firstborn. But they had a normal karyotype. The histopathology report of the colostomy site showed the presence of ganglion cells and hypertrophic nerve fibers not seen. Then Duhamel pull through was performed and after 14 days, the patient was discharged. The patient is now doing well.

Access this article online	
Received - 29 November 2021 Initial Review - 07 January 2022 Accepted - 01 February 2022	Quick Response code 
DOI: 10.32677/ijcr.v8i1.3212	

Correspondence to: Madhumita Mukhopadhyay, Department of Pathology, IPGME and R, Kolkata, West Bengal, India. E-mail: madhumita1313@gmail.com

© 2022 Creative Commons Attribution-NonCommercial 4.0 International License (CC BY-NC-ND 4.0).

Case 2: The Baby with Shah Waardenburg Syndrome

A male baby aged 7 Days presented to the emergency with the features of intestinal obstruction, bilious vomiting, and failure to pass meconium after 48 h of birth. The patient had white skin. He had also a white forelock and white eyebrow (Fig. 1b). He also had changes in the pigment of the iris. Radiological and clinical examination shows the suspicion of syndromic association. The patient was clinically examined. He had a white forelock, white skin, and a distended abdomen. X-ray showed dilated bowel loops. Before surgery, the routine blood examination was done and found normal. Exploratory laparotomy was done. It showed distended small bowel and narrow large bowel (Fig. 2a). The biopsy from the different parts of the colon shows the absence of ganglion cells and the presence of hypertrophic nerve fibers (Fig. 2b). Ileostomy was done after identifying the ganglion cells on the frozen section. Afterward, a Duhamel pull-through was performed. The patient is now doing well.

Case 3: The Baby with Low Anorectal Malformation

A male baby with anorectal malformation was operated on in the newborn period. The patient was having persistent constipation in spite of a normal anus (admits tip of the little finger). Rectal biopsy was done at the age of 1 year and the histopathology was suggestive of Hirschsprung's disease and then treated accordingly.

Case 4: Baby with Neuroblastoma

A male baby aged 5 months came to the OPD with the complaint of abdominal lump and constipation since birth. After various investigations, adrenal neuroblastoma was diagnosed. After the management of neuroblastoma, constipation continued. Hence, a rectal biopsy was planned. The full-thickness biopsy was sent to the Department of Pathology. The histopathology was in keeping with Hirschsprung's disease. Then, he was also treated for the disease.

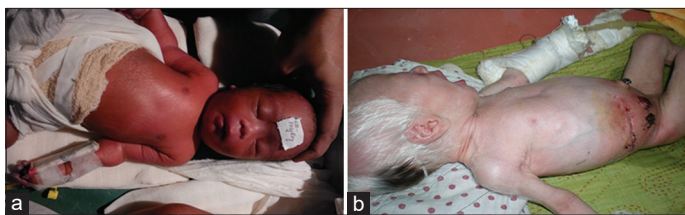

Figure 1: The baby with (a) Down's Syndrome (Case 1); (b) Shah Waardenburg Syndrome (Case 2)

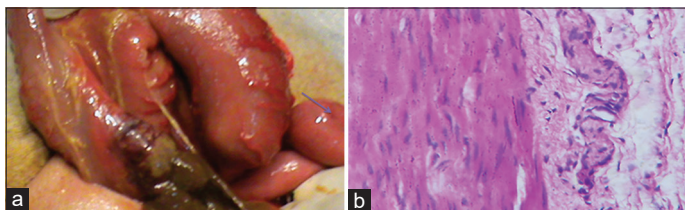


Figure 2: (a) The hypertrophied gut of the baby (Case 2); (b) Histopathological examination showing the Hypertrophic nerve fiber in Myenteric plexus (H and E 400 \times) (Case 2)

DISCUSSION

Chromosomal abnormality is seen in patients with Hirschsprung's disease. In 12% of cases, there is an abnormality of chromosome 21 mainly Trisomy 21 has been described by Amiel *et al.* in the review paper on Hirschsprung's disease with syndromes [2]. They show female predominance and with the features of Down's Syndrome, chromosomal abnormality, and short segment Hirschsprung's disease. In our case 1, the patient was male and he also had short segment aganglionosis. The patient was treated accordingly after taking a biopsy from the rectal biopsy and colostomy site. After getting the biopsy report of the abdominal pull-through. RET hypomorphic allele is overrepresented in patients of Hirschsprung's disease with Down's syndrome [2]. The low penetrance noncoding variants of one or more gene loci of RET, NRG1, SEMA3 affect the patients of Hirschsprung's disease with the syndrome. On the other hand in Trisomy 21 or high penetrance mutations in some genes-RET, GDNF, NRTN, SOX10, EDNRB, and EDN3 are also seen in these patients presenting with syndrome [1].

The association of Hirschsprung's disease and a variety of syndromes is rare. The incidence of Shah Waardenburg syndrome is 4 in 1 million [4]. The Dutch Ophthalmologist, Petrus Johannes Waardenburg described the Waardenburg syndrome which showed pigment abnormality in iris, albinism, and white forelock. When this syndrome is associated with Hirschsprung disease, it is known as Shah Waardenburg Syndrome. It is an autosomal recessive disease [4]. Mahmoudi *et al.* described a case of a 4-day old baby boy with this syndrome. The boy had a white forelock, white eyebrow, and altered iris. The patient presented with bilious vomiting and abdominal obstruction [4]. We also had a similar presentation of Shah Waardenburg Syndrome with forelock, white skin, white eyebrow, and total colonic aganglionosis in case 2. Gupta *et al.* in his paper mentioned the same features as ours in his study [5].

Approximately, 1–2% of children with Down's syndrome develop Hirschsprung's disease and 10% of patients with Hirschsprung's disease have Down's syndrome. As a result, Down's syndrome accentuates the risk of developing the disease 50–100 fold compared to the general population [6]. Genetic mutation and somatic mutation play a role in the development of Hirschsprung's disease in children. The mutation of RET proto-oncogene plays a significant role in the evolution of the autonomic and enteric nervous system and the presence of Trisomy also has some influence on the enteric nervous system [7]. Less than 80 cases of this syndrome have been reported so far in the English literature. Mutation of SOX10 (22q13.1), endothelin3/EDN3(20q13.2q13.3), (EDNRB) (13q22) is responsible for the development of Shah Waardenburg Syndrome [8]. The patient with this syndrome usually presents in the neonatal period. It is associated with a long-segment disease or total colonic aganglionosis [9]. We also had total colonic aganglionosis in Shah Waardenburg Syndrome. Shah described 12 children with Waardenburg syndrome and total colonic aganglionosis (Shah Waardenburg Syndrome) in 1981 [10]. Male predominance is

seen in most of the cases [9]. We also had a male patient with Shah Waardenburg syndrome.

Some other causes of intestinal obstruction are neonatal small left colon syndrome, meconium ileus, meconium plug syndrome, intestinal neuronal dysplasia, etc. [9]. White skin and white forelock are also seen in Tuberous sclerosis, Vitiligo, Vogt-Koyanagi-Harada syndrome, Piebaldism, Rozycki syndrome, etc. [11]. EH Raboei conducted a study on Anorectal malformation on 53 patients. Among them, three male babies were diagnosed with Hirschsprung's disease. Three babies were male and the family history of consanguinity was present in these three cases [12]. However, the association of Hirschsprung's disease and anorectal malformation is not common. It is seen in 2-3.4% of cases. Hirschsprung's disease is common in patients with anorectal malformation [13]. Rohrer *et al.* described a male baby with Congenital Central hypoventilation syndrome with Hirschsprung's disease. When he was 5-months-old, neuroblastoma was diagnosed [14]. Neuroblastoma, Hirschsprung's disease, and several other diseases have been classified under Neurocristopathy. Hence, the association of these diseases can be seen in a syndromic fashion [15].

CONCLUSION

Clinical suspicion of Down's syndrome and Shah Waardenburg Syndrome is the main clue to the diagnosis. In most of the cases of Shah Waardenburg Syndrome, total colonic aganglionosis was seen. If diagnosed early, the outcome is favorable. If constipation is a persistent symptom after the management of various lesions, Hirschsprung's disease should be excluded from the study. In all these syndromic cases, counseling of the parents and genetic sequencing of patients and parents are desirable.

REFERENCES

1. Ambartsumyan I L, Smith C, Kapur RP. Diagnosis of hirschsprung disease. *Pediatr Dev Pathol* 2020;23:8-22.
2. Amiel J, Sproat-Emison E, Garcia-Barcelo M, Lantieri F, Burzynski G, Borrego S, *et al.* Hirschsprung disease, associated syndromes, and genetics: A review. *J Med Genet* 2008;45:1-45.
3. Mukhopadhyay B, Mukhopadhyay M, Mondal KC, Sengupta M, Paul A. Hirschsprung's disease in neonates with special reference to calretinin immunohistochemistry. *J Clin Diagn Res* 2015;9:EC06-9.
4. Mahmoudi A, Ram M, Khattala K, Elmadi A, Affi M, Youssef B. Case report Shah-Waardenburg syndrome. *Pan Afr Med J* 2013;14:60.
5. Gupta R, Barolia DK, Tanger R, Agrawal LD, Gupta AK, Goyal RB. Shah-Waardenburg syndrome. *Formosan J Surg* 2017;50:163-8.
6. Heuckroth RO. Hirschsprung's disease, Down syndrome, and missing heritability: Too much collagen slows migration. *J Clin Invest* 2015;125:4323-32.
7. Moore SW. Advances in understanding the association between Down syndrome and Hirschsprung disease (DS HSCR). *Pediatr Surg Int* 2018;34:1127-37.
8. Cui L, Wong EH, Cheng G, de Almeida MF, So MT, Sham PC, *et al.* Genetic analyses of a three-generation family segregating Hirschsprung disease and Iris heterochromia. *PLoS One* 2013;8:e66631.
9. Gupta R, Sharma SB, Mathur P, Agrawal LD. Waardenburg syndrome presenting with constipation since birth. *Indian Pediatr* 2014;51:1013-4.
10. Shah KN, Dalal SJ, Desai MP, Sheth PN, Joshi NC, Ambani LM. White forelock, pigmentary disorder of irides, and long segment Hirschsprung disease: Possible variant of Waardenburg syndrome. *J Pediatr* 1981;99:432-5.
11. Ambi US, Adarsh ES, Hatti R, Samalad V. Anesthetic management of Shah-Waardenburg syndrome: Experience of two cases and review of literature. *Saudi J Anaesth* 2012;6:172-4.
12. Raboei EH. Patients with anorectal malformation and Hirschsprung's disease. *Eur J Pediatr Surg* 2009;19:325-7.
13. Nakamura H, Puri P. Concurrent Hirschsprung's disease and anorectal malformation: A systematic review. *Pediatr Surg Int* 2020;36:21-4.
14. Rohrer T, Trachsel D, Engelcke G, Hammer J. Congenital central hypoventilation syndrome associated with Hirschsprung's disease and neuroblastoma: Case of multiple neurocristopathies. *Pediatr Pulmonol* 2002;33:71-6.
15. Sato TS, Handa A, Priya S, Watal P, Becker RM, Sato Y. Neurocristopathies: Enigmatic appearances of neural crest cell derived abnormalities. *Radiographics* 2019;39:2085-102.

Funding: None; Conflicts of Interest: None Stated.

How to cite this article: Mukhopadhyay B, Seal M, Das C, Mukhopadhyay M. Hirschsprung's disease and associated syndrome and malformation: A case series of four cases. *Indian J Case Reports*. 2022;8(1):1-3.