

Squamous papilloma in the floor of the mouth: A rare presentation

Priya K Nair¹, Beena Varma², Anu Ramachandran¹, Vindhya Savithri³, Krishna S Kumar¹, Aravind M Shanmughan⁴

From ¹Assistant Professor; ²Professor Emeritus, ⁴Reader, Department of Oral Medicine and Radiology, ³Additional Professor, Department of Oral Pathology, Amrita School of Dentistry, Amrita Vishwa Vidyapeetham, Kochi, Kerala, India

ABSTRACT

Oral squamous papilloma is a benign epithelial tumor that constitutes around 2.5% of all oral verruco-papillary lesions and is caused by the Human Papilloma Virus (HPV). HPV subtypes 6 and 11, which are considered to be of low carcinogenic potential are usually associated with oral squamous papilloma. Though there is no site predilection as such, the most common intraoral sites reported are tongue, lips, buccal mucosa, gingiva, and palate. This is a case report describing the case of a 69-year-old male patient who reported the complaint of growth on the floor of the mouth for four years which was diagnosed as squamous papilloma on the floor of the mouth which is a relatively uncommon site.

Key words: Human papilloma virus, Oral cavity, Oral exophytic lesion, Squamous papilloma, Verrucopapillary lesions

Verrucopapillary lesions of the oral cavity are fairly common and are often linked with Human Papilloma Virus (HPV) [1]. HPVs are double-stranded DNA viruses that are epitheliotropic and belong to the family of papovaviridae. These viruses can infect both skin and mucosa and the viral penetration initiates infection and gains entry into the host through micro-injuries [2]. A study conducted by Rautava and Syrjanen in 2011 concluded that HPVs has the propensity to infect oral mucosa and one category of oral cancer is evidently linked with HPV [3]. HPVs can induce the formation of both benign and malignant lesions and their clinical presentation can range from benign, hyperplastic, papillomatous, or verrucous lesions to carcinomatous changes [4]. Squamous papilloma is one such benign lesion that occurs frequently on the tongue, lips, buccal mucosa, gingiva, and palate [5].

Here, we discuss the case of squamous papilloma in the floor of the mouth in a 69-year-old male patient. Through this case report, we want to highlight the fact that there can be true innocuous lesions on the floor of the mouth also but the removal of the lesion and histological examination is the better choice of management.

CASE REPORT


A 69-year-old male patient reported the complaint of growth on the floor of the mouth for four years. On eliciting the history, the

patient revealed that he noticed the growth four years back and the lesion was of present size (approximately 0.8 × 0.5 cm in size) when he first noticed it. Since then, it hasn't grown and remained the same size. The patients' medical, dental and family histories were non-contributory. He gave a history of using chewing tobacco regularly for 50 years and alcohol consumption occasionally.

His general examination was non-contributory and his vitals were within normal limits (Temperature - 37^o C, blood pressure-130/80 mm of Hg, Pulse rate-64 beats/minute). On intraoral soft tissue examination, a well-defined, solitary, ovoid, exophytic, pedunculated lesion approximately 0.8 × 0.5 cm in size was discovered in the left floor of the mouth, around 0.5 cm lateral to the opening of the submandibular duct near the sublingual fold. The lesion was pinkish in color with a whitish and pebbled surface. The lesion was soft and non-tender on palpation (Fig. 1). On intraoral hard tissue examination, multiple missing teeth (18,17,16,15,14,27,28,38,37,36,35,34,31,41,42,43,46), generalised attrition, stains, and calculus deposits on teeth were present. Based on the history and clinical presentation, a provisional diagnosis of oral papilloma was given.

A complete hematological examination was done and all parameters were within normal limits. An excisional biopsy of the lesion was planned. After obtaining informed consent from the patient, an excision biopsy of the suspected lesion was done and the specimen was sent for histopathological examination.

Histopathological examination revealed hyperplastic hyperparakeratinised stratified squamous epithelium showing

Access this article online	
Received - 07 October 2021 Initial Review - 21 October 2021 Accepted - 24 November 2021	Quick Response code 
DOI: 10.32677/ijcr.v7i12.3155	

Correspondence to: Dr. Priya K Nair, Assistant Professor, Department of Oral Medicine and Radiology, Amrita School of Dentistry, Amrita Vishwa Vidyapeetham, Kochi, Kerala, India. E-mail: priyanairkk@gmail.com

© 2021 Creative Commons Attribution-NonCommercial 4.0 International License (CC BY-NC-ND 4.0).

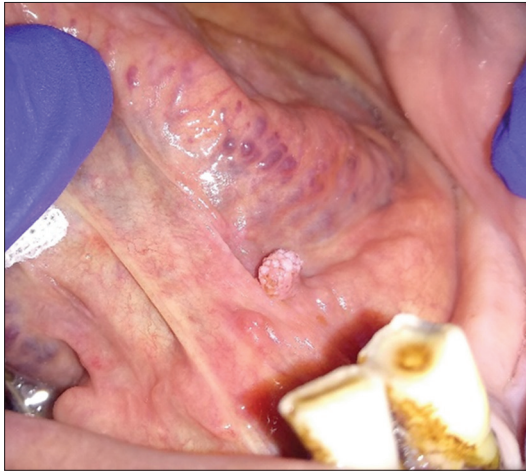


Figure 1: Well-defined, solitary, ovoid, exophytic, pedunculated lesion in the left floor of the mouth

finger-like projections with a fibrovascular connective tissue core (Fig. 2a). Connective tissue core shows numerous dilated blood vessels engorged with red blood cells and moderate inflammatory infiltrate consisting mainly of lymphocytes. Dilated ducts were observed in deeper connective tissue (Fig. 2b). A final diagnosis of squamous papilloma was given after histopathological examination.

We had contacted the patient over the phone 2 days after the procedure and reminded him about the follow-up. The patient was followed up again after 1 month over the telephone during which he reported that there was no sign of recurrence and wound healing was uneventful. We planned to keep the patient under follow-up for a period of 1 year but the patient was lost to follow-up.

DISCUSSION

Oral squamous papilloma is a non-specific term that is used to describe papillary and verrucous growths consisting of benign epithelium and minimal supporting connective tissue. They constitute around 2.5% of all oral verruco-papillary lesions [6]. They are usually asymptomatic and harmless lesions that are neither contagious nor aggressive and are the fourth most common oral mucosal lesions. Although they are usually seen in the age group of 40–50 years, they are not uncommon in children with a reported incidence of about 8% of oral tumors in children. Our patient was 69-years-old. These lesions can occur anywhere in the oral cavity but the most common intraoral sites are the tongue, lips, buccal mucosa, gingiva, and palate. In our case, the lesion was on the floor of the mouth which is not a commonly reported site in the literature. Tomes in 1848 first reported this lesion as a “gingival wart” [5]. The clinical features in our patient were consistent with those in the literature.

The HPV is implicated as the etiological agent which can be transferred sexually, mouth to mouth, and vertically from an infected mother during delivery. Even though more than 120 different HPV types have been described on the basis of isolation and sequencing of full genomes, mucosal sites are infected by alpha papillomavirus consisting of 15 species [7, 8]. Most

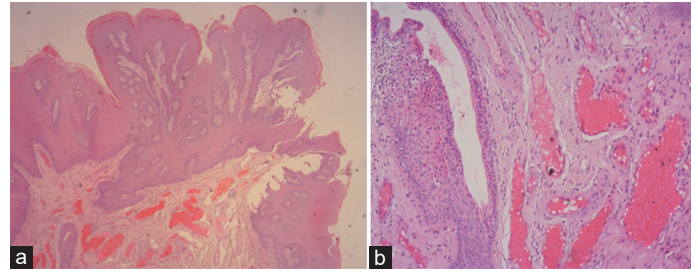


Figure 2: (a) Hyperplastic hyperparakeratinised stratified squamous epithelium showing finger like projections with a fibrovascular connective tissue core; (b) Connective tissue core showing numerous dilated blood vessels engorged with RBCs and moderate inflammatory infiltrate consisting mainly of lymphocytes

commonly, the subtypes HPV-6 and HPV-11 are associated with oral squamous papilloma [9]. The initial step in this process is the binding of HPV to heparin sulfate proteoglycans in the basement membrane followed by relocation to the nucleus where they reside as an episome. Replication and relocation of these resultant cells towards the superficial epithelial lining during the epithelial maturation process activates the viral genome to initiate the expression of genes required for viral replication. As a consequence, the shedding of mature viral particles occurs from the epithelial surface. The viability of infected epithelial cells is essential for viral replication and protection from the host immune system; these cells are not lysed by the virus [8].

Squamous Papillomas are of two types, isolated-solitary type which is usually found in an adult’s oral cavity, as was in our case, and multiple-recurring type which is mostly found in laryngotracheobronchial complex in children. Malignant transformation of these lesions is commonly seen with multiple recurring types [6]. Solitary lesions rarely recur as compared to multiple ones [7]. Clinically, HPV can present itself in three different ways (i) Transitory or subclinical infection which constitutes about 50% of the cases; (ii) Spontaneously regressing lesions which constitute about 30% of the cases; (iii) Persistent infections that do not present viral elimination even after treatment [10].

The presence of HPV in the normal oral mucosa is controversial. A great variation in the prevalence rate is noted based on the population studied and the methods and varies from 0% to 81% [2]. Syrjanen *et al.* In 1983 first proposed the involvement of HPV in head-and-neck carcinogenesis. HPV 16 and 18 considered under high-risk have a strong association with cervical cancer. HPVs 6 and 11, associated with squamous papillomas are considered to be of low oncogenic potential [7, 11]. Kreimer *et al.* calculated an overall prevalence of HPV in 25% of head and neck cancer, 35.6% in oropharyngeal cancer, and 23.5% in oral squamous cell carcinoma [12]. Smoking and alcohol may interact with HPV infection and can increase an individual’s response to oral cancer [4]. Our patient being a chronic tobacco chewer for 50 years was educated well regarding the risk and encouraged to discontinue the habit.

As per the literature, oropharyngeal carcinoma is closely associated with HPV infection. Since the epithelium of the

oropharynx and oral cavity is similar and continuous, the chances of these viruses migrating from the oropharyngeal epithelium to the oral epithelium are more. There is a considerable increase in the incidence of oral cancer which is not associated with the commonly accepted etiological factors like tobacco, alcohol, or areca nut use. So, one may seriously consider checking for HPV virus infection. More studies are needed to exclusively prove the direct connection of HPV with oral lesions, especially oral cancer with no evident etiology. That is where the need for surveillance programs comes [13].

Differential diagnosis of verruca vulgaris and condyloma acuminatum were considered as these lesions clinically resembles oral papilloma. In verruca Vulgaris, the lesions are usually seen on the mucocutaneous junction of lips, labial mucosa, or anterior tongue. Condyloma acuminatum is usually found on the ventral surface of the tongue and floor of the mouth [14]. Condyloma acuminatum is considered a sexually transmitted disease, whereas, squamous papilloma need not be associated with HPV and the association may be incidental [6]. The patient, in this case, did not report any untoward sexual habits.

The diagnosis of oral squamous papilloma is fundamentally clinical, followed by cytology, and confirmed by biopsy. There are strict histologic criteria proposed by Carneiro *et al.* and this include 'squamous epithelium arrayed in finger-like projections, normal maturation pattern, and the presence of hyperparakeratosis in the epithelium, koilocytosis as a result of perinuclear cytoplasmic vacuolization of cells of the spinous layer of the epithelium, producing perinuclear pale/clear halos, and pyknosis and the occasional presence of basilar hyperplasia' [7]. Polymerase chain reaction is a highly sensitive method of virus identification.

Oral squamous papilloma can be treated by various treatment modalities such as conservative surgical excision, laser ablation, cryotherapy, cold-steel excision, electrocautery, intralesional injections of interferon, and salicylic acid application. This should be decided upon based on various factors such as size and number of the lesion, location, willingness of the patient to undergo the procedure, availability of resources, and cost [10]. Oral papillomas differ from other papillomas as oral papillomas have a higher risk of developing into malignancy, occur with greater frequency, and have more possibility to recur [15].

CONCLUSION

The risk of development of oral cancer increases with continued exposure to HPV Infection. The risk of malignant transformation in multiple recurring types of oral squamous papillomas is high.

A periodic and thorough examination of the oral cavity should be carried out to detect HPV-associated changes in the oral mucosa. Tobacco and alcohol have a synergistic effect on the risk of developing squamous cell carcinoma. This calls for mandatory patient counseling so as to avoid and stop these deleterious habits. The concept of 5 As should be reinforced-Ask, Advise, Assess, Assist, and Arrange.

REFERENCES

1. Nayak A, Nayak MT. Oral squamous papilloma occurring on the palate with review of literature. *J Exp Ther Oncol* 2016;11:319-24.
2. Castro TP, Filho IB. Prevalence of human papillomavirus (HPV) in oral cavity and oropharynx. *Rev Bras Otorrinolaringol* 2006;72:272-82.
3. Rautava J, Syrjanen S. Human papillomavirus infections in the oral mucosa. *J Am Dent Assoc* 2011;142:906-14.
4. Kumaraswamy KL, Vidhya M. Human papilloma virus and oral infections: An update. *J Cancer Res Ther* 2011;7:120.
5. Kumar BP, Khaitan T, Ramaswamy P, Pattipati S, Sudhakar S, Geethika VR. Squamous papilloma. Report of two cases. *J Stomatol Occlusion Med* 2013;6:106-9.
6. Jaju PP, Suvarna PV, Desai RS. Squamous papilloma: Case report and review of literature. *Int J Oral Sci* 2010;2:222-5.
7. Carneiro TE, Marinho SA, Verli FD, Mesquita AT, Lima NL, Miranda JL. Oral squamous papilloma: Clinical, histologic and immunohistochemical analyses. *J Oral Sci* 2009;51:367-72.
8. van Heerden WF, Raubenheimer EJ, Bunn BK. Human papillomavirus infection of the oral cavity: What the dentist should know. *SADJ* 2017;72:52-5.
9. Syrjanen S. Human papillomavirus infections and oral tumors. *Med Microbiol Immunol* 2003;192:123-8.
10. Dos Reis HL, Rabelo PC, de Santana MR, Ferreira DC, Filho AC. Oral squamous papilloma and condyloma acuminatum as manifestations of buccal-genital infection by human papillomavirus. *Indian J Sex Transm Dis* 2009;30:40-2.
11. Neville BW, Damm DD, Allen CM, Bouquet JE. *Oral and Maxillofacial Pathology*. 3rd ed. Haryana, India: Elsevier; 2010. p. 363.
12. Campisi G, Giovannelli L. Controversies surrounding human papilloma virus infection, head and neck vs oral cancer, implications for prophylaxis and treatment. *Head Neck Oncol* 2009;1:8.
13. Pantham G, Ganesan S, Einstadter D, Jin G, Weinberg A, Fass R. Assessment of the incidence of squamous cell papilloma of the esophagus and the presence of high-risk human papilloma virus. *Dis Esophagus* 2017;30:1-5.
14. Sen R, Shah N, Sheikh MA, Chatterjee RP. Oral condyloma acuminatum in a 75-year-old geriatric patient. *BMJ Case Rep* 2018;2018.
15. Kumar AN, Rajeshwaran R, Kumar HH. Large squamous papilloma of buccal mucosa. *J Case Rep* 2012;2:110-3.

Funding: None; Conflicts of Interest: None Stated.

How to cite this article: Nair PK, Varma B, Ramachandran A, Savithri V, Kumar KS, Shanmughan AM. Squamous papilloma in the floor of the mouth: A rare presentation. *Indian J Case Reports*. 2021;7(12):513-515.