

Colon cancer in malrotated gut: A case report

Arnab Gupta, Subrata Kumar Sahu, Samir Bhattacharya, Sudip Haldar

Department of Surgical Oncology, Saroj Gupta Cancer Centre and Research Institution, Thakurpukur, Kolkata, West Bengal, India

ABSTRACT

Malrotation of the gut is a rare congenital anomaly that mostly presents in the 1st month of life. Very rarely, it is found during adulthood either as an asymptomatic incidental finding or at autopsy. Presenting in adulthood with colon cancers is extremely rare. Here, we present the case of a middle-aged male patient with unexplained anemia which on investigation was found to have adenocarcinoma at the hepatic flexure of the colon. The staging computed tomography scan of the abdomen showed the growth at the hepatic flexure with malrotation of the gut. During the laparoscopic assessment, the cecum and ascending colon were found on the left side, and hence, a formal midline incision was made. Cecum was found on the left of the midline along with Ladd's band. Extended right hemicolectomy was performed, dividing the Ladd's band, taking care of the anomalous position of superior mesenteric vessels. The post-operative period was uneventful. Histopathological examination revealed this to be well-differentiated adenocarcinoma (pT3N1b). He thereafter received adjuvant chemotherapy and remains well after 5 years of follow-up. Presentation of malrotation of the gut in adulthood is seen in only 10–15% of cases as an incidental finding or at autopsy. Cancers in the colon in these patients are extremely rare. The treatment for colon cancer remains the same although one has to be careful about the vascular anomaly during the resection.

Key words: Colorectal cancer, Gut, Ladd's band, Malrotation

Malrotation of the gut is very rare with an average incidence of 1 in 6000 live births [1]. Most of them are detected in the 1st month of life because of the obstructive symptoms. Rarely do they present late with gut-related pathologies like tumors.

We hereby present a case where a 54-year-old male patient presented with colonic cancer. During the investigation, he was found to have growth in the ascending colon. The rarity of colon cancer in malrotated gut and careful perioperative evaluation insisted us to report this case.

CASE REPORT

A 54-year-old gentleman presented at the outpatient department for unexplained anemia. The patient had a history of altered blood in stool 6 months back. There was no history of addiction and family history was irrelevant.

On examination, the vitals of the patient were stable but there was a presence of pallor. On local examination, the abdomen was soft with no palpable lumps and there was no organomegaly. Colonoscopy revealed an ulceroproliferative growth with narrowing of the lumen at the hepatic flexure. The

biopsy of the growth was reported as adenocarcinoma (Grade II). His hemoglobin was 7.5 for which he had received two units of packed red blood cell transfusion. Carcinoembryonic antigen was 1.35. Liver and renal functions were normal. Contrast-enhanced computed tomography (CECT) scan of the chest, abdomen, and pelvis was unremarkable except for the presence of a lesion in the hepatic flexure which was placed in the left side of the abdomen (Fig. 1). A final diagnosis of the right colon cancer in a malrotated gut was made on the basis of a CECT scan, colonoscopy, and biopsy report.

Surgery was planned after a discussion in a multidisciplinary tumor (MDT) board meeting. A laparoscopic staging followed by formal laparotomy was done. The cecum was found in the left side of the abdomen close to the sigmoid colon, while the ascending colon was found to be going across toward the right hypochondrium (Fig. 2). The growth was indeed found at the hepatic flexure. Ladd's band toward the right parietal wall was divided. Extended right hemicolectomy was done with standard lymphadenectomy, taking care of the superior mesenteric artery (SMA) and superior mesenteric vein (SMV) which were in a reverse relationship between themselves. The post-operative recovery was uneventful. The biopsy was reported as well-differentiated adenocarcinoma (pT3 N1b Mx).

Correspondence to: Arnab Gupta, Saroj Gupta Cancer Centre and Research Institution, Mahatma Gandhi Road, Greater Bakul Bithi, Thakurpukur, Kolkata, West Bengal - 700 063, India. E-mail: drarnabgupta1@gmail.co

© 2021 Creative Commons Attribution-NonCommercial 4.0 International License (CC BY-NC-ND 4.0).


Access this article online	
Received - 10 February 2021 Initial Review - 30 July 2021 Accepted - 13 August 2021	Quick Response code 
DOI: 10.32677/ijcr.v7i9.3023	

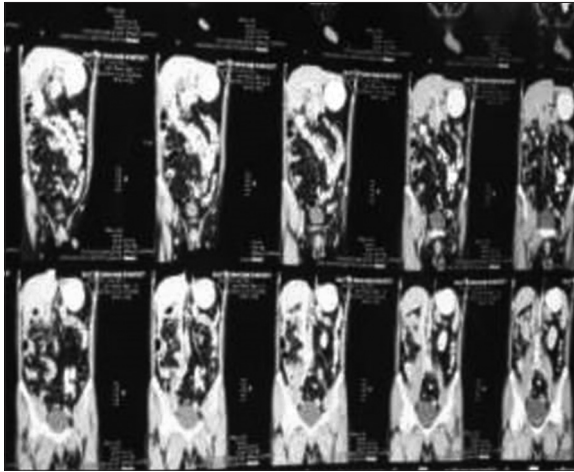

Figure 1: Contrast-enhanced computed tomography scan showing caecum in the left side of the abdomen

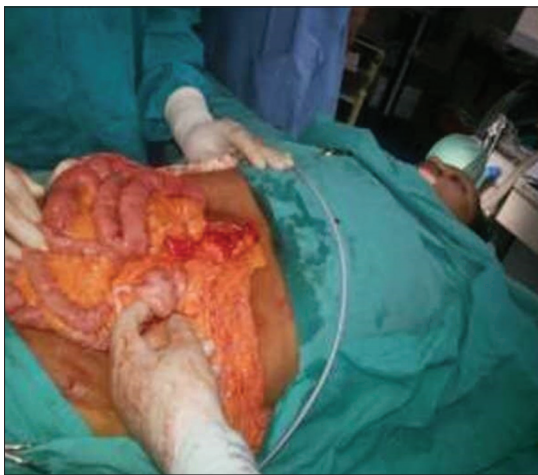

Figure 2: Cecum found at the left iliac fossa

After discussion in the MDT, he was started on adjuvant FOLFOX (5 FU, oxaliplatin, and leucovorin combination chemotherapy). For Grade III toxicity after the third cycle, he was put on three more cycles of capecitabine and oxaliplatin chemotherapy (CAPEOX). He has been on regular follow-up since then and remains well after 5 years from the time of surgery.

DISCUSSION

Intestinal malrotation is a rare congenital anomaly with an incidence of 1 in 6000 live births [1]. It occurs during the first trimester of the pregnancy when the fetal gut undergoes a complex series of growth and development. Rapid differential growth of the mid-gut starts at the 5th gestational week with herniation into the proximal umbilical cord. There is 270° counterclockwise rotation around SMA as the intestine returns to the abdomen at the 10th gestational week and fixes to the retroperitoneum. The arrest of development along this process leads to malrotation [1-3]. It mostly presents in the 1st month of life. Approximately, 10–15% present in adulthood as an incidental finding during investigations or surgery for other clinical conditions or diagnosed at autopsy.

Unless there is a high index of suspicion, the diagnosis of malrotation is often missed. In a study on 2000 adults with

barium enema, the incidence of malrotation was found to be 0.2%. Cancer of the colon along with malrotation of the gut is an extremely rare phenomenon with only 12 cases being reported worldwide in the English literature [4,5]. However, for reasons unknown, malrotation of the gut with colon cancer seems to be commoner in Japan with 48 cases being reported till date [6,7]. The first case of malrotation with carcinoma colon was published from Czechoslovakia in 1970. The first case reported from India was by Ray and Morimoto [6].

Diagnosis can be a challenge unless there is a high index of suspicion. The upper gastrointestinal series has 80% sensitivity. Recently, a CECT scan with a thorough examination of the images has become a standard investigation [8]. Laparoscopic resection with lymph nodal dissection can be done with caution with prior planning based on the imaging to avoid damage to anomalous SMA and SMV [6,9,10]. Ladd's procedure is not separately required when resection is done for the right-sided colonic tumors. The outcome remains similar to those without malrotation.

CONCLUSION

Colon cancer in a malrotated gut is extremely rare. One needs a high index of suspicion during pre-operative evaluation and requires careful dissection of SMA and SMV during surgery to avoid injury.

REFERENCES

1. Lauriti G, Miscia ME, Cascini V, Chiesa PL, Pierro A, Zani A. Intestinal malrotation in infants with omphalocele: A systematic review and meta-analysis. *J Pediatr Surg* 2019;54:378-82.
2. Soffers JH, Hiksloops JP, Mekonen HK, Koehler SE, Lamers WH. The growth pattern of the human intestine and its mesentery. *BMC Dev Biol* 2015;15:31.
3. Stalker HJ, Chitayat D. Familial intestinal malrotation with midgut volvulus and facial anomalies: A disorder involving a gene controlling the normal gut rotation? *Am J Med Genet* 1992;44:46-47.
4. Tatsuma S, Katsuji T, Shigeyoshi I, Yosuke U, Kazumasa Y, Masashi O, *et al.* A case of colon cancer accompanied with adult malrotation of intestine treated by laparoscopic surgery. *J Jpn Soc Coloproctol* 2013;66:105-9.
5. Petrou A, Papalambros A, Katsoulas N, Bramis K, Evangelou K, Felekouras E. Primary appendiceal mucinous adenocarcinoma alongside with situs inversus totalis: A unique clinical case. *World J Surg Oncol* 2010;8:49-51.
6. Ray D, Morimoto M. Malrotation of the intestine in adult and colorectal cancer. *Indian J Surg* 2015;77:525-31.
7. Donaire M, Mariadson J, Daniel S, Pillarisetty S, Wallack MK. Carcinoma of the colon in an adult with intestinal malrotation. *Case Rep Surg* 2013;2013:525081.
8. Kokubo K, Hayashi M, Iida Y, Tohii K, Fujita S, Katagiri S, *et al.* A case of caecum carcinoma with intestinal reverse malrotation. *J Jpn Coll Surg* 2011;36:965-70.
9. Tokai H, Maeda S, Nagata Y. A case of transverse colon cancer with intestinal malrotation resected by laparoscopy assisted colectomy. *J Jpn Surg Assoc* 2012;73:1497-501.
10. Bass KD, Rothenberg SS, Chang JH. Laparoscopic Ladd's procedure in infants with malrotation. *J Pediatr Surg* 1998;33:279-81.

Funding: None; Conflicts of Interest: None Stated.

How to cite this article: Gupta A, Sahu SK, Bhattacharya S, Haldar S. Colon cancer in malrotated gut: A case report. *Indian J Case Reports.* 2021;7(9):386-387.