

Ruptured hepatocellular carcinoma presenting as Cullen's and Grey-Turner's sign

Ghulam Nabi Yattoo¹, Syed Mushfiq Shafi², Neeraj Dhar², Saurabh Kaushik², Ghulam Mohd Gulzar³, Jaswinder Singh Sodhi³

From ¹Professor and Head, ²Senior Resident, ³Professor, Department of Gastroenterology, Sheri Kashmir Institute of Medical Sciences, Srinagar, Jammu and Kashmir, India

ABSTRACT

Hepatocellular carcinoma (HCC), the most common malignant liver tumor, is usually asymptomatic but rarely bleeds into the peritoneal cavity which can be a serious catastrophe. In this case report, we are presenting a case of ruptured HCC, who came to our emergency room with hepatic decompensation in the form of jaundice and progressive abdominal distention and on evaluation were found to have ruptured HCC and the classical findings associated with it were the signs of intraperitoneal bleed like Cullen's and Grey-Turner's sign which are classically mentioned in acute pancreatitis.

Key words: Cullen's sign, Grey-Turner sign, Hepatocellular carcinoma

Hepatocellular carcinoma (HCC) is the most common primary malignant tumor of the liver [1]. The incidence of the disease varies from area to area and the burden is highest in areas with endemic hepatitis B infection, with incidence rates of over 20/100,000 individuals. In intermediate endemic areas, the incidence is 10–20/100,000, whereas, in low endemic areas, the incidence is <5/100,000 individuals. Although mostly asymptomatic, when symptoms are present, the most common presentation of HCC is abdominal pain and jaundice. In about 3–15% of cases, HCC may present with a ruptured bleeding tumor [1]. Cardinal signs of intraperitoneal hemorrhage described are Grey-Turner (bluish discoloration of skin in the lumbar region) and Cullen's sign (periumbilical ecchymosis).

We are presenting a case report of HCC, complicated with intraperitoneal rupture. The rationale of reporting this case is that the chances of intraperitoneal rupture are very low, and in this case, both the classical signs of the intraperitoneal bleed are evident. These signs are very well-mentioned in association with severe hemorrhagic pancreatitis, but associating these signs with the rupture of HCC is the key here.


CASE REPORT

A 70-year-old male presented to our emergency room with complaints of jaundice and progressive abdominal distension for 5 days. The patient is a known diabetic for 20 years, on oral

hypoglycemics, has non-alcoholic fatty liver-related compensated cirrhosis (Child-Turcotte-Pugh B) with portal hypertension and low-grade esophageal varices.

On physical examination, the patient was conscious, cooperative, and well oriented to person, place, and time. His vitals recorded were a pulse rate of 68 per min. Blood pressure measured at the brachial artery level was 90/60 mmHg and a respiratory rate of 20 cycles per minute. Examination of the conjunctiva revealed mild pallor and icterus. His body temperature was normal. Examination of respiratory and cardiovascular systems revealed no significant abnormality. On abdominal examination, signs of intraperitoneal hemorrhage such as Cullen's sign (Fig. 1a) and Grey-Turner's sign (Fig. 1b) were observed. Palpation of the abdominal cavity revealed ascites, but no definitive signs of organomegaly were found.

Baseline hemogram showed severe anemia with hemoglobin 6.7 g/dl and thrombocytopenia (68,000/mm³). Mean corpuscular volume and mean corpuscular concentration values suggested the picture consistent with anemia of chronic disease. Renal function tests and blood electrolyte levels were normal. Tests for liver function showed decreased plasma albumin concentration and hyperbilirubinemia (bilirubin=4.5 mg/dl). Serum liver enzyme levels and blood coagulation profile were within normal limits. Bedside ultrasonography of the abdomen identified a liver mass with background cirrhotic changes. Triple-phase contrast-enhanced computed tomography abdomen revealed a ruptured liver mass (6.5 cm × 5.4 cm), strongly suggestive of HCC (LIRADS 4) with cirrhotic liver and moderate ascites (Figs. 2 and 3).

Access this article online	
Received - 28 July 2020 Initial Review - 24 August 2020 Accepted - 01 September 2020	Quick Response code 
DOI: 10.32677/IJCR.2020.v06.i09.002	

Correspondence to: Syed Mushfiq Shafi, Department of Gastroenterology, Doctor's Hostel, Sheri Kashmir Institute of Medical Sciences, Soura, Srinagar - 190 011, Jammu and Kashmir, India. E-mail: syedmushfiq37@gmail.com

© 2020 Creative Commons Attribution-NonCommercial 4.0 International License (CC BY-NC-ND 4.0).

The patient was admitted and the treatment was started as per the protocol. The patient received a packed red blood cell transfusion and other supportive measures such as lactulose to prevent hepatic encephalopathy, antibiotics to prevent spontaneous bacterial peritonitis, and intravenous albumin to prevent hepatorenal syndrome were instituted as per the Care of the Critically Ill Surgical Patient protocol. The patient refused to continue admission to the hospital and left against medical advice and was lost to follow up.

DISCUSSION

HCC is usually asymptomatic, but in few cases, it can present as liver dysfunction in the form of jaundice or ascites. A MEDLINE search was undertaken to identify articles using the keywords HCC, spontaneous rupture, and therapeutic embolization. All the studies, even case reports that contained materials related to the topic were considered, and we found around 1500 patients with spontaneous rupture of HCC [2].

Rarely, HCC can bleed into the peritoneal cavity (3–15%) and can produce signs of intraperitoneal bleed such as Grey-Turner's and Cullen's signs which are usually described with severe pancreatitis [1]. British surgeon George Grey-Turner described Grey-Turner's sign in 1920 in acute pancreatitis [2]. This sign is most of the times associated with retroperitoneal bleed due to acute pancreatitis, ruptured aortic aneurysm, and ruptured ectopic pregnancy. There are reported cases of this sign due to HCC [1] and perirenal hematoma [3]. Grey-Turner sign is caused by the diffusion of blood from the anterior pararenal space to the lateral edge of the quadratus lumborum muscle, passing through a defect in the transversalis fascia that leads to the subcutaneous tissue within the abdominal wall muscle and flank [4,5]. The limited extent of discoloration is explained by the corresponding attachment of the membranous superficial fascia to the deep external oblique aponeurosis [5]. The pathophysiology behind the appearance of this sign, using computerized tomography, is caused by tracking of hemorrhagic fluid and pancreatic enzymes toward the umbilicus from the retroperitoneum along the gastrohepatic and falciform ligament. Anatomically, the membranous superficial fascia creates a tube-like conduit attaching to a ring of the external oblique aponeurosis, umbilicus, and the skin [5].

The other signs of retroperitoneal bleed include Cullen's sign (periumbilical ecchymosis) [6], Fox's sign (ecchymosis of the thigh with superior border) [7], and Bryant's sign (bluish discoloration of the scrotum) [8]. These signs will assist clinicians in performing relevant investigations to arrive at a clinical diagnosis.

The management of the patient with HCC depends on the condition of the patient and associated comorbidities. If the patient

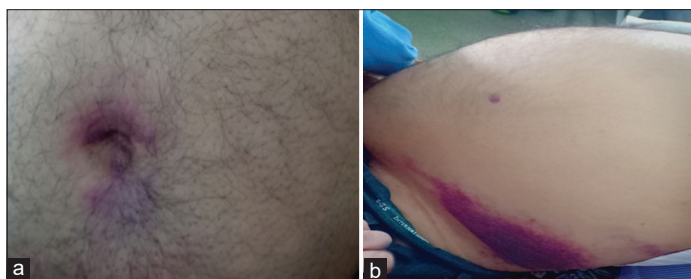


Figure 1: Clinical manifestations of hepatocellular carcinoma showing (a) periumbilical ecchymosis and (b) ecchymosis in flanks

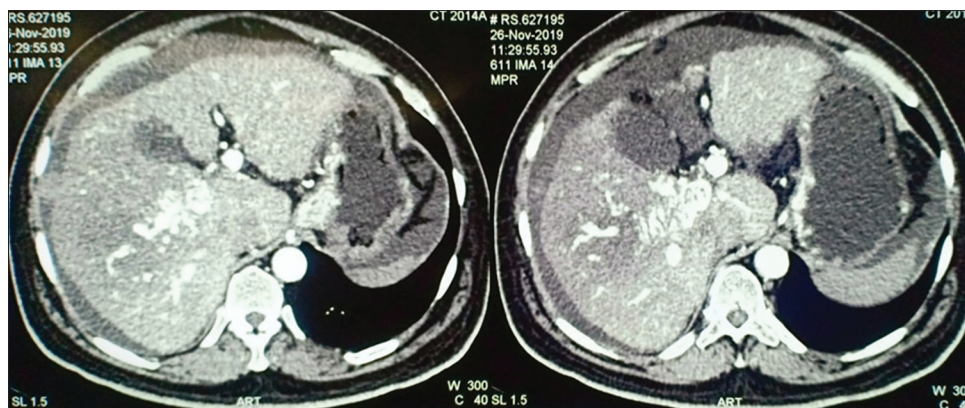


Figure 2: Arterial phase of contrast-enhanced computed tomography abdomen showing large hyperenhancing liver space-occupying lesion

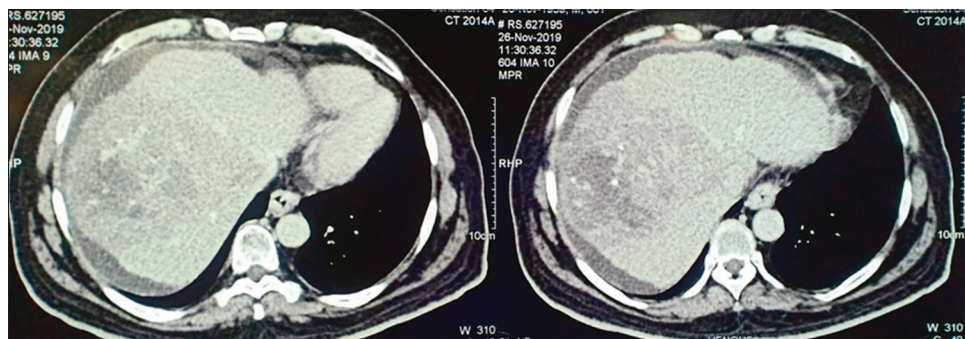


Figure 3: Portovenous phase of computed tomography abdomen showing liver space-occupying lesion with early washout of contrast

is hemodynamically stable and there are no serious complications, the patient can be treated conservatively with bed rest, adequate analgesia, and correction of any coagulopathy and anemia. The patient should be monitored for potential complications such as hypovolemic shock, muscle necrosis, and intra-abdominal hypertension. In unstable patients, urgent surgical intervention or a radiological intervention is the key to successful management.

CONCLUSION

HCC is usually asymptomatic but rarely bleeds into the peritoneal cavity which can be a serious catastrophe. The chances of intraperitoneal rupture are very low in HCC, but in the present case, both the classical signs of the intraperitoneal bleed are evident.

REFERENCES

1. Sevastianos VA, Deutsch M, Dourakis SP. Grey-turner's sign as the first indication of a ruptured hepatocellular carcinoma. *J Clin Oncol* 2004;22:1156-7.
2. Turner GG. Local discoloration of the abdominal wall as a sign of acute pancreatitis. *Br J Surg* 1920;7:394-5.
3. Chung KM, Chuang SS. Cullen and Grey Turner signs in idiopathic perirenal hemorrhage. *CMAJ* 2011;183:e1221.
4. Bosmann M, Schreiner O, Galle PR. Coexistence of Cullen's and Grey Turner's signs in acute pancreatitis. *Am J Med* 2009;122:333-4.
5. Meyers MA, Feldberg MA, Oliphant M. Grey Turner's sign and Cullen's sign in acute pancreatitis. *Gastrointest Radiol* 1989;14:31-7.
6. Cullen TS. A new sign in ruptured extrauterine pregnancy. *Am J Obstet Gynecol* 1918;78:457.
7. Fox JA. A diagnostic sign of extraperitoneal haemorrhage. *Br J Surg* 1966;53:193-5.
8. Ratzam RM, Donaldson MC, Foster JH, Walzak MP. The blue scrotum sign of Bryant: A diagnostic clue to ruptured abdominal aortic aneurysm. *J Emerg Med* 1987;5:323-9.

Funding: None; Conflicts of Interest: None Stated.

How to cite this article: Yattoo GN, Shafi SM, Dhar N, Kaushik S, Gulzar GM, Sodhi JS. Ruptured hepatocellular carcinoma presenting as Cullen's and Grey-Turner's sign. *Indian J Case Reports*. 2020;6(9):485-487.