

## Digital gangrene in spinal tuberculosis

Masaraf Hussain<sup>1</sup>, Shriram Sharma<sup>2</sup>, Baia Synmon<sup>3</sup>, Yasmeen Hynniewta<sup>4</sup>

From <sup>1</sup>Associate Professor; <sup>2</sup>Professor; <sup>3</sup>Assistant Professor; <sup>4</sup>Senior Resident, Department of Neurology, North Eastern Indira Gandhi Regional Institute of Health and Medical Sciences, Shillong, Meghalaya

### ABSTRACT

Though tuberculosis (TB) is commonly seen, peripheral gangrene as a manifestation of TB is not common. Spinal TB presents with backache, paraparesis, or quadriplegia with or without bladder and bowel involvement. It may cause spinal deformities. However, peripheral gangrene is not a common manifestation of spinal TB. Here, we present the case of spinal TB, with peripheral gangrene in a 30-year-old female. There was blackening and shrinkage of the left third toe, with superficial tenderness, darkening, and loss of sensation over the left fourth and fifth toes. Tuberculin test and Mantoux test were positive. The magnetic resonance imaging findings were suggestive of Pott's spine. Arterial Doppler of the affected lower limb revealed sluggish flow, as suggested by the biphasic waveform. The patient was started on antituberculous treatment. Although the neurological symptoms improved with antituberculous treatment, the peripheral gangrene resolved only partially and required amputation.

**Key words:** Spinal, Tuberculosis, Vasculitis

According to the World Health Organization (WHO), the incidence of tuberculosis (TB) ranges from 9.0–11.1 million cases worldwide [1] and in India, up to 2.5 million cases [2]. Spinal TB is a common manifestation of extrapulmonary TB, accounting for 2% of all cases of TB, and 15% of extrapulmonary TB cases [3].

Gangrene is a rare feature of TB, usually involving the digits, but may also involve other parts of the body. Peripheral gangrene refers to the diminution of the blood supply, nutrient, or oxygen to the tissues/organs for a prolonged period of time causing their death. Peripheral gangrene as a manifestation of TB is very rare. The exact pathogenesis is not known. It was supposed that disseminated intravascular coagulation is responsible for approximately 85%–100% of all cases [4]. Here, we report an uncommon case of spinal TB, with acral symmetrical digital gangrene of the toes.

### CASE REPORT

A 30-year-old female patient, housewife by occupation, presented with a history of fever of low-grade and weight loss for 1 month, followed by low backache and weakness of the left lower limb for approximately one week. The weakness then involved the right lower limb, followed by the retention of urine for 1 day.


The patient also complained of pain over the toes of the left foot, along with the change of color of the left third, fourth, and fifth toes. The color of the left third toe rapidly changed to black, along with shrinkage of the toe. The fever was associated with evening rise and night sweats. There was no history of trauma, loss of appetite, disturbed sleep pattern, and daily routine activities which were normal. The patient denied any habits of smoking, alcohol, or drug abuse.

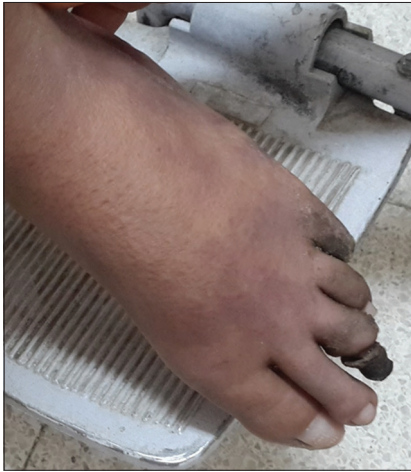On examination, the vitals were stable, but the temperature was elevated (37.5°C). The weight loss of the patient was non-significant and the body mass index (BMI) was found average (BMI-22.6). There was no pallor, cyanosis, icterus, or peripheral lymphadenopathy. There were no neurological deficits in the upper limbs. No cranial nerve deficits, higher mental function impairment, or signs of meningeal irritation were detected. Local examination revealed sacral spinal tenderness, paraparesis (muscle power grade 3/5 in both lower limbs) with diminished deep tendon reflexes (bilateral knee and ankle reflexes), and mute plantar response bilaterally. Sensory examination revealed perianal sensory loss.

There were blackening and shrinkage of the tip of the left third toe involving the nail bed and the plantar aspect of the toe. A clear demarcation was visible at the left third toe between the gangrenous and the healthy part. Along with this, there were superficial tenderness and darkening of the left fourth and fifth toes involving the nail beds (Fig. 1). There was a loss of sensation

**Correspondence to:** Masaraf Hussain, Neurology, North Eastern Indira Gandhi Regional Institute of Health and Medical Sciences, Mawdiangdiang, Shillong 79018, Meghalaya. E-mail: masarafhussain@yahoo.co.in

© 2020 The Author(s). This open access article is distributed under a Creative Commons Attribution (CC-BY) 4.0 license.

Access this article online	
Received - 22 May 2020 Initial Review - 06 June 2020 Accepted - 18 August 2020	Quick Response code 
DOI: 10.32677/IJCR.2020.v06.i08.017	



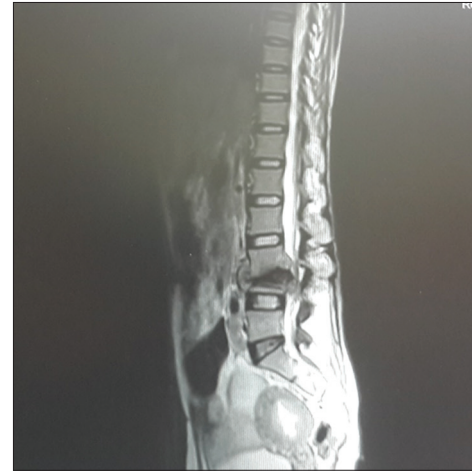
**Figure 1: Dry gangrene of the left third toe involving the nail bed and the plantar aspect of the foot and darkening of the left fourth and fifth toes involving the nail beds**

with the left third toe, and the temperature of her left foot was lower than that of the right one. The radial, brachial, femoral, and dorsalis pedis pulses were palpable. Other systemic abnormalities or positive findings were not found on physical examination. As the patient had a complaint of backache, the local examination of the spine was done, but it did not show any curvature or deformity, and the skin overlying the spine was normal.

Blood investigations revealed hemoglobin of 9.0gm/dl, erythrocyte sedimentation rate was 57 mm 1<sup>st</sup> h, international normalized ratio was 2.3, and accelerated partial thromboplastin time was 40 s. The blood sugar, liver function test, renal function test, and lipid profile were normal. Mantoux test with 5 tuberculin unit purified protein derivative was strongly positive. The chest X-ray did not show any abnormality. Serological markers for hepatitis B and C, human immunodeficiency virus, cytomegalovirus, and Epstein Barr virus were all negative. C-reactive protein was 15.2 mg/dl. The anti-cyclic citrullinated peptide, aANA, anti-ds-DNA antibody, and ANCA were negative.

Magnetic resonance imaging (MRI) spine revealed irregularity of both the vertebral endplate and anterior aspect of vertebral bodies, with bone marrow edema and enhancement. There was T1 hypointense marrow in the adjacent vertebra, with T2 hyperintense marrow and disc. There was a Gadolinium enhancement of marrow, disc, and dura (Fig. 2). The MRI findings were suggestive of Pott's spine. Arterial Doppler of the left lower limb revealed sluggish flow, as suggested by the biphasic waveform and the other lower limb was normal. On the basis of clinical examination and MRI findings, a final diagnosis of dry gangrene of the digits, along with spinal TB, was made.

The patient was started on antituberculous treatment in accordance with the Revised National TB Control Program-III. Regarding dry gangrene involving the left third, fourth, and fifth toes, a surgical consultation was taken and they advised for amputation of the left third toe. Amputation of the left third toe was done. Histopathology of the amputated toe revealed coagulative necrosis. A follow-up of the patient at the 3<sup>rd</sup>-month showed improvement in the symptoms of digital gangrene of the



**Figure 2: Magnetic resonance imaging spine showing irregularity of both the vertebral endplate and anterior aspect of vertebral bodies, with bone marrow edema and enhancement**

fourth and fifth toes and the skin returned to normal color for both toes.

## DISCUSSION

Acral symmetrical digital gangrene was first reported by Hutchison in 1891 [5]. The manifestation of digital gangrene in TB has always been rare, and the explanation for it is still not clear. The etiology of peripheral gangrene is multifactorial; however, in general, it has been divided into two main categories which are infective factors and non-infective factors [6]. In the present case, the etiology was found to be spinal TB and her gangrene resulted in secondary to TB.

Some case reports have described gangrene secondary to TB due to vasculitis [7]. Vasculitis is a clinicopathologic process characterized by blood vessel wall inflammation, which can be primary or secondary to other systemic diseases. One report has suggested that the digital gangrene in TB may result from vasospasm or small vessel obstruction [8]. Vasculitis secondary to TB was first described by Parish and Rhodes in 1967 [9]. TB is known to cause large vessel vasculitis. It has been suggested that *Mycobacterium tuberculosis* acts as a chronic stimulus for an immunogenic reaction causing vasculitis, leading to thickening of vessel wall and stenosis of the vessels [10]. TB has also been associated with small vessel vasculitis, such as leukocytoclastic vasculitis. However, there is only one report of medium vessel vasculitis caused by TB [7].

All cases of digital gangrene due to TB cannot be explained by vasculitis. Digital gangrene with palpable pulses may be explained by hyperaggregation of platelets, or due to hemodynamic instability [7]. Abnormalities of platelets and platelet function have been described in dry gangrene [11]. Embolization of arterioles by tubercle bacilli may also cause digital gangrene. The peripheral gangrene of the toes in our patient was probably due to hyperaggregation of platelets, as the peripheral pulses were palpable. The presence of palpable pulses suggests the absence of vasculitis. A case of diffuse ischemic limb gangrene with palpable pulses in a patient with septic shock was reported by Gill *et al.* [12].

Similar to our case, Bansal and Tyagi presented a case of digital gangrene in disseminated TB in a 35-year-old male [13]. Another case of symmetrical peripheral gangrene was presented by Patial *et al.* in a 46-year-old man, who initially presented with signs and symptoms suggestive of TB but later developed symmetrical peripheral gangrene along with septic shock [14]. Itin *et al.* described symmetrical peripheral gangrene in a patient with disseminated TB [15]. Gangrene secondary to TB has been reported at various sites of the body such as scrotum, penis, small intestines, and retina [16-18]. Other causes of gangrene should also be excluded by appropriate clinical examination and laboratory investigations. Treatment of digital gangrene in TB generally consists of antituberculous therapy. Several agents, such as aspirin, vasodilators, tissue plasminogen activator [19], have been suggested. A study has shown the successful treatment of peripheral symmetrical gangrene with epoprostenol and tissue plasminogen activator [19]. However, another study found the above modalities of treatment unsatisfactory [5]. Amputation and debridement may also be required if the gangrene is advanced.

## CONCLUSION

TB has varied presentations. In an endemic region, even rare presentations like digital gangrene can be seen, which if treated appropriately shows recovery. However, at times, surgical amputation may be required for the gangrenous part.

## REFERENCES

- World Health Organization and Global Fund Sign Cooperation Agreement. Strategic Initiative to Reach Missed TB Cases a Critical Component of Grant. Geneva: World Health Organization; 2019. Available from: [https://www.who.int/tb/features\\_archive/WHO\\_Global\\_Fund\\_agreement/en](https://www.who.int/tb/features_archive/WHO_Global_Fund_agreement/en). [Last accessed on 2020 Aug 16].
- World Health Organization. Global Tuberculosis Control 2015. Geneva: World Health Organization; 2015. Available from: [http://www.who.int/tb/publications/global\\_report](http://www.who.int/tb/publications/global_report). [Last accessed on 2020 Mar 15].
- Chen CH, Chen YM, Lee CW, Chang YJ, Cheng CY, Hung JK. Early diagnosis of spinal tuberculosis. *J Formos Med Assoc* 2016;115:825-36.
- Ghosh SK, Bandyopadhyay D. Symmetrical peripheral gangrene. *Indian J Dermatol Venereol Leprol* 2011;77:244-8.
- Hutchinson J. Notes of uncommon cases. *Br Med J* 1891;2:8-9.
- Lerolle N, Carlotti A, Melican K, Aubey F, Pierrot M, Diehl JL, *et al.* Assessment of the interplay between blood and skin vascular abnormalities in adult purpura fulminans. *Am J Respir Crit Care Med* 2013;188:684-92.
- Yao Y, Liu B, Wang JB, Li H, Liang HD. Tuberculosis should not be ignored in patients with peripheral gangrene. *J Vasc Surg* 2010;52:1662-4.
- Prashant K, Girdhar KK, Raktima A. Symmetrical peripheral gangrene: Multifactorial association. A case report. *Indian Anesth Forum* 2006;1:1-4.
- Parish WE, Rhodes EL. Bacterial antigens and aggregated gamma globulin in the lesions of nodular vasculitis. *Br J Dermatol* 1967;79:131-47.
- Stratta P, Messuerotti A, Canavese C, Coen M, Luccoli L, Bussolati B, *et al.* The role of metals in autoimmune vasculitis: Epidemiological and pathogenic study. *Sci Total Environ* 2001;270:179-90.
- Preston FE, Emmanuel IG, Winfield DA, Malia RG. Essential thrombocythaemia and peripheral gangrene. *Br Med J* 1974;3:548-52.
- Gill D, Mann K, Kaur S, Ruiz VG, Dean R, Zaidi S. A case of diffuse ischemic limb gangrene with palpable pulses in a patient with septic shock. *Arch Med* 2017;9:1.
- Bansal N, Tyagi VK. Digital gangrene in disseminated tuberculosis: A rare presentation. *IOSR J Dent Med Sci* 2017;16:51-3.
- Patial T, Sharma K, Jaswal AS, Thakur V, Negi S. Symmetrical peripheral gangrene and tuberculosis: A rare kinship. *Int J Mycobacteriol* 2017;6:407-9.
- Itin P, Stalder H, Vischer W. Symmetrical peripheral gangrene in disseminated tuberculosis. *Dermatologica* 1986;173:189-95.
- Huriez C, Dupont A, Bergoend H, Thomas P, Douay B. Tuberculous gangrene of the penis. *Bull Soc Fr Dermatol Syphiligr* 1979;1:91-2.
- Derevianko IM. Gangrene of the scrotum of tubercular etiology. *Urol Nefrol (Mosk)* 1993;5:41-2.
- Telkov NA. Gangrene of small intestines in tuberculosis of mesenteric glands. *Probl Tuberk* 1950;4:66-8.
- Denning DW, Gilliland L, Hewlett A, Hughes LO, Reid CD. Peripheral symmetrical gangrene successfully treated with epoprostenol and tissue plasminogen activator. *Lancet* 1986;2:1401-2.

*Funding: None; Conflicts of Interest: None Stated.*

**How to cite this article:** Hussain M, Sharma S, Synmon B, Hynniewta Y. Digital gangrene in spinal tuberculosis. *Indian J Case Reports*. 2020;6(8):471-473.