

## A case of hybrid verrucous carcinoma with lymph node metastasis: A rare case report

Anjali Sharma<sup>1</sup>, Deshant Agarwal<sup>2</sup>, Praveena Vyas<sup>3</sup>

From <sup>1</sup>Head, <sup>2</sup>Additional Consultant, <sup>3</sup>Senior Resident, Department of Pathology, Bhagwan Mahaveer Cancer Hospital and Research Centre, Jaipur, Rajasthan, India

### ABSTRACT

Verrucous carcinoma (VC) constitutes around 2–16% of total oral carcinomas. It tends to recur; however, lymph node metastasis is a rare finding. There are around 20% of VC cases associated with dysplasia/minimal invasion. Different names were used by many authors for those in-between varieties of VC. The clinical data, biological behavior, and histopathological features for that in-between variety of VC are not clearly defined. The previous case reports of VC with lymph node metastasis were attributed to the presence of dysplasia/minimal invasive component, along with pure VC. In this case report, we discuss pure VC and in-between varieties of VC. A universal name should be used for those lesions and should be incorporated in the World Health Organization classification. Careful examination of VC biopsy is mandatory to rule out any focal area of dysplasia/microinvasion as they suggest the probability of nodal metastasis.

**Key words:** Dysplasia, Hybrid verrucous carcinoma, Invasion

Verrucous carcinoma (VC) was first described by Ackerman in 1948. It forms almost 2–12% of all oral malignancies. By strict definition, VC lacks dysplastic cytological features [1]. Few cases of VC were reported associated with dysplasia/minimal invasion and regarded as “in-between” variety of VC. Since there is not enough literature regarding this entity, their clinical, histopathological, and prognostic behavior are unclear [2]. Here, we report a case of “in-between” variety of VC, along with its clinical, pathological, and management aspects.

### CASE REPORT

A 73-year-old male patient came to our hospital in May 2018 with a chief complaint of painless growth at the right side of the lower gums.


On clinical examination, vitals and general examination were normal at presentation. On local examination, a whitish exophytic sessile growth of size 3.8 cm × 3.5 cm and with well-defined margins was identified on the right lower alveolus. The growth was extending up to the right buccal mucosa. No lymphadenopathy was palpable. Thus, a provisional diagnosis of VC was made and a differential diagnoses of squamous papilloma, focal epithelial

hyperplasia, squamous cell carcinoma (SCC), and condyloma acuminatum were considered.

Pre-operative computed tomography scan showed an ill-defined thickening with contrast enhancement of the right lower gingiva-buccal sulcus (GBS) of size 23 mm × 11 mm × 17 mm, which was extending into the masticatory space. No bony erosion was detected. Ultrasonography of the neck shows few enlarged right cervical lymph nodes in the right submandibular region, of which the largest lymph node was of 20.6 mm × 8.7 mm size. The fatty hilum of the lymph node was maintained.

A punch biopsy was performed, which was suggestive of VC. Wide local excision of the lesion with segmental mandibulectomy, along with supraomohyoid neck dissection (SOHND), was planned. Grossly, a whitish verrucopapillary growth of size 3.8 cm × 3.5 cm × 1.5 cm was identified on the right lower GBS extending up to the right buccal mucosa (Fig. 1). About, 22 lymph nodes were harvested from the SOHND specimen.

Histopathological examination revealed hyperkeratotic hyperplastic squamous epithelium with broad rete ridges, showing both exophytic and endophytic components with mild dysplasia. At one focal area, a cluster of angulated, pleomorphic epithelial cells with high nuclear-cytoplasmic ratio, and abnormal mitosis seen in the subepithelial tissue and the depth

Access this article online	
Received - 10 June 2020 Initial Review - 26 June 2020 Accepted - 11 July 2020	Quick Response code 
DOI: 10.32677/IJCR.2020.v06.i07.014	

**Correspondence to:** Dr. Deshant Agarwal, Department of Pathology, Bhagwan Mahaveer Cancer Hospital and Research Centre, Jln Marg, Jaipur - 302 017. E-mail: deshaant@gmail.com

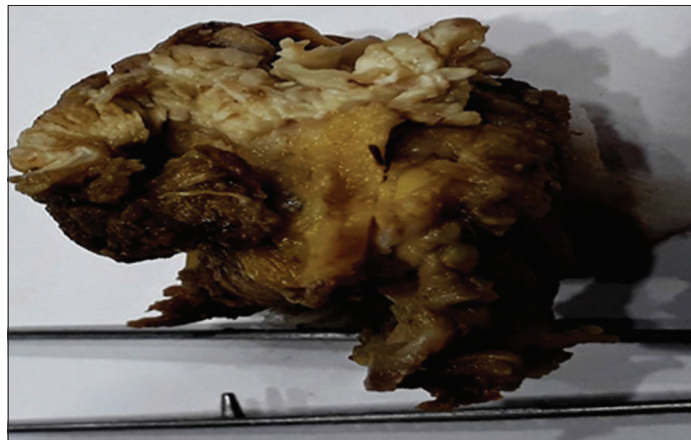© 2020 The Author(s). This open access article is distributed under a Creative Commons Attribution (CC-BY) 4.0 license.

of invasion was less than 1 mm. A focal area of squamous epithelium showed koilocytic changes (Fig. 2a and 2b). Since only a few dysplastic epithelial clusters were seen in the subepithelial tissue, it was difficult to label it as SCC. The slides were re-evaluated intradepartmental by three pathologists, and a diagnosis of VC with dysplasia and minimal invasion was suggested.

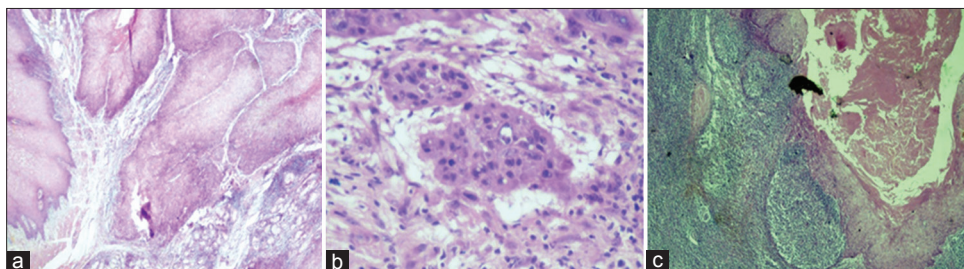
All the mucosal and soft-tissue margins were assessed and found to be unremarkable. Underlying bone was not infiltrated by tumor. Out of 22 lymph nodes, interestingly, one lymph node showed metastasis, whereas other lymph nodes showed reactive hyperplasia. Moreover, the metastatic component in the lymph node showed only minimal cytological atypia (Fig. 2c). Since VC was associated with multiple recurrences, our patient was on regular follow-up for a year, and no recurrence was reported.

## DISCUSSION

VC was first described by Ackerman in 1948 [1]. Association of VC with dysplasia/minimal invasion was studied by several authors. Medina *et al.*, in 1984, studied 104 cases of VC and reported that 20% of VC is associated with less differentiated SCC, and the local recurrence was slightly higher than pure VC, but none of those tumors had nodal metastasis [2]. Batsakis and Suarez in the year 2000 coined a term hybrid VC for those in which pure VC associated synchronously with



**Figure 1:** Gross appearance of verrucous carcinoma of the buccal mucosa



**Figure 2:** Histopathological image shows (a) broad pushing rete ridges invading into stroma with the presence of koilocytes; (b) irregular nest of tumor with angulated edges and dysplastic epithelial cells; (c) verrucous carcinoma metastasizing in the lymph node (H and E stain  $\times 10$ )

non-verrucous SCC component [3]. Various terminologies were used for these “in-between” varieties of VC such as VC with focal dysplasia, VC with invasion, VC with SCC, SCC with verrucous features, and the focus of SCC with VC and hybrid VC [4,5]. Patel *et al.*, in their study, showed that hybrid VC has a 2–3 times higher recurrence rate than pure VC, but none of their cases develop nodal metastasis [6]. Rekha and Angadi studied 133 VC patients from India and showed that VC with dysplasia/minimal invasion does not show any regional LN positivity [7].

Lymph node metastasis in VC is a very rare finding. Recently, Mohammadi *et al.* reviewed 58 cases of VC and found two cases with lymph node metastasis without extranodal extension. Few other case reports of VC with lymph node metastasis were also reported. However, on re-evaluation, all cases showed the presence of dysplasia/minimal invasion [8,9].

Here, we have reported a case of VC showing dysplasia and minimal invasion with lymph node metastasis. This case helped us to understand this new “in-between” variety of VC and strengthens the belief that pure VC never metastasize to the regional lymph node unless it is associated with dysplasia/minimal invasion.

Thorough sampling and careful examination of VC are mandatory to rule out any dysplasia or minimal invasive component. To date, this category is not included in the World Health Organization classification. More studies related to hybrid VC may lead to a better understanding of these lesions and may put it into a separate category in the future. This case also highlights the controversies regarding the name for those lesions as well as it also helped us to understand the biological behavior of hybrid VC.

The vast majority of VC cases are treated by surgery alone. Older literature raised the issue of radiotherapy related anaplastic/malignant transformation in VC [4,10,11]; however, RT now considered an acceptable tool for inoperable VC patients.

The current common practice for VC with dysplasia or minimal invasion is to treat them as conventional SCC [12]. Patel *et al.* suggested that treating VC with dysplasia/minimal invasion as conventional SCC may result in overtreatment [6]. However, omitting neck dissection in hybrid VC may result in the residual metastatic lesions in the regional lymph nodes. Future studies are necessary to investigate and set a guideline to treat those patients.

**CONCLUSION**

All VC cases should be thoroughly sampled and carefully studied for dysplasia/minimal invasion, as these features suggest the probability of nodal metastasis. We recommend a separate and uniform terminology with proper histopathological guidelines for those lesions so that its clinical behavior, histopathological features, prognosis, and treatment plan would be established.

**REFERENCES**

- Ackerman LV. Verrucous carcinoma of the oral cavity. *Surgery* 1948;23:670-8.
- Medina JE, Dichtel W, Luna MA. Verrucous-squamous carcinomas of the oral cavity: A clinicopathologic study of 104 cases. *Arch Otolaryngol* 1984;110:437-40.
- Batsakis JG, Suarez P. Papillary squamous carcinoma: Will the real one please stand up? *Adv Anat Pathol* 2000;7:2-8.
- Fonts EA, Greenlaw RH, Rush BF, Rovin S. Verrucous squamous cell carcinoma of the oral cavity. *Cancer* 1969;23:152-60.
- Orvidas LJ, Olsen KD, Lewis JE, Suman VJ. Verrucous carcinoma of the larynx: A review of 53 patients. *Head Neck* 1998;20:197-203.
- Patel KR, Chernock RD, Sinha P, Müller S, El-Mofty SK, Lewis JS Jr. Verrucous carcinoma with dysplasia or minimal invasion: A variant of verrucous carcinoma with extremely favorable prognosis. *Head Neck Pathol* 2015;9:65-73.
- Rekha KP, Angadi PV. Verrucous carcinoma of the oral cavity: A clinicopathologic appraisal of 133 cases in Indians. *Oral Maxillofac Surg* 2010;14:2118.
- Mohammadi W, Mohiyuddin SM, Harshitha N, Suresh TN, Prasad CS, Sagayaraj A, *et al.* Outcome of treatment in verrucous carcinoma of oral cavity: A tertiary rural hospital experience. *Indian J Otolaryngol Head Neck Surg* 2020;15:1671.
- Walvekar R, Chaukar DA, Deshpande MS, Pai PS, Chaturvedi P, Kakade A, *et al.* Verrucous carcinoma of the oral cavity: A clinical and pathological study of 101 cases. *Oral Oncol* 2009;45:47-51.
- Kraus FT, Perezmesa C. Verrucous carcinoma. Clinical and pathologic study of 105 Cases involving oral cavity, larynx and genitalia. *Cancer* 1966;19:26-38.
- Perez CA, Kraus FT, Evans JC, Powers WE. Anaplastic transformation in verrucous carcinoma of the oral cavity after radiation therapy. *Radiology* 1966;86:108-15.
- Kolokythas A, Rogers TM, Miloro M. Hybrid verrucous squamous carcinoma of the oral cavity: Treatment considerations based on a critical review of the literature. *J Oral Maxillofac Surg* 2010;68:2320-4.

*Funding: None; Conflicts of Interest: None Stated.*

**How to cite this article:** Sharma A, Agarwal D, Vyas P. A case of hybrid verrucous carcinoma with lymph node metastasis: A rare case report. *Indian J Case Reports*. 2020;6(7):393-395.