

Unilateral renal agenesis and proximal blind-ending ureter with ureteric atresia

Krishnendu Maity¹, Ritesh Satardey², Dilip Kumar Pal³

From ¹Associate Professor, ²Post Doctoral Trainee, ³Professor and Head, Department of Urology, Institute of Post Graduate Medical education and Research, Kolkata, West Bengal, India

Correspondence to: Dilip Kumar Pal, Department Of Urology, Institute of Post Graduate Medical education and Research, 244, Acharya Jagdish Chandra Bose Road, Bhowanipore, Kolkata, West Bengal, India. E-mail: urologyipgmer@gmail.com

Received - 12 May 2020

Initial Review - 28 May 2020

Accepted - 12 June 2020

ABSTRACT

Renal agenesis associated with proximal blind-ending ureter, ureteric atresia, and fusiform dilatation of distal ureter which is an extremely rare occurrence and has not been described in the literature. We report a case of unilateral renal agenesis and ipsilateral proximal blind-ending ureter with ureteric atresia in an 11-year-old boy which was dealt surgically with good outcomes.

Key words: Renal agenesis, Renal involution, Ureteric atresia

Renal agenesis generally results from the lack of induction of the metanephric blastema by the ureteral bud, which may be secondary to ureteral bud maldevelopment and/or due to a problem with the formation of the mesonephric duct [1]. Unilateral renal agenesis is usually an incidental finding with the contralateral kidney demonstrating compensatory hypertrophy [1]. Ureteral atresia is a rare congenital abnormality usually associated with a dysplastic non-functioning kidney [2]. It is hypothesized that it could be caused by a failure of canalization of a segment of the ureter during the process of development and elongation of the ureteric bud.

The production of urine starts at 9 weeks of development when the ureter joins the urogenital sinus which is still obstructed by the Chwalla's membrane. This membrane decreases during approximately the 37th–47th days of pregnancy [3,4]. Our case is a combination of unilateral renal agenesis, proximal blind-ended ureter, and ureteric atresia with fusiform dilatation of distal ureter which has not been reported in the literature to the best of our knowledge.

CASE REPORT

An 11-year-old male child presented with complaints of pain in the abdomen, on and off, for the past 6 years with gradually increasing frequency of micturition. He was being treated in his home town for the same. On examination, the patient was vitally stable. Per abdomen examination revealed a soft, non-tender abdomen with no palpable lump. The genital examination was within normal limits.

On ultrasonography, he was found to have a solitary right kidney with suspected bladder diverticula. He had normal hematocrit with normal renal biochemical parameters. Micturating cystourethrogram suggested a bladder diverticulum. Uroflowmetry was within normal limits. Contrast-computed

tomography showed absent left kidney, with a normal right kidney, dilated tubular thin-walled structure at left side pelvis (70 cm×60 cm×40 mm in size), between urinary bladder and rectum, without any demonstrable communication with urinary bladder (Fig. 1).

Dimercaptosuccinic acid scan failed to demonstrate the presence of the left kidney with a normal functioning right kidney. Magnetic resonance imaging of the abdomen and pelvis was suspicious of bladder diverticulum, with seminal vesicles in normal position. Communication between urinary bladder and cyst could not be ruled out with certainty (Fig. 2). Cystoscopy revealed normal urethra, normal bladder neck, normal trigone, and a patent normally placed right ureteric orifice. The left ureteric orifice was absent, instead, dimpling at the site was seen (Fig. 3). No evidence of any diverticular opening in bladder on cystoscopy.

On laparoscopy, a 6 cm×4 cm cystic structure was seen at the left side of the base of the bladder. It was found to be a cystic structure in continuation of the distal left ureter. On further dissection, the proximal blind end of the left ureter was found. The left kidney was absent. Vas deference and seminal vesicles were present bilaterally at the normal anatomical positions. The cystic structure was resected from the bladder wall. On examination of the specimen, the proximal ureter was found to be devoid of canalization. The procedure and post-operative course were uneventful. The patient was advised to avoid nephrotoxic drugs and stay well hydrated. On follow-up till 3 months, the patient is doing well.

DISCUSSION

Renal agenesis is not an uncommon entity, but unilateral renal agenesis with proximal blind-ending ureter and ureteric atresia with fusiform dilatation of the distal ureter is extremely rare

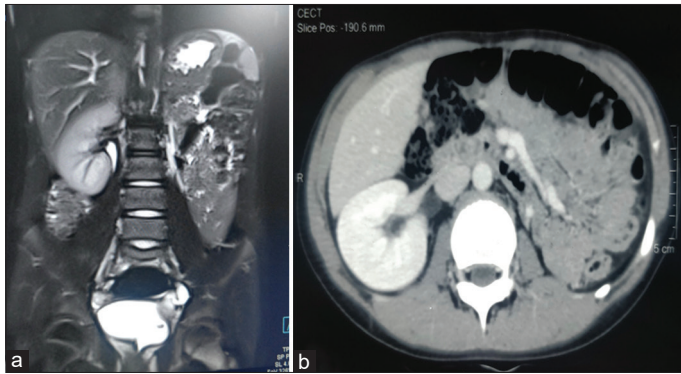


Figure 1: (a) Left ureteric cyst indenting on the urinary bladder; (b) Absent left kidney and normal seminal vesicles

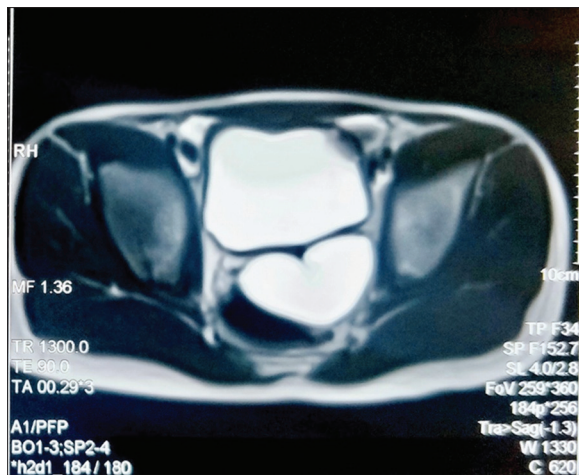


Figure 2: Ureteric cyst adjacent to the urinary bladder

and has not been so far reported in the literature. Unilateral renal agenesis may be associated with ipsilateral genitourinary anomalies [5]. Few cases with unilateral renal agenesis with ipsilateral ureterocoele, megaureter, and blind-ending proximal ureter in the same patient have been described [6,7]. Unilateral renal agenesis can also be associated with other urologic abnormalities in 48% of patients, including primary vesicoureteral reflux (28%), obstructive megaureter (11%), and ureteropelvic junction obstruction (3%) [8].

The interest of this case lies in the association of unilateral renal agenesis with ipsilateral ureteric atresia, distal fusiform dilated ureter, and blind-ended ipsilateral proximal ureter. The presentation of this patient was increased frequency of micturition with pain in the abdomen, but no lump was palpable. It is necessary to carry out an early investigation in these kinds of cases as the operative intervention will cure patient's symptoms and help the early realization of single kidney status and avoid future infection of distal cyst in the ureter as it would increase the morbidity.

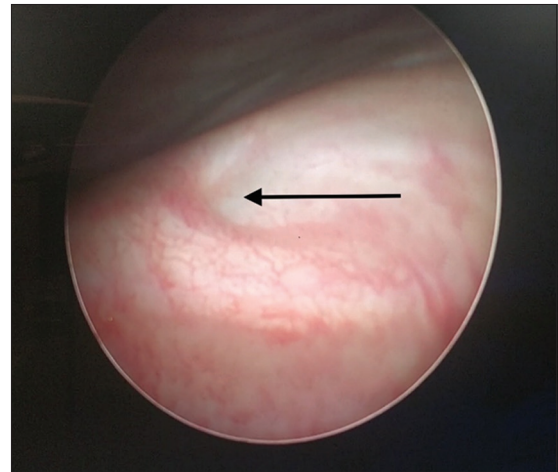


Figure 3: Dimpling at the site of the left ureteric orifice

CONCLUSION

It is important to do early investigations in patients with congenital urinary tract anomalies so as to avoid complications with delayed diagnosis and avoid increased morbidity and mortality. Our patient was treated for 6 years before performing any imaging. Early imaging would have avoided all the sequence of complications before getting definitive management.

REFERENCES

- Mishra A. Renal agenesis: Report of an interesting case. *Br J Radiol* 2007;80:e167-9.
- Alcaraz A, Vinaixa F, Tejado-Mateu A, Forés MM, Gotzens V, Mestres CA, *et al.* Obstruction and recanalization of the ureter during embryonic development. *J Urol* 1991;145:410-6.
- Coplen DE. Ureteral obstruction and malformations. In: Ashcraft KW, Holcomb GW, Murphy JP, editors. *Pediatric Surgery*. 4th ed. Philadelphia, PA: Elsevier; 2005. p. 732-79.
- Bhattacharjee PK, Ghosal S, Sharma GD. Distal ureteric atresia presenting as an abdominal lump in an adult. *Indian J Surg* 2009;66:175-7.
- Halachmi S, Pillar G. Congenital urological anomalies diagnosed in adulthood - management considerations. *J Pediatr Urol* 2008;4:2-7.
- Ahmed A. Ipsilateral renal agenesis with megaureter, blind end proximal ureter and ureterocele in an adult. *J Ayub Med Coll Abbottabad* 2017;29:150-3.
- Maas KL, Lipson SA, Hricak H. Ureteric bud remnant in two patients with renal agenesis: Diagnosis by MRI. *J Comput Assist Tomogr* 1997;21:745-7.
- Cascio S, Paran S, Prori P. Associated urological anomalies in children with unilateral renal agenesis. *J Urol* 1999;162:1081-3.

Funding: None; Conflict of Interest: None Stated.

How to cite this article: Maity K, Satardey R, Pal DK. Unilateral renal agenesis and proximal blind-ending ureter with ureteric atresia. *Indian J Case Reports*. 2020;6(6):344-345.

Doi: 10.32677/IJCR.2020.v06.i06.020