

A nail through the urethra in urinary bladder: A case report of autoerotism

Ankit Kayal¹, Sunirmal Choudhury², Tapan Kumar Mandal³, Tapas Kumar Majhi³

From ¹Consultant Urologist, Department of Urology, Chirayu Hospital, Jaipur, Rajasthan, India, ²Associate Professor, Department of Urology, Institute of Post Graduate Medical Education and Research, Kolkata, West Bengal, India, ³Professor, Department of Urology, Nil Ratan Sircar Medical College and Hospital, Kolkata, West Bengal, India

Correspondence to: Dr. Sunirmal Choudhury, Department of Urology, Institute of Post Graduate Medical Education and Research, Kolkata - 700 020, West Bengal, India. E-mail: sunir09@gmail.com

Received - 25 April 2020

Initial Review - 11 May 2020

Accepted - 23 May 2020

ABSTRACT

Autoerotic stimulation, psychosexual disorders, drug intoxication, iatrogenicity, penetrating injury, or migration from neighboring organs are common causes for an intraurethral foreign body. As per our knowledge, our patient is the first case with a self-inserted intraurethral metallic nail in prostatic urethra and bladder. A nail was found in prostatic urethra and bladder which had migrated during sexual stimulation. We successfully removed the urethral foreign body with the combined approach of percutaneous suprapubic cystostomy and cystoscopy. First-line treatment must be endoscopic manipulation, but sometimes the combined approach may be necessary. A psychiatric evaluation must be done. It can be simply avoided by psychiatric counseling to prevent its recurrence.

Key words: *Autoerotic stimulation, Intraurethral foreign body, Nail, Psychosexual disorders*

Autoerotic stimulation, psychosexual disorders, drug intoxication, iatrogenicity, penetrating injury, or migration from the neighboring organs are common causes for an intraurethral foreign body [1]. A variety of foreign bodies such as fish hooks, metal rods, hairpins, screws, pellets, wires, wooden sticks, a piece of fish, telephone cables, and headset in the urinary bladder is described in the literature [2].

As per our knowledge, our patient is the first case with a self-inserted intraurethral metallic nail in the prostatic urethra and bladder. Common presentations are dysuria, urinary retention, hematuria, suprapubic pain, external genitalia pain, and swelling.

CASE REPORT

A 26-year-old male presented to the emergency department with complaints of retention of urine, followed by urinary incontinence, blood in urine, burning micturition, and difficulty in urination for 1 day. On detailed history, he admitted that he used to insert metallic nail per urethra for sexual pleasure, but the night before presentation, it had retained inside the urethra. On general examination, vitals were stable and a general survey was alright except that there was suprapubic fullness along with tenderness.

An X-ray of the bladder region showed the nail with its tail in the prostatic urethra and cap part within the bladder (Fig. 1). As a diagnostic impression of the nail in prostatic urethra and bladder was made, a combined approach of percutaneous suprapubic cystostomy and cystoscopy was planned. As cystoscopy alone may cause urethral injury, the combined approach was preferred.

After serial dilatation up to 32 F, suprapubic access was done and Amplatz sheath inserted. The nail head was held by grasper and safely removed. The nail was 4 cm long (Figs. 2 and 3). The urethra and urinary bladder were inspected after removal of the nail to rule out any associated injury. The prostatic urethra was unhealthy, so per urethral catheter was kept for 2 weeks. On follow-up, recovery was uneventful. On psychiatric evaluation, the purpose of insertion was clearly masturbation and no evidence of the psychological disorder was found.

DISCUSSION

Most of the patients introduce foreign bodies themselves in the urethra for sexual gratification/masturbatory purpose. Various household things such as pencils, electric cables, thermometers, glass rods, toothbrushes, candles, serum sets, balloons, hairpins, wires, ampules, broken keys, plastic spoon handles, bullets, thermometers, bird feathers, chewing gum, pieces of gauze, metallic batteries, paraffin, urethral device, plastic tubes, fish, snake, and many other entities are reported in the literature [3-5].

Although the various psychiatric disorders are described in the literature associated with self-insertion of foreign bodies into the urethra, it is not always necessary. As in our case, there were no associated psychiatric disorders or drug abuse [6]. Surprisingly, foreign bodies can migrate through the bulbous urethral curvature without significant injuries [7,8]. The situation becomes more complicated and difficult to retrieve when the foreign body migrates to proximal urethra or bladder [9].

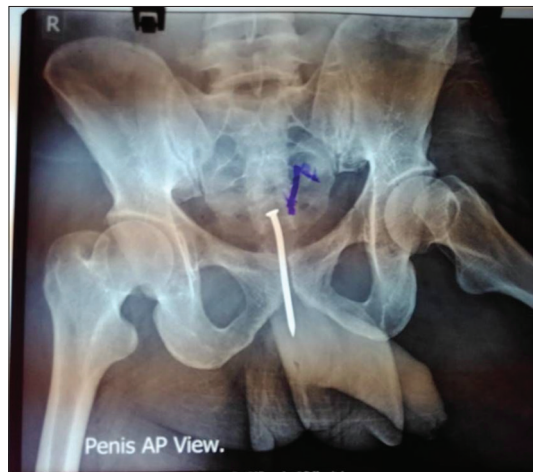


Figure 1: X-ray film with nail *in-situ*

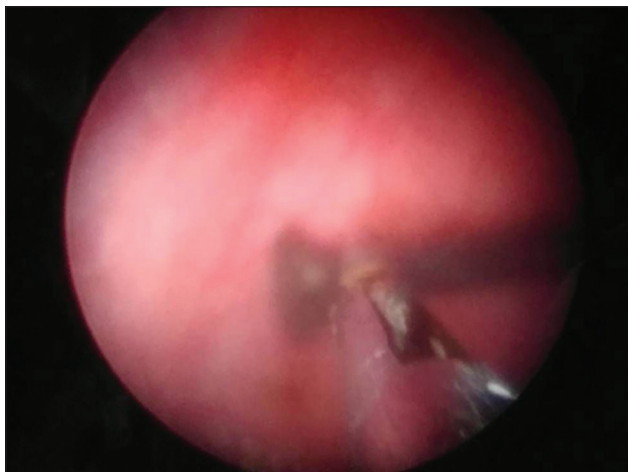


Figure 2: Endoscopy view

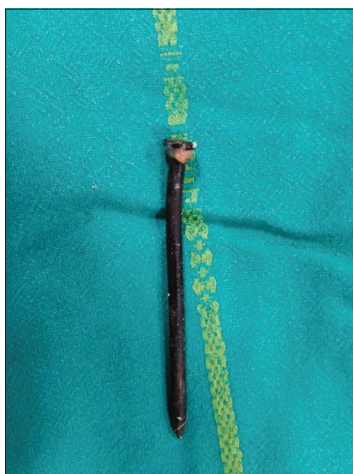


Figure 3: Nail after removal

Although in our case, the presentation was early but in most of the cases, it is delayed due to social stigma. These foreign bodies have various presentations such as lower abdominal pain, dysuria, urethral discomfort, pollakiuria, hematuria, gross bleeding from the urethra, painful erection, difficulty in voiding, and urinary retention. In long-term conditions, it may give rise to repeated infections, chronic urinary retention, urethral stenosis, urethral

diverticula, periurethral abscess and/or fistula, calcification of foreign bodies, squamous cell carcinoma, etc. [10].

The presence of a foreign body in the lower urinary tract is easily suspected on the basis of the history itself, and physical examination like palpation, in case, the object is in the urethra. Radiologic evaluation helps in knowing the exact size, number, and location of foreign bodies. The objects are preferably extracted by minimal invasive surgery or by cystostomy when cystoscopy fails [11].

In our case, after a proper suggestive history of the foreign body, the prostatic urethra and bladder foreign body were confirmed with the help of an X-ray. We successfully removed the urethral foreign body with the combined approach of percutaneous suprapubic cystostomy (PCCL) and cystoscopy. There was also a similar case report on the literature search [12].

CONCLUSION

A self-inserted foreign body in the urethra is not a frequent situation, but it should be treated early. First-line treatment must be endoscopic manipulation, but sometimes the combined approach may be necessary. A psychiatric evaluation must be done. It can be simply avoided by psychiatric counseling to prevent its recurrence.

REFERENCES

- Ahmed MH, Pawar PW, Sawant AS, Sakharani J, Arora A, Patil SR, *et al.* Foreign body in urinary bladder: Our experience and review of literature. *Int Surg J* 2019;6:4327-31.
- Chowdhury S, Pal DK. Listening to music from the urinary bladder! Case report of a headset in a urinary bladder. *Int J Adolesc Med Health* 2016;30. doi: 10.1515/ijamh-2016-0058.
- Bansal A, Yadav P, Kumar M, Sankhwar S, Purkait B, Jhanwar A, *et al.* Foreign bodies in the urinary bladder and their management: A single-centre experience from North India. *Int Neurourol J* 2016;20:260.
- Rahman NU, Elliott SP, McAninch JW. Self-inflicted male urethral foreignbody insertion: Endoscopic management and complications. *BJU Int* 2004;94:1051-3.
- Mannan A, Anwar S, Qayyum A, Tasneem RA. Foreign bodies in the urinarybladder and their management: A Pakistani experience. *Singapore Med J* 2011;52:24-8.
- Kenney RD. Adolescent males who insert genitourinary foreign bodies: Ispychiatric referral required? *Urology* 1988;32:127-9.
- Ku JH, Lee CS, Jeon YS, Kim ME, Lee NK. A foreign body in the urethra: A case report. *Korean J Urol* 1997;38:219-21.
- Moon SJ, Kim DH, Chung JH, Jo JK, Son YW, Choi HY, *et al.* Unusual foreign bodies in the urinary bladder and urethra due to autoerotism. *Int Neurourol J* 2010;14:186-9.
- Jung TY, Choi NG. 14 cases of foreign bodies in the bladder. *Korean J Urol* 1997;38:76-80.
- Johnin K, Kushima M, Koizumi S, Okada Y. Percutaneous transvesical retrievalof foreign bodies penetrating the urethra. *J Urol* 1999;161:915-6.
- Amiroune D, Bouchikhi AA, Adawi F. Retained self-inserted foreign body into the urethra associated with sequela urethral stenosis: A case report. *J Med Case Rep* 2014;8:244.
- Moslemi MK, Sorani M. Self-inflicted male bladder foreign body: Its endoscopic removal using a rigid cystoscope and a suprapubic forceps. *Case Rep Urol* 2013;2013:729013.

Funding: None; Conflict of Interest: None Stated.

How to cite this article: Kayal A, Choudhury S, Mandal TK, Majhi TK. A nail through the urethra in urinary bladder: A case report of autoerotism. *Indian J Case Reports*. 2020;6(6):305-306.

Doi: 10.32677/IJCR.2020.v06.i06.006