

Lumbosacral plexopathy – An unusual presentation of sciatic endometriosis

Monika Singla¹, Parth Bansal², Kamini Gupta³, Saurav Aggarwal⁴

From ¹Associate Professor, ²Resident, Department of Neurology, ³Professor, Department of Radiology, Dayanand Medical College and Hospital, ⁴Consultant, Department of Neurology, Oswal Hospital, Ludhiana, Punjab, India

Correspondence to: Monika Singla, Department of Neurology, Dayanand Medical College and Hospital, Ludhiana - 141 012, Punjab, India. E-mail: drmonika78@yahoo.com

Received - 18 April 2020

Initial Review - 06 May 2020

Accepted - 12 May 2020

ABSTRACT

Endometriosis is a common gynecologic disorder that presents with chronic pelvic pain or infertility. It is the presence of endometrial tissue outside the uterus. It is typically present in the pelvis, such as on the ovaries and pelvic peritoneum. It may also involve the bowel, ureter or bladder, and the neurovascular bundle in the leg. We, hereby, report that the case of a lady who presented to us with catamenial leg pain on her right side was diagnosed to have lumbosacral plexopathy with underlying etiology as endometriosis on evaluation, an unusual presentation of a disease.

Key words: Cyclical pain, Endometriosis, Lumbosacral plexus, Sciatic nerve

Endometriosis, besides involving uterus, has many extrapelvic manifestations. Although considered to be a common gynecological disorder, the etiology of the disease is not fully elucidated. Out of the many theories put forward over the years, only two have retained significance. According to the theory of coelomic epithelium metaplasia, endometriosis originates in peritoneal endothelium which, in turn, is derived from the coelomic epithelium. The cause of such metaplasia might be increased estrogen levels, in the presence of which mesenchymal elements, either covered or not by epithelium layer, turn itself into endometrium or inflammation (embryonal coelomic cells are supposed to turn into endometrium under the impact of inflammatory phenomena).

The second theory is the theory of endometrial origin supported by two hypotheses: The “backflow” theory (retrograde menstruation) states that the endometrial fragments in menstrual blood are taken over by tubal peristalsis, into the peritoneal cavity, where they get affixed. The theory of vascular metaplasia explains the other endometrial locations: The proliferation reaching myometrial interstices may penetrate blood and lymph vessels causing real endometrial embolism in any tissue or organ of the body [1,2].

Extrapelvic endometriosis has been reported in many areas, such as the sciatic nerve and lung. The other sites of extragenital endometriosis are the gastrointestinal tract, with the predominance of the sigmoid colon and rectosigmoid. Small intestine endometriosis is less commonly seen, in 1–7% of patients, affecting appendix or the ileum under Meckel diverticulum [3]. Another site is the urinary tract presenting with cystalgia, cyclical hematuria, dysuria, cystitis, and hematuria. Thoracic endometriosis cases have also been reported to involve either the

parenchyma or the pleura. Rare cases of sciatic nerve involvement have been reported, a nerve being encased by endometrial zones extending deeply under ligaments, accompanied by cyclical sciatica linked to the menstrual phase [4,5].

We report a case of a young female who presented to us with cyclical pain in her right leg, with diffuse involvement and wasting of leg muscles suggestive of the involvement of lumbosacral plexus beyond sciatic nerve.

CASE REPORT

A 33-year-old female was referred to the neurology department for pain in her right leg, which was present for the past 1 year. It was present in her lower back and in the right thigh which radiates down to her right foot. The pain was spasmodic in nature and very severe in intensity. She was consuming many analgesics, non-steroidal anti-inflammatory drugs, antispasmodics, and sometimes opioid agonists for the same, but not relieved. The pain used to increase with exertion and had no particular relation to coughing, sneezing, or straining.

Initially, the pain used to last for a few days in a month centered on her menstrual phase, but over a year, it had increased in intensity and duration and outlasted her menstrual phase also. For the last few months, she started having difficulty in walking due to inability to lift her right foot off the floor and had to raise her right leg higher up to clear the foot off the floor, but since the last few months, she started dragging the right foot due to inability to lift her right thigh high up. She also had difficulty in flexing the right leg to her thigh in lying down position and moving her right foot up and down. She complained of decreased muscle mass of her right thigh and the right leg for the past 2–3

months and had significant wasting. Her manner of walking had also changed, and she started to waddle for the past 1–2 months.

She had complaints of sensory impairment in the form of decreased touch sensation on the back of the right thigh and leg and lateral side of the right calf and the right foot. She had no complaints with her left leg or either arm and had no urinary trouble in the past 1 year. She had no fasciculations in her right leg. She had no fracture or operative intervention, with no history of intramuscular injection in her right thigh. Her menstrual history was also unremarkable with no history of polymenorrhea or menorrhagia. Her obstetrical history was uneventful, and she had two children delivered by cesarean section aged 11 and 7 years.

She was evaluated in detail, her neurological examination confirmed the wasting of the right gluteal, thigh, and leg muscles, and no fasciculations were noticed. She had the right foot drop and weakness of the hip abductors, abductors, thigh flexors, extensors, knee flexors, extensors and foot dorsiflexors, evertors, and the invertors. She had sensory impairment in the distribution of posterior cutaneous nerve of the thigh, lateral cutaneous nerve of the thigh, and the superficial and deep peroneal nerves. Neurophysiology revealed the decreased amplitude in the right femoral, tibial motor, superficial, and deep peroneal nerves.

Electromyography (EMG) examination revealed fibrillation potential in tibialis anterior, vastus lateralis, biceps femoris, and the gluteal suggesting the lesion higher up in the neuraxis at the level of plexus or the roots. Paraspinal muscle EMG was normal confirming the lesion to be in the lumbosacral plexus. Since she had typical cyclical pain in the thigh and the leg, the possibility of some hormone responsive lesion was kept. The patient underwent radiological investigation, including computed tomography (CT) of the pelvis (Figs. 1 and 2).

Laparoscopy was done; dense adhesions were present between the omentum and the anterior abdominal wall. The left ovary was congested and the large cyst was drained and cystectomy was done. Later, the cyst wall revealed the presence of endometrium with corpus albicans. The right ovary was also congested and adhered to the posterior uterine wall. The uterine surface had endometriotic patches. The findings were consistent with the diagnosis of endometriosis. The patient was given oral contraceptives, including both estrogen and progestin hormones. She initially responded to the treatment, and overtime, her pain decreased. Later, she had to undergo surgery, as her symptoms were recurring. Recently, she was started on gonadotropin-releasing hormone antagonist.

DISCUSSION

The first case of endometriosis-induced sciatica was reported by Schlicke in 1946 [5]. Since then, many histologically proved cases have been reported. In a few of them, CT of the pelvis revealed a lesion on the sciatic nerve [6,7]. Endometriosis, a very common gynecologic disease, affects between 1% and 5% of women of reproductive age [8]. Few cases of the

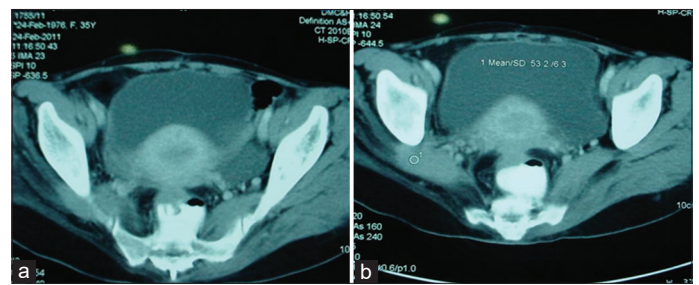


Figure 1: Computed tomography scan of the pelvis. (a) Axial section shows the blurring of endomyometrial junction with hypodense areas in myometrium; (b) coronal section shows a thin-walled cyst with hyperdense dependent debris in the left hemipelvis superolateral to urinary bladder s/o endometriotic cyst

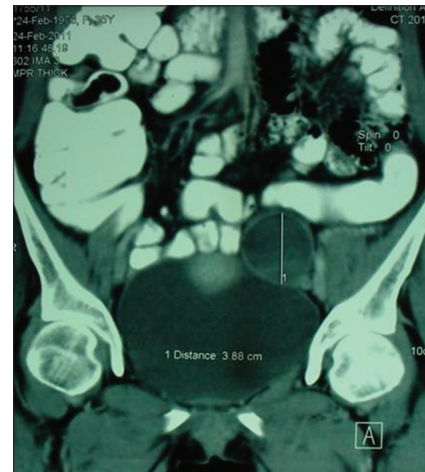

Figure 2: Axial computed tomography section shows eccentric enhancing thickening of the anterior rectal wall with soft tissue in rectouterine space extending laterally to involve the right greater sciatic notch with the involvement of neurovascular bundle and piriformis muscle

sciatic nerve and the lumbosacral plexus involvement in the literature have been mentioned. A case is reported of sciatic nerve involvement with a hemorrhagic lesion of endometriosis, as demonstrated on magnetic resonance (MR) imaging [9]. A woman was referred for episodic pain in her back and left leg with difficulty walking. Clinical history revealed cyclic left sciatica that had persisted for longer than 3 years. Pelvic MR revealed a distinct mass of approximately 2 cm in diameter in the left sciatic notch. The lesion was situated in the lower part of the piriformis muscle, in contact with the sciatic nerve in the gluteal area.

The location of endometrial nodes at the root of a nerve or in the nerve itself is rare topographic variations of endometriosis. The existence of a peritoneal diverticulum permits endometrial tissue to migrate to the sciatic nerve from the site of genital endometriosis or after retrograde menstruation through the fallopian tubes [10], but this “pocket sign” rarely is observed during the pelvic examination. Hematologic migration after vascular damage such as a slight injury or surgery also could be the cause, especially in patients without other sites of endometriosis. Because endometriosis is hormone dependent, the hemorrhage penetrates neighboring tissues during each menstrual cycle and

triggers an inflammatory response. The sciatica is cyclical and occurs during menstrual periods, sometimes beginning 1–2 days before or after the 1st day of a period. The pain is intense and progressive, with a pain-free interval that gradually shortens until, after a few years, it becomes permanent. There is a predominance of sciatic pain on the right side [11]. A case is reported, in which pain disappeared during pregnancy; in many other cases, it had no effect on pain [12].

Sciatic nerve endometriosis was previously treated with surgery, and the most commonly used surgeries were hysterectomy and bilateral salpingo-oophorectomy. Surgery must be appropriately directed to avoid negative exploration. Surgical decompression achieves good relief of symptoms, and medical therapy also allows sustained suppression of this disease. Few cases of sciatic nerve endometriosis have been reported to respond well to medical management. De Cesare *et al.* reported rapid and complete resolution of sciatica secondary to endometriosis after medical treatment with the gonadotropin-releasing hormone analog leuprolide acetate for depot suspension [13].

CONCLUSION

Endometriosis should be suspected and treated aggressively both medically and surgically in women of childbearing age who present with catamenial pain to reduce both the medical and psychological impact of the treatable hormonal condition. Therefore, we are reporting this case that we need to have a high index of suspicion in a young female of this particular entity, even though the manifestation may be unusual, beyond sciatic nerve involving the whole of the lumbosacral plexus, as was seen in our particular patient.

REFERENCES

1. Douglas C, Rotimi O. Extragenital endometriosis—a clinicopathological review of a Glasgow hospital experience with case illustrations. *J Obstet Gynaecol* 2004;24:804-8.
2. Veeraswamy A, Lewis M, Mann A, Kotikela S, Hajhosseini B, Nezhat C. Extragenital endometriosis. *Clin Obstet Gynecol* 2010;53:449-66.
3. Griffin JB, Betsill WL Jr. Subcutaneous endometriosis diagnosed by fine needle aspiration cytology. *Acta Cytol* 1985;29:584-8.
4. Honoré GM. Extrapelvic endometriosis. *Clin Obstet Gynecol* 1999;42:699-711.
5. Schlicke CP. Ectopic endometrial tissue in the thigh. *J Am Med Assoc* 1946;132:445.
6. Fishman EK, Scatarige JC, Satsouk FA, Rosenhein NB, Siegelman SS. Computed tomography of endometriosis. *J Comput Assist Tomogr* 1983;7:257-64.
7. Richards BJ, Gillet WR, Polloc KM. Reversal of footdrop in sciatic nerve endometriosis. *J Neurol Neurosurg Psychiatry* 1991;54:935-40.
8. Barbieri RL. Endometriosis 1990: Current treatment approaches. *Drugs* 1990;39:502-10.
9. Moeser P, Donofrio PD, Karstaedt N, Bechtold R, Greiss FC Jr. MRI findings of sciatic endometriosis. *Clin Imaging* 1990;14:64-6.
10. Hedd HB, Welch JS, Mussey E, Espinosa RE. Cyclic sciatica. Report of a case with introduction of a new surgical sign. *JAMA* 1962;180:521-4.
11. Torkelson SJ, Lee RA, Hildahl DB. Endometriosis of the sciatic nerve: A report of two cases and a review of the literature. *Obstet Gynecol* 1988;71:473-7.
12. Salazar-Grueso E, Roos R. Sciatic endometriosis: A treatable sensorimotor mononeuropathy. *Neurology* 1986;36:1360-3.
13. Decesare SL, Yeko TR. Sciatic nerve endometriosis treated with a gonadotropin releasing hormone agonist. A case report. *J Reprod Med* 1995;40:226-8.

Funding: None; Conflicts of Interest: None Stated.

How to cite this article: Singla M, Bansal P, Gupta K, Aggarwal S. Lumbosacral plexopathy – An unusual presentation of sciatic endometriosis. *Indian J Case Reports*. 2020;6(5):274-276.

Doi: 10.32677/IJCR.2020.v06.i05.020