

## Giant genital seborrheic keratosis: A case report and review of the literature

Rupinder Kaur<sup>1</sup>, Charu Batra Atreja<sup>2</sup>, Sneha Singh<sup>2</sup>, Samriti Gupta<sup>3</sup>

From <sup>1</sup>Professor, <sup>2</sup>Assistant Professor, <sup>3</sup>PG Demonstrator, Department of Pathology, Maharishi Markandeshwar Institute of Medical Sciences and Research, Ambala, Haryana, India

**Correspondence to:** Dr. Rupinder Kaur, Department of Pathology, MMIMSR, Mullana – 133207, Ambala, Haryana, India.  
E-mail: rupicmc@yahoo.com

Received - 13 March 2020

Initial Review - 06 April 2020

Accepted - 20 April 2020

### ABSTRACT

Seborrheic keratosis (SK) of the skin is a quite common lesion characterized by epithelial proliferation. However, its occurrence in genitalia can grossly be mistaken for genital warts and can only be confirmed on histology. We, hereby report the case of a 44-year-old gentleman who presented with large polypoidal growth in the pubic region. Histopathology confirmed it to be giant genital SK.

**Key words:** *Genitalia, Genital warts, Giant seborrheic keratosis*

Seborrheic keratosis (SK) is a common lesion in the elderly population. It can occur anywhere in the sun-exposed areas of the skin except for palms, soles, and mucosa [1]. It is formed due to the rapid proliferation of the keratinocytes of the skin. Its occurrence in the genital region is rare and can be misdiagnosed as genital warts [2]. The lesions in reported incidences of SK in genital areas are usually small and seen commonly in males. Dermoscopic examination of the lesion and careful histopathological diagnosis aids in clinching the diagnosis [1-5].

### CASE REPORT

A 44-year-old gentleman presented to the outpatient department with complaints of swelling in the pubic region involving the base of the penis along with difficulty in micturition for 1 year. There was no history of sexual promiscuity in either of the spouse. There was no history of diabetes, hypertension, or any other significant medical ailments. Past medical and personal history were non-contributory. There was no familial history of such lesions in any of the family.

Local clinical examination revealed a verrucous well-demarcated blackish brownish papillomatous growth giving a “stuck on appearance” located on the pubic region involving the base of the penis and measuring 6.5 × 4.5 × 3.5 cm. No lymphadenopathy was seen in either of the inguinal areas.

The radiological examination of the lesion was suggestive of fungating growth at the root of the penis. No involvement of the underlying bone was observed. Imaging of the abdomen did not reveal any internal lesion or malignancy. The complete hemogram, renal and liver function tests were within normal range. Viral serology (hepatitis B, C, and HIV) and the venereal disease research laboratory test were non-reactive.

Bowenoid papillomatosis and squamous cell carcinoma were kept as differentials after clinical, radiological, and laboratory

examinations. The whole lesion was excised up to the base of the penis with surrounding normal skin and was subjected for histopathological examination.

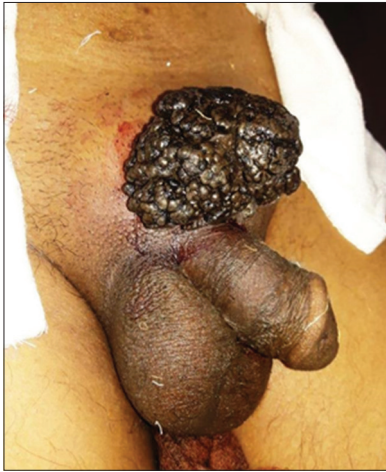Gross examination showed a skin covered blackish brownish polypoidal mass showing cerebriform appearance with fissures and ridges and measuring 6.5 × 4.5 × 3.5 cm (Fig. 1). The cut section showed greyish white verrucous areas.

Microscopy revealed an exophytic lobular lesion exhibiting marked hyperkeratosis, papillomatosis, and acanthosis with proliferation of basaloid cells showing the presence of melanocytes in the basal layer (Fig. 2). No melanocytes were seen within the lobules. Numerous true and pseudo horn cysts were seen within the epidermis (Fig. 3). The subepithelium showed edema with the presence of chronic inflammatory cell infiltrate. No evidence of viral cytopathic effect, dysplasia, or malignancy was observed in any of the sections studied. A histomorphological diagnosis of giant SK acanthotic type was made.

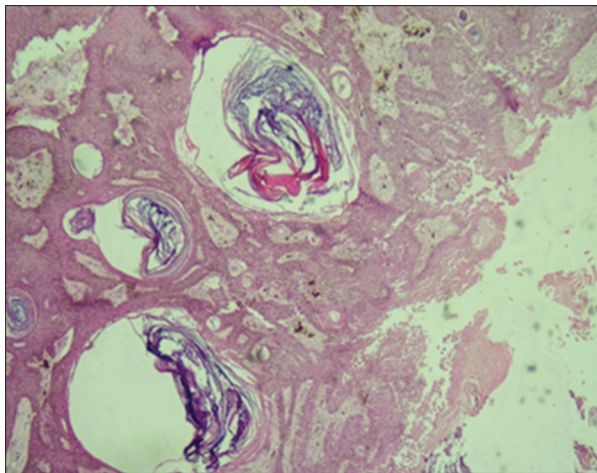
### DISCUSSION

SK is also known as senile warts or basal cell papillomas [2]. The lesions are rarely more than 3 cm in diameter and commonly occurs in sun-exposed areas with exception of palms, soles, and mucosa and usually presents as multiple pigmented papules and plaques with stuck-on appearance [1,6]. SK in the genital [1-4,7] and perianal [8] areas is a rare entity and is usually seen mostly in males in 4–5<sup>th</sup> decades [1-5] as seen in our case. However, its occurrence in the younger age group has also been noted in few studies [1,9]. A lone case report on female vulval SK was found after a detailed literature search [3].

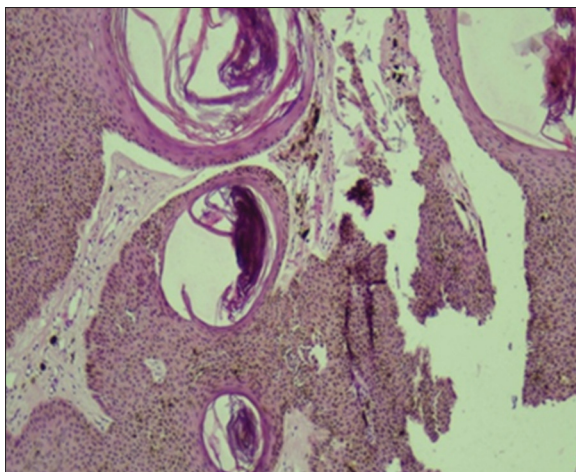
The genital lesions can be misdiagnosed as pedunculated skin tags, condyloma acuminatum, Bowen’s disease, squamous



**Figure 1:** Gross picture showing a skin covered blackish brownish polypoidal mass having cerebriform appearance with fissures and ridges



**Figure 2:** Microphotograph showing exophytic lobular lesion exhibiting marked hyperkeratosis, papillomatosis, and acanthosis. Numerous true and pseudo horn cysts were seen within the epidermis (H&E  $\times 10$ )



**Figure 3:** Microphotograph showing basaloid cells showing the presence of melanocytes in the basal layer (H&E  $\times 25$ )

cell carcinoma, basal cell carcinoma, or melanoma on gross examination [2,3,7,8,10]. Bowenoid papillomatosis and squamous

cell carcinoma were kept as differential diagnoses based on the clinical and imaging analysis in the present study. Depending on the stages of development, the lesions in SK can manifest as macules, papules, or plaques [7,11]. The genital lesion in various studies presented as polypoidal masses which was similar to the lesion seen in our case.

The etiology of SK is unknown, but a familial predisposition with an autosomal mode of inheritance and activation of fibroblast growth factor receptor 3 signaling pathway has been implicated. The role of human papilloma virus-6 (HPV-6) has been suggested in the pathogenesis of SK [4,7,9]. Strong association between genital SK and HPV-6 (70%) was seen in a study done by Tardio *et al.* [9]. However, there were a few studies which did not support this relationship [12,13]. HPV marker study was not done in the present study; however, viral serology was negative.

SK in the genital area is usually seen as solitary lesion but rare reported cases with multiple lesions have found especially when associated with advancing age [1,2,7]. Various morphological variants of SK have been identified, namely, common flat type, and skin tag such as stucco keratosis, dermatosis papulosa nigra, inverted follicular keratosis, and melanoacanthoma type [14]. There is the equal number of distinct histomorphological patterns seen in SK with overlapping features: Hyperkeratotic, clonal, irritated, desmoplastic, adamantinoma, inflamed, and acanthotic type [7]. All types of SK have hyperkeratosis, acanthosis, and papillomatosis as common histological features. The present study showed acanthotic type as a predominant pattern similar to few other studies [3,4,8].

## CONCLUSION

SK involving the genital region is rare and can be easily be misdiagnosed as warts or malignancy. The diagnosis of SK can be challenging; however, a careful dermoscopic examination and histopathological examination are used to clinch the final diagnosis.

## REFERENCES

1. Thakur JS, Thakur A, Chauhan C, Diwana VK, Chauhan DC. Giant pedunculated seborrheic keratosis of penis. *Indian J Dermatol* 2008;53:37-8.
2. Seethalakshmi GV, Venugopal S, Nanjappachetty G, Kannan G. Giant seborrheic keratosis of the genitalia with an unusual histopathological finding. *Indian J Sex Transm Dis* 2017;38:176-9.
3. Nath AK, Kumari R, Rajesh G, Thappa DM, Basu D. Giant seborrheic keratosis of the genitalia. *Indian J Dermatol* 2012;57:310-2.
4. Sevil A, Başsorgun CI. Giant seborrheic keratosis of the genitalia Clinically mimicking a genital wart. *J Clin Exp Dermatol* 2013;4:185.
5. Livaoglu M, Karacal N, Gücer H, Arvas L. Giant genital seborrheic keratosis. *Dermatol Surg* 2007;33:1357-8.
6. Salim S, Bouhelab J, Benzekri A, Hassam B. Seborrheic keratoses of the penis: About a rare case. *J Dermatol Res Ther* 2018;4:62.
7. Hafner C, Vogt T. Seborrheic keratosis. *J Dtsch Dermatol Ges* 2008;8:664-77.
8. Salah B, Mahseeri M, Al-Ali Z, Gaiath A, Aldwan T, Rawashdeh BA. Giant perianal seborrheic keratosis: A case report. *Int J Surg Case Rep* 2018;51:296-301.
9. Tardío JC, Bancalari E, Moreno A, Martín-Fragueiro LM. Genital seborrheic keratoses are human papillomavirus-related lesions. A linear array genotyping test study. *APMIS* 2012;120:477-83.

10. Part M, Svecová D, Brezová D, Breza J. Giant seborrheic keratoses on penis. *J Sex Med* 2014;11:3119-22.
11. Stern RS, Boudreaux C, Arndt KA. Diagnostic accuracy and appropriateness of care for seborrheic keratoses. A pilot study of an approach to quality assurance for cutaneous surgery. *JAMA* 1991;265:74-7.
12. Zhu WY, Leonardi C, Kinsey W, Penneys NS. Irritated seborrheic keratoses and benign verrucous acanthomas do not contain papillomavirus DNA. *J Cutan Pathol* 1991;18:449-52.
13. Serarslan G, Atik E, Otlu B, Bakariş S, Durmaz R . Expression of cell proliferation markers in benign, premalignant and malignant lesions and human papillomavirus isolation. *Turk Arch Dermatol Venereol* 2007;41:57-62.
14. Quinn AG, Perkins W. Non-melanoma skin cancer and other epidermal skin tumours. In: Burns T, Breathnach S, Cox N, Griffiths C, editors. *Rook's Textbook of Dermatology*. 8<sup>th</sup> ed., Vol. 3. Oxford: Blackwell Science; 2010. p.52.38-52.39.

*Funding: None; Conflict of Interest: None Stated.*

**How to cite this article:** Kaur R, Atreja CB, Singh S, Gupta S. Giant genital seborrheic keratosis: A case report and review of the literature. *Indian J Case Reports*. 2020;6(5):232-234.

Doi: 10.32677/IJCR.2020.v06.i05.005