

Diphtheria in adult - A case report

S R Swarna¹, Stalin Sivagurunathan², T Bharathi³, Mohan Kumar⁴, M Lavanya⁵, D Jeyakumari⁶

From ¹Associate Professor; ⁴Assistant Professor; ⁵Tutor; ⁶Professor and Head, Department of Microbiology, JIPMER, Karaikal, Puducherry, ²Professor, Department of ENT; ³Microbiologist, Department of District Model Laboratory, Government General Hospital, Karaikal, Puducherry

Correspondence to: S R Swarna, Department of Microbiology, JIPMER, Karaikal, Puducherry, India. E-mail: srswa@yahoo.co.in

Received - 19 February 2020

Initial Review - 05 March 2020

Accepted - 23 March 2020

ABSTRACT

Diphtheria caused by *Corynebacterium diphtheriae* is a toxin-mediated upper respiratory tract infection. It spreads by airborne respiratory droplets and commonly affects children. The implementation of a Universal Immunization Program has resulted in a decline in the incidence. In spite of the ongoing immunization program, there is an intermittent re-emergence of diphtheria in developing countries like India. The resurgence of diphtheria in the recent past, with a shift in the age from children to adults, poses a major concern. Hereby, we report a case of isolation of toxigenic *C. diphtheriae* from an adult patient who suffered from diphtheritic tonsillitis.

Key words: *Corynebacterium diphtheriae*, Diphtheritic tonsillitis, Upper respiratory tract infection

Diphtheria is an acute upper respiratory tract disease of childhood caused by toxin-producing *Corynebacterium diphtheriae*. It is spread by direct contact or by inhalation of aerosolized secretions from the infected individual. The infection is characterized by sore throat, low-grade fever, and an adherent membrane on the tonsils, pharynx, and/or nasal cavity. It was also reported that diphtheria toxin produced by *C. diphtheriae* can lead to myocarditis and polyneuritis if not treated [1]. After the introduction of diphtheria-tetanus toxoid (TT) and whole-cell pertussis (diphtheria-TT pertussis) vaccines, three doses, starting at 6, 10, and 14 weeks of the age followed by two booster doses at 18 months between 54 and 72 months of the age, the occurrence of diphtheria started declining.

In the recent past, in spite of the reported increase in coverage of the Universal Immunization Program (UIP), there are reports of either re-emergence or persistence of *C. diphtheriae* in India [2,3]. The percentage positivity of diphtheria cases varies from 17% to 79% in children of >10 years of age in different places of India due to waning of vaccine-induced immunity [2,4]. Here, we report a case of an adult female patient who suffered from diphtheritic tonsillitis from whom toxigenic *C. diphtheriae* was isolated.

CASE REPORT

A 28-year-old female came to the ENT outpatient department with complaints of fever and pain on swallowing for the past 3 days. On general examination, the patient was oriented to time, place, and person and there was no pallor, icterus, clubbing, cyanosis, generalized lymphadenopathy, and edema. Her pulse rate was 92/min and her blood pressure was 110/70 mmHg. The examination revealed bilateral Grade IV tonsillar enlargement

covered by a white membrane with edematous uvula, whereas the posterior pharyngeal wall was clear. Diffuse swelling of the neck was noted. On indirect laryngoscope examination, arytenoids, arytenoids epiglottis fold, and false cords were edematous and congested. The condition was provisionally diagnosed as diphtheritic tonsillitis, and throat swab was sent to the laboratory.

Laboratory investigations showed Gram-positive bacilli clustered with few epithelial cells and no inflammatory cells on Gram staining. A direct smear of Albert staining showed no metachromatic granules. The culture of the throat swab showed growth of colonies morphologically similar to *C. diphtheriae* (Fig. 1). Gram stain from culture showed Gram-positive bacilli and Albert stain showed the presence of green bacilli with bluish-black metachromatic granules (Fig. 2). Urease test was negative. Antibiotic sensitivity testing showed that isolated strain was sensitive to erythromycin (31 mm), clindamycin (25 mm), cotrimoxazole (21 mm), gentamicin (27 mm), ciprofloxacin (21 mm), norfloxacin (17 mm), vancomycin (21 mm), and linezolid (22 mm) (Fig. 3). To confirm, the culture was sent to JIPMER, Puducherry and identified as *C. diphtheriae* by matrix-assisted laser desorption/ionization-time-of-flight. Further, the isolate was sent to CMC, Vellore, for toxin detection and was found to be positive for Elek's test and toxA gene by a polymerase chain reaction (PCR).

Soon after, the provisional diagnosis of diphtheritic tonsillitis, the patient was referred to a tertiary care teaching hospital, Puducherry. Subsequently, the patient got treated with IV crystalline penicillin 20 lakh IU 06 h and IV metrogyl 500 mg 08 h for 2 days and given one lakh units of antitoxin, followed by erythromycin for 3 days and improved symptomatically. The patient was followed for 2 months and there was no recurrence.

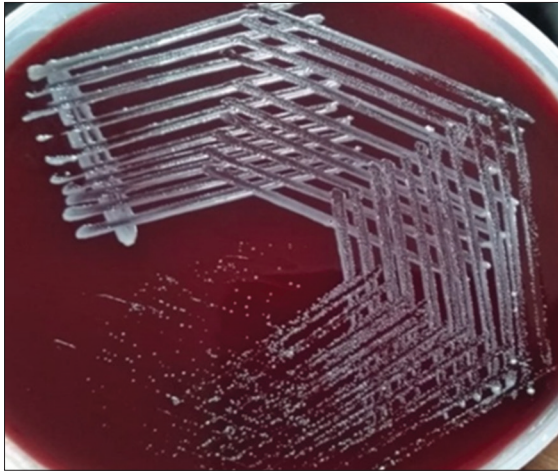


Figure 1: Culture of *Corynebacterium diphtheriae* on blood agar

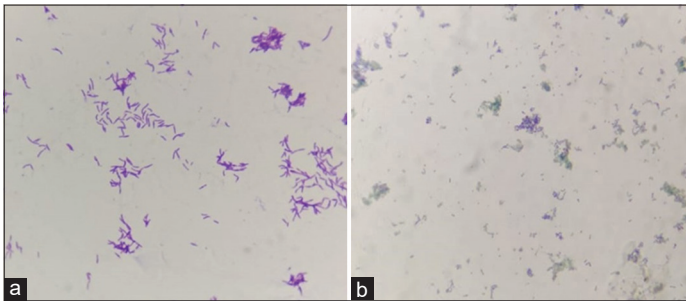


Figure 2: (a) Gram stain showing Gram-positive bacilli in the cuneiform arrangement (×1000); (b) Albert stain showing metachromatic granules (×1000)

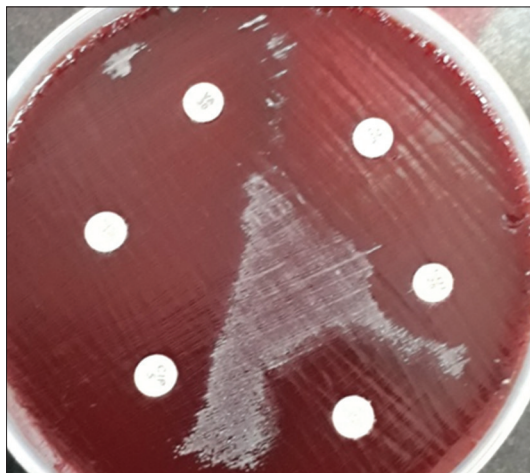

Figure 3: Antibiotic susceptibility testing on blood agar by Kirby-Bauer disc diffusion method

DISCUSSION

Diphtheria, being a vaccine-preventable disease, is reported to re-emerge, despite the increased coverage of the UIP. Data from the World Health Organization showed that India contributed to 53.9% of diphtheria cases globally in the year 2016 [5]. Ten Indian states, namely, Kerala, Assam, Delhi, Gujarat, Haryana, Karnataka, Nagaland, Maharashtra, Rajasthan, and West Bengal, accounted for 84% of these cases [6]. Most infections are asymptomatic or run a relatively mild clinical course. However,

the case fatality ratio was 2.2% in India, and such a low percentage was due to active surveillance during the outbreaks by the health system along with early diagnosis, isolation, and treatment of cases and contacts [6].

Although the diphtheritic tonsillitis was provisionally diagnosed in the present case, the microbiological diagnosis was carried out to rule out other clinical conditions such as severe streptococcal throat infection, Vincent's angina, or glandular fever. The typical Gram stain morphology and metachromatic granules could not be demonstrated by direct examination. However, staining done on growth from the blood culture able to reveal the characteristic Gram-positive bacilli with a cuneiform arrangement on Gram staining and metachromatic granules on Albert staining. Further, confirmation by the automated method was done at JIPMER, Puducherry, and toxin production by *in vitro* Elek's test and presence of *toxA* gene by PCR at CMC, Vellore. To prevent toxin-mediated complications of diphtheria and to eliminate the infection to prevent further transmission, anti-diphtheritic serum and antibiotic therapy were administered to the patient in the referral center. Subsequently, the patient improved symptomatically.

In the present case, the diphtheritic patient was a 28-year-old female. The age shift in the occurrence of diphtheria from children to adolescents and adults was reported from various states in India [2,7,8]. The study from Pondicherry reported the persistence of non-toxigenic strains of *C. diphtheriae* in two adults, causing diphtheria [9]. Another study from Andhra Pradesh reported female preponderance and stated that females above 20 years are either caregivers for children and adolescents or work in households that pose them high risk for contracting the disease [10]. In the present case, although the source cannot be traced, it was suggested that the main source of infection in the community is either unimmunized children or older unimmunized cohort and reported a ratio of 95 carriers for five clinical cases [11].

The present case gave a history of complete immunization. In spite of it, the patient was susceptible to diphtheria, and this might be probably due to waxing immunity. In addition, other factors suggested for increased susceptibility risk in adults include the infecting dose, virulence of the diphtheria bacilli, failure to undergo vaccination in early childhood, overcrowding, increase in the migrant population and low awareness among parents [12].

It is a known fact that immunity against diphtheria depends primarily on the antibody to diphtheria toxin. Long-term protection depends on a high level of circulating anti-diphtheria toxoid IgG antibody at a level of ≥ 1.0 IU/ml, as reported in serological studies [6]. A decrease in antibody titers between 0.01 and 0.09 IU/mL can lead to declining immunity. As the level of antibodies decreases over time, adults become susceptible to diphtheria. Moreover, they might have reduced opportunities for boosting through subclinical infections with circulating toxigenic strains of *C. diphtheria* or repeat vaccination [12].

Disease in the previously immunized individuals is milder and less likely to be fatal, as is observed in the present case. To control

the re-emergence of diphtheria, studies have recommended the replacement of TT with tetanus-diphtheria toxoid as a booster dose for adults, particularly at school leaving age, pregnancy, after the age of 18 years [6]. Such a periodic adult booster helps to avoid re-emergence of this serious, potentially fatal infectious disease by maintaining the protective antitoxin levels.

CONCLUSION

The present study emphasized the need for constant epidemiological surveillance due to the isolation of toxigenic strains of *C. diphtheria* from this geographical location. This is achieved through early detection of diphtheria outbreaks and assessment of immunization programs by serosurveillance to reduce transmission and mortality rates.

REFERENCES

- Dikid T, Jain SK, Sharma A, Kumar A, Narain JP. Emerging and re-emerging infections in India: An overview. *Indian J Med Res* 2013;138:19-31.
- Sangal L, Joshi S, Anandan S, Balaji V, Johnson J, Satapathy A, *et al.* Resurgence of diphtheria in North Kerala, India, 2016: Laboratory supported case-based surveillance outcomes. *Front Public Health* 2017;5:218.
- Mahantesh VP, Aisha MP, Lakkannavar SL, Sanjiva DK, Subarna R. Diphtheria outbreak in rural North Karnataka, India. *JMM Case Rep* 2014;1:1-3.
- Bhagat S, Grover SS, Gupta N, Roy RD, Khare S. Persistence of *Corynebacterium diphtheriae* in Delhi and national capital region (NCR). *Indian J Med Res* 2015;142:459-61.
- Mohanty A, Bhatia M, Gupta P, Varshney S, Malhotra M, Omar BJ. Diphtheria: The patch still remains-a case report from the state of Uttarakhand. *J Pharm Bioallied Sci* 2019;11:190-3.
- Murhekar M. Epidemiology of diphtheria in India, 1996-2016: Implications for prevention and control. *Am J Trop Med Hyg* 2017;97:313-8.
- Chandran P, Lilabi MP, Thomas B, Thavody J, George S. Re-emergence of diphtheria in Kerala: The need for change in vaccination policy. *Int J Community Med Public Health* 2019;6:829-35.
- Parande MV, Roy S, Mantur BG, Parande AM, Shinde RS. Resurgence of diphtheria in rural areas of North Karnataka, India. *Indian J Med Microbiol* 2017;35:247-51.
- Shashikala P, Reddy PV, Prashanth K, Kanungo R, Devi S, Anitha P, *et al.* Persistence of nontoxigenic *Corynebacterium diphtheriae* biotype gravis strains in Pondicherry, Southern India. *J Clin Microbiol* 2011;49:763-4.
- Meera M, Rajarao M. Diphtheria in Andhra Pradesh-a clinical-epidemiological study. *Int J Infect Dis* 2014;19:74-8.
- Das PP, Patgiri SJ, Saikia L, Paul D. Recent outbreaks of diphtheria in Dibrugarh District, Assam, India. *J Clin Diagn Res* 2016;10:1-3.
- Krishnan S, Kizhakkekarammel P, George K, Johnson J, Kurukanari R, Raveendran G. Re-emergence of diphtheria in Malappuram District, North Kerala, India. *J Acad Clin Microbiol* 2018;20:37-9.

Funding: None; Conflict of Interest: None Stated.

How to cite this article: Swarna SR, Sivagurunathan S, Bharathi T, Kumar M, Lavanya M, Jeyakumari D. Diphtheria in adult – A case report. *Indian J Case Reports*. 2020;6(4):160-162.

Doi: 10.32677/IJCR.2020.v06.i04.004