

## Axillary lymph node metastasis in gastrointestinal stromal tumor of jejunum: A case report

Manishi Bansal<sup>1</sup>, Smriti Gupta<sup>2</sup>, Girdhar Gopal<sup>3</sup>

From <sup>1</sup>Senior Radiation Oncologist, Department of Radiation Oncology, <sup>2</sup>Consultant Pathologist and Lab Head, Department of Pathology, SRL Lab, <sup>3</sup>Oncosurgeon, Department of Surgical Oncology, Mayo Hospital, Mohali, Punjab, India

**Correspondence to:** Dr. Smriti Gupta, SRL Limited, Mayo Hospital, Sector 69, Mohali, Punjab, India. E-mail: smriti.gupta@srl.in

Received - 20 January 2020

Initial Review - 06 February 2020

Accepted - 25 February 2020

### ABSTRACT

A gastrointestinal stromal tumor (GIST) is the most common mesenchymal tumor of the gastrointestinal tract accounting for <1% of all gastrointestinal tumors. The stomach is the most common primary site and the tumor spreads more frequently to the liver and peritoneum rather than lymph nodes. Herein, we present a rare case of a 78-year-old man who presented with GIST of the jejunum, which was surgically excised but developed isolated matted axillary lymph nodes 1 year after surgery. The axillary lymph nodes were excised, and histopathology confirmed metastasis from GIST of the jejunum. The patient was started on imatinib therapy and is completely disease free after 8 months of the second surgery.

**Key words:** Axillary lymph node, Gastrointestinal stromal tumor, Jejunum, Metastasis

Gastrointestinal stromal tumors (GISTs) are the most common mesenchymal tumors of the gastrointestinal tract (GIT), accounting for approximately 1–3% of all gastrointestinal tumors and 80% of all sarcomas [1]. Mazur and Clarke coined the term GIST in 1983 for mesenchymal tumors of the GIT which do not have any ultrastructural or immunohistochemical (IHC) features characteristic of smooth muscle differentiation [2]. Kindblom *et al.* in 1998 demonstrated that the actual cell of origin of these tumors is a pluripotent mesenchymal stem cell programmed to differentiate into interstitial cells of Cajal, which are the cells responsible for initiating and coordinating gastrointestinal motility [3].

These tumors have different clinical and biological behavior than other malignancies of the GIT. GISTs usually spread through the hematogenous route to the liver and peritoneum and lymph node metastasis within and outside the abdominal cavity are extremely rare. They most commonly arise from the stomach (60%) followed by the small intestine in 30% of the cases. Therefore, we report a case who presented with GIST of the jejunum which is an unusual primary site and later developed peripheral lymph node metastasis in the axilla, which is again a very rare presentation.

### CASE REPORT

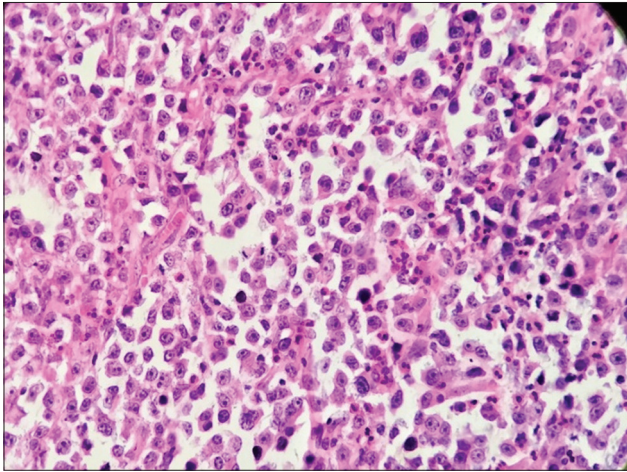
A 78-year-old male presented with complaints of pain in the abdomen for the past 3 months and one episode of hematemesis 7 days back. He was a chronic smoker and occasional alcoholic with no other significant past or family history. Blood counts, liver, and kidney parameters were within normal limits. His

ultrasonography was normal, computed tomography (CT) of the abdomen revealed thickening of the jejunum with a mass lesion. He was planned for upper gastrointestinal endoscopy which showed a soft, friable, polypoidal lesion in the jejunum. A biopsy was taken which was suggestive of malignancy.

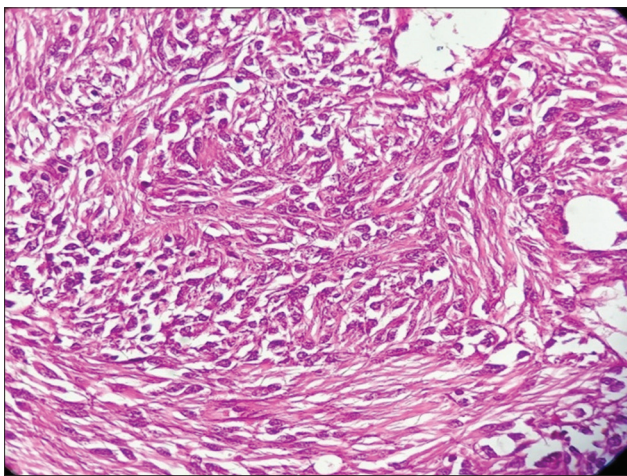
He was further investigated with positron emission tomography-CT (PET-CT) scan to look for any distant metastasis. However, a PET-CT scan revealed only a mass in the jejunum with no disease elsewhere. Surgery with anastomosis (R0 resection) was performed and the jejunal mass was sent for histopathological examination. Grossly, the tumor was 8.5×6.5×5 cm in size, intramural, and firm mass. Serosa appeared free.

On microscopic examination, spindle-type GIST was diagnosed with a mitotic count of >5/50 high-power field (HPF) – high grade (Fig. 1). The angiolymphatic invasion was present and perineural involvement was an intermediate type. Further IHC studies were done and the tumor was positive for CD117. Hence, the diagnosis of GIST was confirmed and adjuvant treatment with imatinib 400 mg/day was started in view of a high-grade tumor with lymphovascular and perineural invasion.

After 1 year, the patient presented with a complaint of the right axillary mass. The mass was about 9x6 cm, firm to hard in consistency and fixed to underlying muscles. He was again investigated. PET-CT scan showed 18F-fluorodeoxyglucose uptake on the right axilla with no evidence of disease elsewhere. Fine-needle aspiration cytology and biopsy performed with no conclusive diagnosis. Hence, the decision was taken to excise the axillary lymph nodes *en bloc*. The right axillary lymph node dissection was done, and the excised mass sent for histopathological examination.



**Figure 1: Spindle-type gastrointestinal stromal tumor, with a mitotic count of >5/50 high-power field – high grade**



**Figure 2: Round to polygonal poorly differentiated cells infiltrating the lymph nodes with increased mitotic activity**

Grossly, the mass was multinodular overall measuring 10×6×4 cm. The cut surface showed multiple lymph nodes. Microscopic examination revealed round to polygonal poorly differentiated cells infiltrating the lymph nodes. Increased mitotic activity was observed (Fig. 2). IHC revealed strong positive for vimentin and patchy positivity for CD 117.

In view of the clinical history of GIST and patchy CD117 positivity, a probable diagnosis of metastatic GIST was given. He was continued with imatinib 400 mg once a day in view of old age and good tolerance to imatinib. It is now 8 months post-axillary surgery and he is asymptomatic with no evidence of disease.

## DISCUSSION

GISTs are uncommon tumors of the GIT, seen more commonly in 60–70 years of age. Stomach being the most common site followed by the small intestine in 30% of the cases [4]. Our patient presented with the jejunum as the primary site which is a less common occurrence. Very few cases of GIST of the small intestine, particularly of the jejunum, have been reported so far. Ma *et al.* have reported a case of GIST of jejunum with mediastinal

and left supraclavicular lymph nodes which developed 1 year after the primary surgery as in our case [5].

The incidence of lymph node metastasis in GIST is 1–5% only [6,7]. Among the lymph node metastasis, peritumoral and abdominal lymph node metastasis is more common than extra-abdominal. Peritumoral lymph nodes are usually discovered in histopathological examination of surgical specimens. DeMatteo *et al.* studied the pattern of recurrence and metastasis in 200 cases of digestive tract GISTs and found only six cases with lymph node metastasis (6%) [6]. The literature is also sparse on the distant lymph node metastasis from GIST. To the best of our knowledge, very few such cases have been reported so far.

Zhang *et al.* reported a case of GIST of the stomach with inguinal lymph node metastasis which developed 3 years after primary surgery [8]. However, this patient already had perigastric lymph nodes and the liver metastasis at the time of diagnosis which could explain the aggressive behavior of the tumor. Vasso *et al.* reported two cases of GIST with extra-abdominal lymph nodes metastasis [9]. One patient had GIST of the ileum with synchronous inguinal lymph node presentation and the other patient had GIST of the stomach with liver metastasis and axillary lymph developing 2 years later. The biological behavior of these GISTs is similar to that of adenocarcinomas, but the exact phenomenon of the occurrence of distant metastasis in few cases of GISTs is unknown.

Molecular pathological studies show that approximately 75–80% of all GISTs have mutations in the receptor for tyrosine kinase – KIT [10]. Approximately 5–10% of GISTs have mutations that activate a closely related receptor tyrosine kinase called platelet-derived growth factor receptor alpha (PDGFRA) [11]. KIT and PDGFRA mutations are mutually exclusive. Few GISTs without the above two mutations (wild-type GISTs) may have mutations in other genes that function through the same pathway as NF1, BRAF, HRAS, and NRAS [12]. A recent gene expression profiling study has shown that a novel gene DOG1 (which encodes a hypothetical protein) is expressed ubiquitously in GISTs irrespective of KIT or PDGFRA mutation status, which might be useful for diagnosis and for the guidance of therapy in KIT-negative status [13].

The molecular phenotype is an important consideration in the prognostication and treatment of patients of unresectable, recurrent, or metastatic GISTs. The recognition that activating c-KIT mutations plays a central role in the pathogenesis of GISTs and the recent development of clinically effective inhibitors targeting the transmembrane receptor tyrosine kinase c-KIT radically changed the management of the advanced and metastatic disease [14].

Although the relationship between certain genotypes and clinical progression has been described by Heinrich *et al.* in a few articles [11], it is still unclear as to why few patients develop aggressive and unusual metastasis. It is also unclear as to why the expression of CD117 in certain metastatic lesions is diminished, which also happened in our case. The absence or patchy positivity of CD117 may be due to the dedifferentiation of the malignancy or may be associated with changes induced by tyrosine kinase inhibitor therapy [15].

The major prognostic factors are tumor size, mitotic rate, and primary site. Miettinen and Lasota have developed guidelines for the risk stratification of primary GIST based on the long-term follow-up [12]. According to these guidelines, gastric GISTs have an overall indolent behavior and <2 cm in size are essentially benign, whereas GISTs of small intestine and rectum tend to be more aggressive. The American Joint Committee on Cancer (AJCC) staging system for GIST has rather categorized gastric and small intestine GIST separately due to differences in clinical behavior.

Bucher *et al.* proposed a grading system based on histopathological findings after surgical resection [16]. It includes two major and five minor criteria. The major criteria being lymphatic and distant metastasis and minor criteria are tumor size, mitotic index, presence of necrosis, infiltration of adjacent structures, and MIBI index. Tumors with one major and four to five minor criteria are classified as high-grade tumors, whereas tumors with <4 minor criteria are termed as low-grade tumors. AJCC staging system has also incorporated a grading system depending on the mitotic rate in the tumor, node, and metastasis classification, making mitotic rate as the most important prognostic factor. The tumor is categorized as low grade when the mitosis is five or less per 50 HPF and high grade when the mitosis is more than five per HPF. Our case was T3 N0 M0 (AJCC Stage III B) with high-grade type, so more prone to local as well as distant spread.

As far as the treatment of GIST is concerned, surgery of the primary tumor without routine lymphadenectomy remains the main modality of treatment. Adjuvant therapy with imatinib and sunitinib is advised if there is residual disease or metastasis. In some cases, pre-operative imatinib can also be given to reduce the size of the primary tumor. The appropriate indication of use in patients and the optimal duration of treatment with imatinib are still not very clear. Based on the results of the American College of Surgeons Oncology Group Z9001 randomized Phase-III trial, adjuvant imatinib can be given for 36 months in high-risk GIST [15].

Mutational analysis and testing is an evolving concept, and its clinical significance is yet to be established. GISTs with exon 11 mutations appear to be more sensitive to imatinib [17]. Our patient was on adjuvant imatinib after primary surgery in view of the high-grade tumor with lymphovascular invasion and remained on imatinib after axillary dissection also in view of old age, R0 resection, and no other site of disease in PET-CT scan. Moreover, imatinib is very well tolerated with fewer side effects.

## CONCLUSION

Extra-abdominal lymph node metastasis is unusual in cases of GIST and heralds a poor prognosis. Surgery remains the mainstay of treatment for gastrointestinal GIST. IHC markers help in confirming the diagnosis and prediction of outcome to treatment. Recent advances in the treatment with targeted agents have given

long-term control rates even in metastatic and recurrent cases. More studies are needed to understand the aggressiveness of GIST in few cases.

## REFERENCES

- Lehnert T. Gastrointestinal sarcoma (GIST)-a review of surgical management. *Ann Chir Gynaecol* 1998;87:297-305.
- Mazur MT, Clark HB. Gastric stromal tumors. Reappraisal of histogenesis. *Am J Surg Pathol* 1983;7:507-19.
- Kindblom LG, Remotti HE, Aldenborg F, Meis-Kindblom JM. Gastrointestinal pacemaker cell tumor (GIPACT): Gastrointestinal stromal tumors show phenotypic characteristics of the interstitial cells of Cajal. *Am J Pathol* 1998;152:1259-69.
- NCCN Practice Guidelines in Oncology-Version 4; 2019. Available from: <https://www.nccn.org>. [Last accessed on 2020 Feb 07].
- Ma C, Hao SL, Liu XC, Nin JY, Wu GC, Jiang LX, *et al.* Supraclavicular lymph node metastases from malignant gastrointestinal stromal tumor of the jejunum: A case report with review of the literature. *World J Gastroenterol* 2017;23:1920-4.
- DeMatteo RP, Lewis JJ, Leung D, Mudan SS, Woodruff JM, Brennan MF. Two hundred gastrointestinal stromal tumors: Recurrence patterns and prognostic factors for survival. *Ann Surg* 2000;231:51-8.
- Aparicio T, Boige V, Sabourin JC, Crenn P, Ducreux M, Le Cesne A, *et al.* Prognostic factors after surgery of primary resectable gastrointestinal stromal tumours. *Eur J Surg Oncol* 2004;30:1098-103.
- Zhang Q, Yu JW, Yang WL, Liu XS, Yu JR. Gastrointestinal stromal tumor of stomach with inguinal lymph nodes metastasis: A case report. *World J Gastroenterol* 2010;16:1808-10.
- Vassos N, Agaimy A, Hohenberger W, Croner RS. Extraabdominal lymph node metastasis in gastrointestinal stromal tumors (GIST). *J Gastrointest Surg* 2011;15:1232-6.
- Fletcher CD, Berman JJ, Corless C, Gorstein F, Lasota J, Longley BJ, *et al.* Diagnosis of gastrointestinal stromal tumors: A consensus approach. *Hum Pathol* 2002;33:459-65.
- Heinrich MC, Corless CL, Duensing A, McGreevey L, Chen CJ, Joseph N, *et al.* PDGFRA activating mutations in gastrointestinal stromal tumors. *Science* 2003;299:708-10.
- Miettinen M, Lasota J. Gastrointestinal stromal tumors: Pathology and prognosis at different sites. *Semin Diagn Pathol* 2006;23:70-83.
- Fisher C. Gastrointestinal stromal tumours. In: Pignatelli M, Underwood J, editors. *Recent Advances in Histopathology*. 21<sup>st</sup> ed. London: The Royal Society of Medicine Press; 2005. p. 71-88.
- Abuzakhm SM, Acre-Lara CE, Zhao W, Hitchcock C, Mohamed N, Arbogast D, *et al.* Unusual metastases of gastrointestinal stromal tumor and genotypic correlates: Case report and review of the literature. *J Gastrointest Oncol* 2011;2:45-9.
- Corless CL, Ballman KV, Antonescu CR, Kolesnikova V, Maki RG, Pisters PW, *et al.* Pathologic and molecular features correlate with long-term outcome after adjuvant therapy of resected primary GI stromal tumor: The ACOSOG Z9001 trial. *J Clin Oncol* 2014;32:1563-70.
- Bucher P, Egger JF, Gervaz P, Ris F, Weintraub D, Villiger P, *et al.* An audit of surgical management of gastrointestinal stromal tumours (GIST). *Eur J Surg Oncol* 2006;32:310-4.
- Parab TM, DeRogatis MJ, Boaz AM, Grasso SA, Issack PS, Duarte DA, *et al.* Gastrointestinal stromal tumors: A comprehensive review. *J Gastrointest Oncol* 2019;10:144-54.

*Funding: None; Conflicts of Interest: None Stated.*

**How to cite this article:** Bansal M, Gupta S, Gopal G. Axillary lymph node metastasis in gastrointestinal stromal tumor of jejunum: A case report. *Indian J Case Reports*. 2020;6(3):103-105.

Doi: 10.32677/IJCR.2020.v06.i03.002