

A case of multiple self-inflicted cuts to the neck and wrist presenting with airway compromise and catastrophic hemorrhage

Utsav Anand Mani¹, Firdaus Behram Bhot², Elizabeth Sada³, Prasun Mishra⁴, Vishwanath Patil⁵, Rajesh Ursekar³, Digvijay Adake⁶, Sushma Shriyan⁷

From ¹Senior resident, ²Professor and Head, ³Associate Professor, ⁴Associate Professor, ⁵Assistant Professor, ⁶Chief resident, ⁷Junior resident, Department of Emergency Medicine, ⁴Department of ENT, ⁵Department of Critical Care, Bharati Hospital, Thane, Maharashtra, India

Correspondence to: Dr. Utsav Anand Mani, Department of Emergency Medicine, Bharati hospital, Katraj Dhankawadi, Pune - Satara road, Pune, Maharashtra, India. E-mail: utsavanandmani@gmail.com

Received - 25 October 2019

Initial Review - 09 November 2019

Accepted - 21 November 2019

ABSTRACT

Cut-throat injuries are seen commonly, however, the reporting in the medical literature is not so common. Due to the close proximity of the vital structures in the neck, there is a high risk of compromise to the airway. Transection of just the ulnar artery in itself is sufficient to cause death within a period of 6 hours. Here, we report the case of a 22-year-old male patient with a history of a self-inflicted wound on the anterior aspect of the neck which was associated with bleeding and respiratory distress and multiple incised wounds over the left wrist. The patient was then taken up in the OT for wound exploration and suturing by an ENT surgeon. Simultaneously Radial and Ulnar artery repair, with the repair of multiple flexor tendons of the left forearm was done by a vascular surgeon and a plastic surgeon, respectively.

Keywords: Airway management, Hypovolemic shock, Neck injuries, Self-Injurious behaviour, Tracheostomy, Wrist injuries.

Cut-throat injuries are common; however, less reported in the medical literature [1]. Most cut injuries to the throat are homicidal than they are suicidal or accidental [2-4]. Cutting of the wrist using a sharp object is a more common method of attempting suicide. Whatever the cause, when a cut-throat injury presents to the emergency department, it poses a great challenge. Due to the close proximity of the vital structures in the neck like the carotid artery, jugular vein and trachea, there is a high risk of compromise to the airway and circulation.

If immediate survival is achieved, the patient is still at risk of surgical site infections, persistent change in voice, neurological deficit, laryngeal stenosis, vocal cord palsies, wound dehiscence, mediastinitis (if an injury is present to the esophagus), pharyngocutaneous fistula and a possibility of permanent tracheostomy [5,6,7]. Transection of just the ulnar artery is sufficient to cause death within a period of 6 hours [8]. It can be presumed that suicidal patients do not attempt to inflict multiple injuries if they attempt a cut-throat [9]. A case was reported where the subject had cut his neck 3 times, stabbed himself 9 times on the chest and slashed both his wrist 14 and 13 times [10].

We report a similar case where a young male has attempted to cut his throat along with inflicting multiple cuts on the wrist with a razor blade leading to a life-threatening hemorrhage of the radial and ulnar artery.

CASE REPORT

A 22-year-old male patient reported with a history of multiple and deep self-inflicted wounds on the anterior aspect of the neck which was associated with bleeding and respiratory distress (Fig. 1). Multiple incised wounds over the left wrist were also associated with cut-throat which was profusely bleeding (Fig. 2). Multiple hesitation marks were present both on the neck and the wrist.

Upon arrival, his saturation was 84% on room air with tachypnea. Blood Pressure was not recordable, and pulses were feeble. To secure the airway an attempt was made at intubating the patient with an endotracheal tube (ET) no 8.5 and a blade of

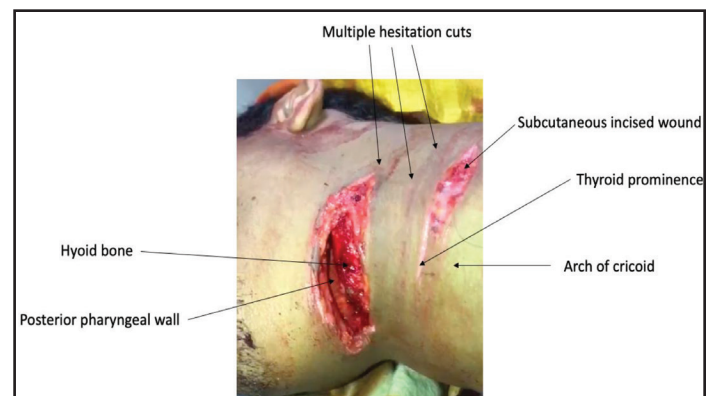


Figure 1: Cut throat injury. The multiple hesitation cuts around the gaping wound were noticed.

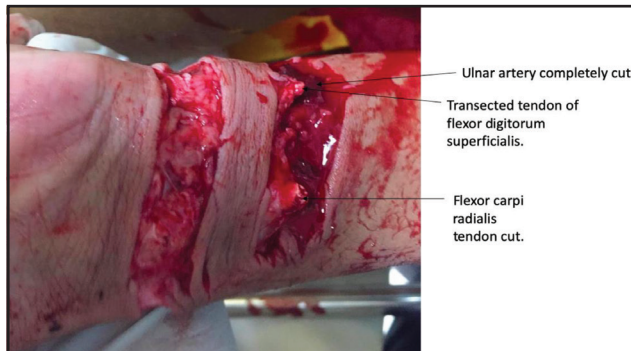


Figure 2: Cut wrist injury. Multiple flexor tendon injuries, median nerve damage, partial cut to the radial artery and complete transection of the ulnar artery were noted during repair.

no. 4 but the tube couldn't be passed in situ due to the significant defect. No attempt was made to pass the tube through the defect in the neck. A cuffed portex no 8 tracheostomy tube was then inserted under the guidance of an ENT surgeon. A tourniquet was promptly applied, and two large-bore IV cannulas were secured immediately, the patient was started on IV crystalloids. Two litres of ringer lactate and 500 ml of colloid was infused to the patient. Following fluid administration, the patient was kept on noradrenaline infusion to maintain adequate mean arterial pressure. Blood grouping and cross-matching were done. The primary survey did not reveal any other life-threatening injury in the chest and abdomen. Tetanus prophylaxis and pain relief were ensured before shifting the patient to a computed tomography (CT) scan and operation theatre (OT).

A head to toe secondary survey revealed the wound over the neck was 12-15 cm long and in the thyrohyoid region gaping was apparent and the wound was deep as that the mucosa of the posterior pharyngeal wall was visualised. Another wound in the neck was present over the cricoid extending into the subcutaneous tissue. Two deep incised cuts over the left wrist revealed multiple flexor tendon injuries, median nerve damage and active blood loss due to partial cut to the radial artery and complete transection of the ulnar artery (Fig. 2).

Subsequently, it was revealed that the patient had used a razor blade and was "lying in a big pool of blood" when he was discovered. The time interval between the injuries inflicted and the discovery by his mother was between four to five hours. Unemployment and a dire financial condition of the family had led the patient to an attempt to take his life. He had no previous history of psychiatric illness and had never attempted suicide in the past. The patient was not on any medication or addictive substances with no history of tobacco or alcohol use.

After the CT scan, the patient was then taken up in the OT for wound exploration and suturing by an ENT surgeon. Simultaneously Radial and Ulnar artery repair, with the repair of multiple flexor tendons of the left forearm was done by a vascular surgeon and a plastic surgeon respectively. During the course of surgery and ICU stay, the patient was transfused with 4 bags of fresh frozen plasma, 4 bags of platelets and 4 bags of packed cells.

The patient was referred to a psychiatrist once stable and started on anti-depressants with counselling done on regular visits. He was discharged on the 12th day after the decannulation of the tracheostomy tube and has been keeping up with the follow up's ever since. A follow-up video laryngoscopy showed both cords to be mobile.

DISCUSSION

According to Roon and Christensen's classification, neck injuries are divided into three zones based on the location [11]. Zone 1 ranges from the sternal notch to the cricoid cartilage. Zone 2 extends from the cricoid cartilage to the angle of the mandible and Zone 3 from the angle of the mandible to the base of the skull. Our patient inflicted upon himself an injury in Zone 2 of the neck, which is where a majority of cut-throat injuries are located [1,6,7,12].

To distinguish between a homicidal, suicidal and an accidental cut-throat injury may be very unconvincing for a forensic pathologist on a case to case basis [4]. A crime scene visualization and a psychological autopsy would definitely help in understanding the intent. This usually is not at stake for the emergency physician. But understanding the intent and counselling with the relatives of the patient would definitely be of help. Knowing the intent will ensure that the patient gets a well-needed consult with a psychiatrist once his condition stabilizes. This is not only useful in cases of deliberate self-harm, but also a case of homicidal or an accidental injury who can develop a post-traumatic stress disorder.

As described by forensic experts usually suicidal cut incisions are oblique, starting on the upper part of the left side of the neck (if the person is right-handed), below the angle of the jaw and terminating on the right side. Depth of the incision is more at the commencement while it becomes shallower as it crosses the throat [3,13]. This tailing of the wound is not characteristic of suicidal cuts. Hesitation cuts are associated with the main wound in the neck and the wrist in cases of suicidal cuts. They are often superficial and multiple. Suicide without hesitation is said to be rare but not unheard of [2,3,13]. Hesitation cuts have also been observed in homicidal cut-throat injuries and thus are said to be non-conclusive evidence of suicide [9,14].

One thing, however, can be said confidently that the depth of the cut will depend on the weapon used and the intention [5]. A cut-throat reaching up to the vertebra would be a homicidal wound [3,9]. A presence of a suicide note around the patient and an absence of defense wounds over the arms attribute to cut-throat injuries of suicidal intention [3,4]. The patient we treated lacked the oblique trail and tailing in direction however multiple hesitation marks were present both over the wrist and the neck from the present attempt only.

The square-shaped wound with irregular boundaries can be attributed to probably multiple attempts to go deeper by the patient. The patient had not left behind any message or note prior to his attempt. Multiple yet consistent description of the crime scene by close ones, a presence of many hesitation cuts, the handedness of the patient to cut his wrists, the confession

by the patient, a visit by the police at the scene and the detailed evaluation by a psychiatrist had led us to conclude beyond any reasonable doubt that this was indeed a suicidal attempt.

Tracheostomy has widely been accepted as a procedure of choice to secure the airway however it has been reported that if resources are inadequate, situation dire and the threat to airway visible, then an endotracheal tube has been “pushed” through the exposed wound as a means to secure the airway only to be followed later by a tracheostomy in the OT [12,15]. Sparing of the vital structures of the neck in spite a deep and big wound, cut injuries at two anatomical sites, a protracted pre-hospital time, enormous loss of blood before arrival to the hospital and prompt attempt to secure airway before aspiration along with aggressive fluid management make this case unique amongst the many suicidal cut-throat injuries and cut wrist seen and read in the literature.

CONCLUSION

This case teaches us that airway management and hemorrhage control should begin simultaneously in cases where we suspect airway compromise and catastrophic hemorrhage can cause death. In cases like ours where the airway is taking time to get secured, hemorrhage control should begin simultaneously with a person taking efforts to control bleeding and replenishing intravascular volume.

Informed Consent – The informed consent was obtained by the patient for this publication.

REFERENCES

1. Panchappa SA, Natarajan D, Karuppasamy T, Jeyabalan A, Ramamoorthy RK, Thirani S, *et al.* Cut throat injuries—a retrospective study at a Tertiary Referral Hospital. *International Journal of Otolaryngology and Head & Neck Surgery (IJOHNS)*. 2014;3:323-9
2. Marak FK, Singh TB. Suicidal cut throat—a case report. *JIAFM*. 2005;27:260-2.

3. Patil SS, Deokar RB, Vidhate SG, Tyagi S. An atypical case of suicidal cut throat injury. *Egypt J Forensic Sci*. 2016;6:492-5.
4. Solarino B, Buschmann CT, Tsokos M. Suicidal cut-throat and stab fatalities: three case reports. *Rom J Leg Med*. 2011;19:161-6.
5. Ahmed MA, Rao MS, Ahmed SM, Kumar MM. Cut throat injuries and its management: a clinical study of 48 patients. *J Evol Med Dent Sci*. 2015;4:6572-81.
6. De S, Sarma MK. Cut throat injuries at a tertiary referral hospital in Guwahati: a review of 165 cases. *IOSR Journal of Dental and Medical Sciences (IOSR-JDMS)*. 2016;15:36-41.
7. Gilyoma JM, Hauli KA, Chalya PL. Cut throat injuries at a university teaching hospital in northwestern Tanzania: a review of 98 cases. *BMC Emerg Med*. 2014;14:1.
8. Karger B, Niemeyer J, Brinkmann B. Physical activity following fatal injury from sharp pointed weapons. *Int J Legal Med*. 1999;112:188-91.
9. Ozdemir B, Celbis O, Kaya A. Cut throat injuries and honor killings: review of 15 cases in eastern Turkey. *J Forensic Leg Med*. 2013;20:198-203.
10. Ventura F, Bonsignore A, Gallo M, Fortunato F, De Stefano F. A fatal case of suicidal stabbing and cutting. *J Forensic Leg Med*. 2010;17:120-2.
11. Nicol AJ, Fagan JJ. Neck trauma. In: *Scott-Brown's Otorhinolaryngology and Head and Neck Surgery*. 8th ed. London: CRC Press; 2018.
12. Aich M, Alam AK, Talukder DC, Sarder MR, Fakir AY, Hossain M. Cut throat injury: review of 67 cases. *Bangladesh J Otorhinolaryngol*. 2011;17:5-13.
13. Shetty BSK, Padubidri JR, Bhandarkar AM, Shetty AJ, Shetty M. “Atypical Suicidal” cut throat injury—A case report. *J Forensic Leg Med*. 2009;16:492-3.
14. Kumar R, Madhusudhan R, Kumar K, Karthik D, Potli S. Cut throat injuries—A challenge for airway and anaesthetic management—Case report of 5 cases. *Int J Curr Sci Res*. 2011;1:137-8.
15. Fukube S, Hayashi T, Ishida Y, Kamon H, Kawaguchi M, Kimura A, Kondo T. Retrospective study on suicidal cases by sharp force injuries. *J Forensic Leg Med*. 2008;15:163-7.

Funding: None; Conflict of Interest: None Stated.

How to cite this article: Mani UA, Bhot FB, Sada E, Mishra P, Patil V, Ursekar R, *et al.* A case of multiple self-inflicted cuts to the neck and wrist presenting with airway compromise and catastrophic hemorrhage. *Indian J Case Reports*. 2019;5(6):551-553.

Doi: 10.32677/IJCR.2019.v05.i06.015