

## Aorto-occlusive disease causing pregnancy complications: A serendipitous diagnosis

Priya V Patil<sup>1</sup>, Kanishka Kumar<sup>2</sup>, Harini Jayaraman<sup>3</sup>, Bharat Reddy<sup>3</sup>

From <sup>1</sup>Associate Professor, <sup>2</sup>Assistant Professor, <sup>3</sup>Resident, Department of General Medicine, Grant Government Medical College and JJ Group of Hospitals, Mumbai, Maharashtra, India.

**Correspondence to:** Dr Kanishka Kumar, 1104b Olympia Towers Byculla West Mumbai - 400008, Maharashtra, India. E-mail: Kanishka205@gmail.com

Received - 22 October 2019

Initial Review - 09 November 2019

Accepted - 25 November 2019

### ABSTRACT

Takayasu arteritis or pulse-less disease is known to present in myriad forms. Here, we report the case of a 22-year-old young pregnant female who presented to us with pregnancy complications was finally diagnosed to have Takayasu Arteritis but not before her disease course took a lot of diagnostic turns. It highlights the fact that the disease is very variable in its presentation. The other unique presentations reported in literature along with a brief review of the treatment options are also given.

**Keywords:** Aortoarteritis, Pregnancy, Takayasu arteritis.

**T**akayasu is a chronic granulomatous arteritis affecting the aorta and its branches [1]. It presents with a variety of symptoms and in various age groups. There were a few atypical presentations.

This patient presented in an unusual way with hypertension and heart failure which appeared to be initially due to pregnancy-induced hypertension or Coarctation of Aorta. The diagnosis of Takayasu Arteritis was made at a late stage. It highlights the unique and unusual ways in which the disease can present and needs a high index of suspicion when unusual symptoms are the presenting symptoms

### CASE REPORT

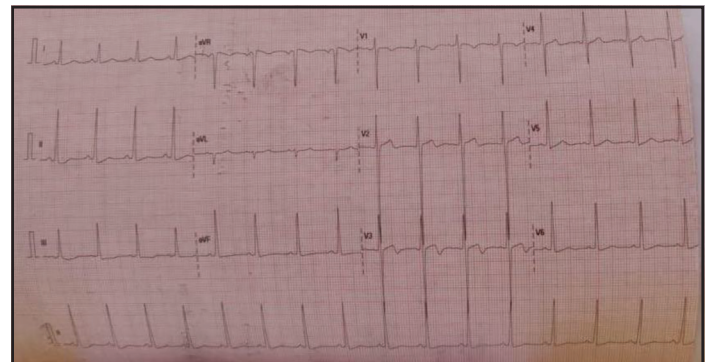
A 25-year-old patient presented to our hospital having been referred from another hospital with complaints of breathlessness and palpitation for the last few days. The patient was 3 months pregnant and had been asymptomatic till about 5 days before when she developed acute onset breathlessness associated with palpitations. It was New York Heart Association (NYHA) grade 3 and associated with swelling of both the legs. The patient had no prior history of breathlessness, chest pain, urine problems, palpitations or any other symptom suggestive of past cardiac or renal diseases.

On examination, she had pallor, bilateral pitting oedema, pulse rate of 100/min regular, and blood pressure of 200/100 mm-hg in both arms. The systemic examination showed S3 to be present on the left side and the peripheral pulses on the lower limb were reduced markedly in volume. Normal heart sounds were present in all four areas with no murmurs. Respiratory, neurological and abdomen examinations were within normal limits. Our working diagnosis was hypertensive heart disease with the possible

reasons for elevated blood pressure being an aorto-occlusive disease as the pulse volume was markedly different in the upper and lower limbs.

Complete blood counts, liver function test, kidney function test, thyroid profile, and urine examination were normal. X-ray chest was normal. Ultrasonography (USG) of the abdomen showed a live fetus with growth coordinates matching with the menstrual period. The ECG was suggestive of the left ventricular hypertrophy and LV strain pattern suggestive of an underlying old hypertensive disease (Fig. 1). 2 D Echocardiography was done which threw up interesting things. There was mild concentric hypertrophy of the left ventricle which was fitting in with the other clinical and laboratory findings but the echo also showed a 3.7 mm patent ductus arteriosus (PDA) and good left ventricular ejection fraction.

Looking for the anatomy of the aorto-occlusive disease, arterial and venous Doppler of the lower limbs was done which showed no major abnormalities. Magnetic Resonance Aortography (MRA) was done to look at the entire aortic anatomy. It suggested



**Figure 1:** ECG showing changes of the left ventricular hypertrophy.

an irregular narrowing of the suprarenal aorta with multiple superficial abdominal wall collaterals. There appeared to be complete occlusion of the infrarenal aorta with non-visualisation of the inferior mesenteric artery, aortic bifurcation and bilateral common iliac artery.

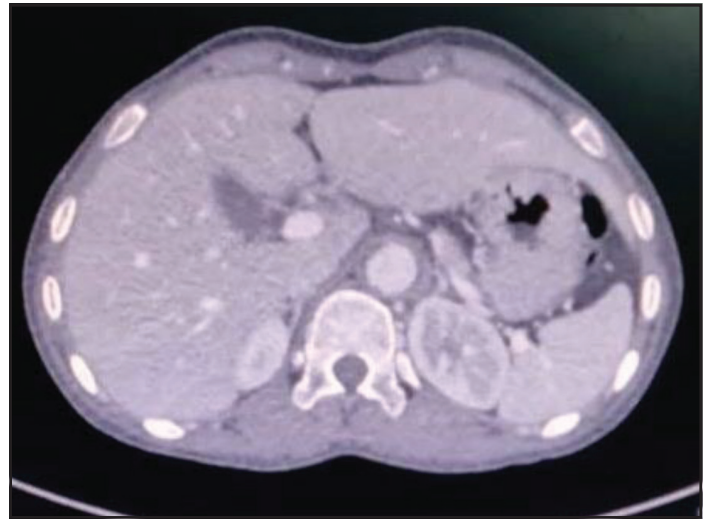
Lehrich's syndrome was coming into the picture. Our differentials at this stage were getting muddier. Coarctation of aorta was looking most likely initially which was more likely when we found a PDA. The presence of diffuse and irregular narrowing; however, was going against it. We thought it could be a case of congenital malformations of the abdominal aortic anatomy which could explain the formation of collateral as that would be a long drawn process. Our other differential at this stage was a procoagulant disorder with a paradoxical embolus coming down the PDA causing a Lehrich's syndrome or a thrombus being formed in situ due to a procoagulant disorder. However, these seemed less likely as collateral formation would take time and thromboembolism would definitely have lead to symptoms earlier, which the patient gave no history of, without collaterals. Takayasu Arteritis was our other differential.

Hypertension in all these conditions was explainable by the presence of renal artery blood supply compromise. The patient was given antihypertensive medications while all of this workup was going on and obstetrics opinion taken. They advised termination of the pregnancy in view of uncontrolled hypertension and risk to the mother in continuing the pregnancy. The patient was absolutely not ready for it and took discharge against medical advice.

Three months later, the patient presented to us again in the casualty after having delivered a macerated female child born vaginally at home. Her complaints at this time were generalised body swelling and palpitation. On examination, her blood pressure was 190/100mmhg in both arms with pallor and oedema present. Cardiovascular examination showed S3 and bilateral crepitations. We treated her with diuretics, beta-blockers, calcium channel blockers and alpha-blockers for her hypertension.

For finding her aetiology computed tomography (CT) Aortography was done which showed concentric homogenous symmetric long segment high attenuation mural thickening involving the arch of aorta, descending aorta, thoracic aorta, abdominal aorta, celiac axis, superior mesenteric artery and bilateral renal arteries (Fig. 2). There was the presence of Macaroni's sign on USG examination of the left common carotid and abdominal aorta. Complete thrombosis of the left renal artery with extensive adjacent collaterals and severe luminal narrowing at the origin of the right renal artery was also seen. There was complete thrombosis of the infrarenal abdominal aorta. A short segment dissection of the pulmonary artery (Main) and mural thickening with luminal narrowing involving the left anterior descending artery was appreciated.

The diagnosis was clear on the above radiological picture that we were dealing with a case of Takayasu Arteritis. The PDA was just an accidental co-finding. The patient was managed with antihypertensive drugs (nifedipine, losartan and furosemide),



**Figure 2: Computed tomography aortography showing thickening of the abdominal aorta.**

steroids (prednisolone) and sent up for stenting of the renal arteries. The patient was kept on medical management and planned for intervention for her renal artery lesions. However, the attendants were not willing for it.

## DISCUSSION

Takayasu arteritis is a chronic granulomatous disease-causing inflammation of the arteries, mainly the aorta and its branches, leading to stenosis, thickening of the vessel wall, fibrosis and thrombus formation [1]. Aneurysm formation may also result from chronic pathological changes [2]. This leads to end-organ damage causing the symptoms. It is found most commonly in East Asian countries. The maximum cases have been reported from Japan but the incidence is also seen in India. It is more common in females.

The clinical feature varies. The patient might present with constitutional symptoms such as fever, weight loss, myalgia, arthralgia and mild anaemia [3] with absent pulses which leads us to the diagnosis. The patients present with an end result of the stenotic and fibrotic lesions. Diminished or absent pulses may be seen with limb claudication and blood pressure differences. Hypertension is often present and represents the presence of renal artery stenosis. Cardiac manifestations such as aortic regurgitation resulting from dilatation of ascending aorta and congestive cardiac failure associated with hypertension and dilated cardiomyopathy may be seen [4]. Dyspnea, chest pain, myocardial infarction, retinopathy and erythema nodosum are other symptoms.

The diagnosis rests on the American College of Rheumatology criteria (ACR) [5] (Table 1). A diagnosis of Takayasu arteritis requires that at least 3 of the 6 criteria are met. There is another New angiographic classification of Takayasu arteritis [6] (Table 2). According to this classification, involvement of the coronary or pulmonary arteries should be designated as C (+) or P (+), respectively.

Sharma et al have proposed a few modifications in Ishikawa's criteria for the diagnosis of Takayasu arteritis. The proposed modifications include: (a) removal of the obligatory criteria of

**Table 1: American College of Rheumatology criteria [5] (1990) for the classification of Takayasu arteritis**

Criterion	Definition
Age at disease onset $\leq 40$ years	Development of symptoms or findings related to Takayasu arteritis at age $\leq 40$ years
Claudication of extremities	Development and worsening of fatigue and discomfort in muscles of 1 or more extremity while in use, especially the upper extremities
Decreased brachial artery pulse	Decreased pulsation of 1 or both brachial arteries
Blood pressure difference $> 10$ mmHg	Difference of $> 10$ mm Hg in systolic blood pressure between arms
Bruit over subclavian arteries or aorta	Bruit audible on auscultation over 1 or both subclavian arteries or abdominal aorta
Arteriogram abnormality	Arteriographic narrowing or occlusion of the entire aorta, its primary branches, or large arteries in the proximal upper or lower extremities, not caused by arteriosclerosis, fibromuscular dysplasia, or similar causes; changes usually focal or segmental

age less than 40 years; (b) inclusion of characteristic signs and symptoms as a major criteria; (c) removal of age in defining hypertension; (d) deletion of the absence of aorto-iliac lesion, in defining abdominal aortic lesion; and (e) an addition of coronary artery lesion in absence of risk factors. The criteria proposed consists of three major criteria including the left and the right mid subclavian artery lesions and characteristic signs and symptoms of at least one month duration and ten minor criteria — a high erythrocyte sedimentation rate, carotid artery tenderness, hypertension, aortic regurgitation or annuloaortic ectasia, pulmonary artery lesion, left mid common carotid lesion, distal brachiocephalic trunk lesion, descending thoracic aorta lesion, abdominal aorta lesion and coronary artery lesion. Presence of two major or one major and two minor criteria or four minor criteria suggests a high probability of Takayasu arteritis [7].

The treatment of Takayasu is mainly with steroids with at least half of the patients responding to it [8]. Other treatment options are methotrexate cyclosporine and myophenolate mofetil. Data from studies is mostly available on methotrexate with it showing good results even in patients who are non-responders to steroids [9,10]. The use of angiotensin-converting enzyme inhibitors should be carefully done in view of renal artery stenosis.

Takayasu Arteritis has been reported from India and other South East Asian countries apart from the majority of cases being reported from Japan. The presentations have been those as discussed in the paper before. Some unique and atypical presentations are worth mentioning. Liu H et al [11] have reported the case of a 3-month-old girl presenting with a constant and unexplained elevation of acute phase reactants which on investigations turned out to be Takayasu. The patient was treated with steroids, cyclophosphamide and mycophenolate.

**Table 2: New angiographic classification of Takayasu arteritis, Takayasu conference 1994 [6]**

Type I	Branches from the aortic arch
Type IIa	Ascending aorta, aortic arch and its branches
Type IIb	Ascending aorta, aortic arch and its branches, thoracic descending aorta
Type III	Thoracic descending aorta, abdominal aorta, and/or renal arteries
Type IV	Abdominal aorta and/or renal arteries

Quali S et al [12] described a rare manifestation of Takayasu arteritis in a 19-year-old black Tunisian man who presented with acute inferior myocardial infarction and complete atrioventricular block after occlusion from a giant aneurysm in the right coronary artery. The coronary artery disease was associated with aneurysmal dilations in the carotid, vertebral, and right renal arteries. Medical therapy improved thrombolysis in myocardial infarction flow in the area of the giant aneurysm from grade 1 to grade 3. Upon the diagnosis of Takayasu arteritis, intravenous methylprednisolone and oral prednisone therapy were started. Tacoy G et al [13] reported a similar case of coronary artery disease due to Takayasu which presented with cardiogenic shock. He had coronary, subclavian, celiac and total abdominal aorta occlusion.

Perera GN et al [14] reported the case of a 39-year-old woman who presented with chronic cough, haemoptysis and hoarseness of voice. She had left recurrent laryngeal nerve palsy and high inflammatory markers on the investigation. CT thorax revealed aortic wall thickening and traction bronchiectasis. 2D echocardiogram revealed grade 1 aortic regurgitation compatible with aortitis. She did not have weak peripheral pulses or a blood pressure discrepancy and did not meet the American College of Rheumatology (ACR) criteria for the diagnosis of Takayasu arteritis at this stage. Tuberculosis, syphilis and sarcoidosis were excluded. While awaiting angiography, she developed left arm claudication and pericardial effusion. Angiography revealed evidence of Takayasu arteritis and the absence of flow in the left subclavian artery. Takayasu arteritis was diagnosed at this stage after a period of eight months from the onset of initial symptoms. She is currently on prednisolone, azathioprine and aspirin.

Peredo R et al [15] reported a case of Takayasu which was diagnosed incidentally. The patient had thrombocytosis and acute phase reactants elevation for three years before the diagnosis and her specific complaints of claudication and pains were missed due to interpretation error. It was a chance CT chest which was done for pain in the chest which showed thickening and dilatation of the aorta and both coronary arteries consistent with Takayasu Arteritis. Gupta M et al [16] reported a similar case which was diagnosed indirectly where the patient, a young female, had been presenting for repeated attacks of erythema nodosum and constant elevation of ESR levels which necessitated a radiographic examination to look for underlying vasculitis even though the

patient had no symptoms or signs suggestive of a vasculitis. She turned out to be a type 3 Takayasu disease.

## CONCLUSION

Takayasu arteritis is a condition which should be kept in mind while dealing with a patient with unexplained hypertension, unequal pulses or organ threatening condition arising out of severe hypertension. It is diagnosed using the criteria mentioned above. Indian modification to the original criteria is very useful in our setting.

## REFERENCES

1. Lupi-Herrera E, Sanchez-Torres G, Marcushamer J, Mispireta J, Horwitz S, Vela JE. Takayasu's arteritis. Clinical study of 107 cases. *Am Heart J*. 1977;93:94-103.
2. Numano F, Okawara M, Inomata H, Kobayashi Y. Takayasu's arteritis. *The Lancet*. 2000;356:1023-5.
3. Hall S, Barr W, Lie JT, Stanson AW, Kazmier FJ, Hunder GG. Takayasu arteritis. A study of 32 North American patients. *Medicine*. 1985;64:89-99.
4. Johnston SL, Lock RJ, Gompels MM. Takayasu arteritis: a review. *J Clin Pathol*. 2002;55:481-6. doi:10.1136/jcp.55.7.481
5. Arend WP, Michel BA, Bloch DA, Hunder GG, Calabrese LH, Edworthy SM, *et al.* The American College of Rheumatology 1990 criteria for the classification of Takayasu arteritis. *Arthritis & Rheumatism*. 1990;33:1129-34.
6. Moriwaki R, Noda M, Yajima M, Sharma BK, Numano F. Clinical manifestations of Takayasu arteritis in India and Japan—new classification of angiographic findings. *Angiology*. 1997;48:369-79.
7. Sharma BK, Jain S, Suri S, Numano F. Diagnostic criteria for Takayasu arteritis. *Int J Cardiol*. 1996;54:S127-33.
8. Shelhamer JH, Volkman DJ, Parrillo JE, Lawley TJ, Johnston MR, Fauci AS. Takayasu's arteritis and its therapy. *Ann Intern Med*. 1985;103:121-6.
9. Sato EI, Lima DNS, Santo BEspirito, Hata F. Takayasu arteritis: treatment and prognosis in a University Center in Brazil. *Int J Cardiol*. 2000;75:S163-6.
10. Hoffman GS, Leavitt RY, Kerr GS, Rottem M, Sneller MC, Fauci AS. Treatment of glucocorticoid-resistant or relapsing Takayasu arteritis with methotrexate. *Arthritis Rheum*. 1994;37:578-82.
11. Liu H, Sun L, Upadhyaya RS, Chen Y, Ajoje OO. Case report: Takayasu arteritis in a 3-month-old Chinese girl. *Medicine*. 2018;97:e12637.
12. Ouali S, Kacem S, Fradj FB, Gribaa R, Naffeti E, Remedi F, *et al.* Takayasu arteritis with coronary aneurysms causing acute myocardial infarction in a young man. *Tex Heart Inst J*. 2011;38:183-6.
13. Tacoy G, Akyel A, Tavil Y, Cengel A. Patient with Takayasu arteritis presented as cardiogenic shock. *Future Cardiol*. 2010;6:889-93.
14. Perera GNd, Jayasinghe AC, Dias LD, Kulatunga A. Bronchiectasis and hoarseness of voice in takayasu arteritis: a rare presentation. *BMC Res Notes*. 2012;5:447. doi: 10.1186/1756-0500-5-447.
15. Peredo R, Vilá S, Goñi M, Colón E, Ríos-Solá G. Reactive thrombocytosis: an early manifestation of Takayasu arteritis. *J Clin Rheumatol*. 2005;11:270-3.
16. Gupta M, Singh K, Lehl SS, Bhalla M. Recurrent erythema nodosum: a red flag sign of hidden systemic vasculitis. *BMJ Case Reports*. 2013;ber-2013-009507.

*Funding: None; Conflict of Interest: None Stated.*

**How to cite this article:** Patil PV, Kumar K, Jayaraman H, Reddy B. Aorto-occlusive disease causing pregnancy complications: a serendipitous diagnosis. *Indian J Case Reports*. 2019;5(6):557-560.

Doi: 10.32677/IJCR.2019.v05.i06.017