

## Removal of accidentally ingested large foreign object via the anus after watchful waiting

Fumio Nakahara, Masashi Matsushima, Naoki Ogiwara, Hajime Mizukami, Masaya Sano, Shihou Yoshihara, Erika Teramura, Makiko Monma, Mia Fujisawa, Jun Koike, Hidekazu Suzuki, Takayoshi Suzuki

From <sup>1</sup>Department of Gastroenterology, Tokai University School of Medicine, Shimokasuya, Isehara, Kanagawa, Japan.

**Correspondence to:** Dr. Fumio Nakahara, Department of Gastroenterology, Tokai University School of Medicine, 143 Shimokasuya, Isehara, Kanagawa 259-1193, Japan. E-mail: nf738921@tsc.u-tokai.ac.jp

Received - 02 June 2019

Initial Review - 19 June 2019

Accepted - 11 October 2019

### ABSTRACT

One of the commonest complaints, for which a patient arrives in hospitals, is the presence of foreign body. It could be due to accidental ingestion or any other cause which leads to presences of a foreign body in the gastrointestinal tract. It is believed that foreign objects larger than 5–6 cm in size are unlikely to pass through the duodenum. Here, we describe a case wherein the patient accidentally swallowed a 7-cm-sized mouthguard that could not be removed by emergency upper gastrointestinal endoscopy but was subsequently removed via the anus after a period of watchful waiting.

**Keywords:** *Accidental swallowing, Endoscopy, Periodic imaging, Watchful waiting.*

The presence of a foreign object in the gastrointestinal tract is a condition frequently encountered in everyday clinical practice. It is believed that foreign objects measuring more than 5–6 cm in size are unlikely to pass through the duodenum [1]. Guidelines published by the European Society of Gastrointestinal Endoscopy (ESGE) relating to the removal of foreign bodies from the upper gastrointestinal tract recommend that those exceeding 5–6 cm in size should be removed by emergency endoscopy, and those that cannot be endoscopically removed should be treated on a case-by-case basis [1]. Here, we describe a case wherein the patient accidentally swallowed a 7-cm-sized mouthguard that could not be removed by emergency upper gastrointestinal endoscopy but was subsequently removed via the anus after a period of watchful waiting.

### CASE REPORT

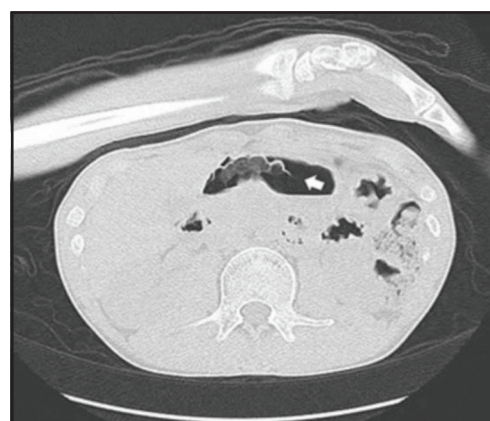A 29-year-old mentally retarded male patient was brought to our hospital after a staff member at the institution noticed that the mouthguard was not in his mouth after the evening meal on the previous night, and suspected that he had swallowed it. He was unable to communicate his wishes and was a resident of an institution for disabled people. The patient was had a history of epilepsy and was undergoing treatment with valproic acid. Owing to severe bruxism, he always wore a plastic mouthguard.

The patient's height was 173 cm, weight was 50.4 kg, temperature was 36.2°C, blood pressure was 127/73 mm-Hg, and heart rate was 69 bpm. Although he was alert and could perform strong movements, he was incapable of communicating with others. On abdominal examination, there was no tenderness,

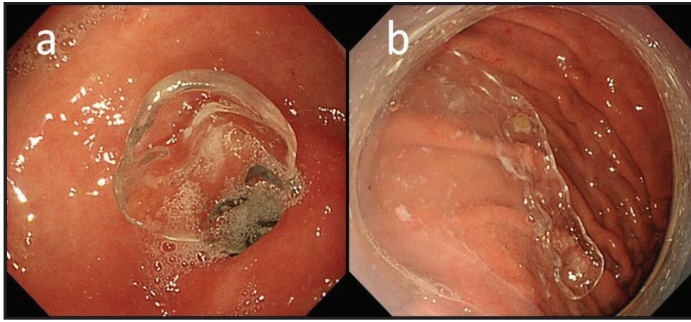
guarding or rigidity and bowel sounds were present. Other general and systemic examination was normal.

Plain computed tomography (CT) revealed a 7-cm mouthguard-shaped foreign object in the stomach, but no free abdominal gas was identified [Fig. 1]. Emergency upper gastrointestinal endoscopy was performed with the aim of removing the foreign object; the semi-transparent mouthguard was clearly visible and was sandwiched in the pyloric ring between the prepylorus and duodenum [Fig. 2].

Several failed attempts were made to remove the foreign object with grasping forceps and a snare. However, although it could be withdrawn from the stomach, its large size and curvature prevented its passage through the gastroesophageal junction. Attempts were then made to remove the object by attaching a skirt-shaped hood (D-Y0001-02, Olympus, Tokyo, Japan) and



**Figure 1:** Abdominal computed tomography (CT) on presentation intratransverse cross-section. The arrow shows a 7-cm mouthguard-shaped foreign object in the stomach.



**Figure 2: Emergency upper gastrointestinal endoscopy. (a)** The semitransparent mouthguard was visible in the prepylorus and duodenum, straddling the pyloric ring. **(b)** The mouthguard was withdrawn into the stomach with grasping forceps.

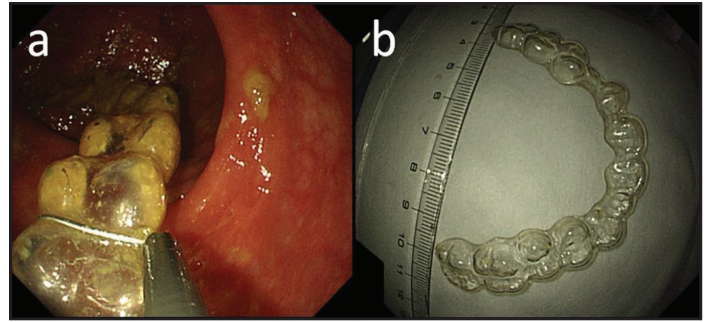
a wide-mouth hood (D-Y0001-02, Olympus, Tokyo, Japan) to the tip of the endoscope with or without an over tube (MD-48519, Sumitomo Bakelite, Tokyo, Japan).; However, it was still impossible to pass the object through the gastroesophageal junction. A bipolar snare was then used in an attempt to cut up the mouthguard within the stomach, but this attempt also failed. Since the foreign object had blunt edges and was larger than 5-6 cm in size, we decided to adopt a policy of watchful waiting in the hope that it would be eliminated naturally, with the proviso that emergency surgery would be performed if gastrointestinal obstruction or perforation occurred. Consequently, the patient was carefully monitored in the hospital.

In addition to monitoring the patient's symptoms and abdominal signs, we also carried out periodic abdominal X-rays and CT examinations. On day 5 post-admission, the mouthguard had reached the horizontal part of the duodenum, and on day 11, it seemed to have reached the terminal ileum. CT images failed to locate the object from the 18<sup>th</sup> day of admission. Therefore, we considered that the object had been incorporated into the feces in the colon. Lower gastrointestinal endoscopy, performed on day 19, successfully revealed the mouthguard was in the sigmoid colon; then, it was removed endoscopically using a snare from there [Fig. 3]. An abdominal X-ray on day 20 showed no free abdominal gas, and on day 21, the patient was discharged.

## DISCUSSION

Here, we report a rare case of successful removal of an ingested foreign body of approximately 7cm by colonoscopy after 19 days of watchful waiting. According to guidelines published by the American Society for Gastrointestinal Endoscopy (ASGE), over 80% of accidentally swallowed foreign objects in the gastrointestinal tract are naturally eliminated through the anus. However, the guidelines also indicate that "Objects longer than 6 cm are likely to have difficulty passing the duodenum and should be removed" and thus represent indications for urgent endoscopy [2].

Evidence for this stance was provided by Palta *et al.*, who found that foreign objects measuring >6 cm in length were retained in the stomach in 115 out of 147 cases, most of which were investigated after at least 48 h [3]. Because this previous study showed that it was difficult for foreign objects measuring



**Figure 3: Lower gastrointestinal endoscopy. (a)** The mouthguard was visible in the sigmoid colon and was removed endoscopically with a snare. **(b)** The removed mouthguard.

larger than 6 cm to be eliminated from the pylorus, their removal by emergency endoscopy is recommended.

According to the ESGE guidelines, endoscopy is performed to remove foreign objects in approximately 20% of cases, and surgery is performed in <1% [1]. These guidelines also recommend that sharp or magnetic foreign objects, batteries, or large or long foreign objects in the stomach should be removed by emergency endoscopy within 24 h. In terms of size, it is difficult for foreign objects measuring over 5–6 cm long to pass through the duodenal curve, and as there is a risk of perforation in 15–35% of cases, emergency endoscopy should be performed [1,2,4–8]. A range of devices can be used for foreign object removal by endoscopy; polypectomy snares and baskets are especially recommended for long foreign objects [1].

In our patient, we attempted to use grasping forceps and a polypectomy snare, but the passage through the cardia was not possible. We also considered the use of a basket but rejected this idea, because the size and shape of the foreign object made it impossible to grasp. We also attempted to cut up the mouthguard using a bipolar snare, but this was also unsuccessful. The recommended procedure is to try and grasp a foreign object by its edge; if an object is grasped centrally it may be difficult to move through the gastroesophageal junction into the esophagus [1]. In the present case, we grasped the mouthguard in different places, including its edges, but failed to pass it through the cardia.

Therefore, we adopted a policy of watchful waiting, with the proviso that surgery would be performed if an accident such as perforation and bowel obstruction occurred. However, it took 5 days for the mouthguard to pass through the duodenal curve, another 6 days to reach the terminal ileum, and further 8 days for it to reach the distal colon. A total of 19 days were required to eventually remove the object via the anus without surgery.

## CONCLUSIONS

This case showed that the foreign objects (larger than 6cm) in the stomach can possibly manage to pass through the duodenum and can be naturally eliminated without complications. However, there are certain associated factors such as the size and material of the object. Each and every such case should be carried out on case-by-case basis.

## REFERENCES

1. Birk M, Bauerfeind P, Deprez PH, Hafner M, Hartmann D, Hassan C, *et al.* Removal of foreign bodies in the upper gastrointestinal tract in adults: European Society of Gastrointestinal Endoscopy (ESGE) Clinical Guideline. *Endoscopy*. 2016;48:489-96.
2. ASGE Standards of Practice Committee, Ikenberry SO, Jue TL, Andersen MA, Appalaneni V, Banerjee S, Ben-Menachem T, *et al.* Management of ingested foreign bodies and food impactions. *Gastrointest Endosc*. 2011;73:1085-91.
3. Palta R, Sahota A, Bemarki A, Salama P, Simpson N, Laine L. Foreign-body ingestion: characteristics and outcomes in a lower socioeconomic population with predominantly intentional ingestion. *Gastrointest Endosc*. 2009;69:426-33.
4. Ambe P, Weber SA, Schauer M, Knoefel WT. Swallowed foreign bodies in adults. *Dtsch Arztebl Int*. 2012;109:869-75.
5. Dray X, Cattan P. Foreign bodies and caustic lesions. *Best Pract Res Clin Gastroenterol*. 2013;27:679-89.
6. Pfau PR. Removal and management of esophageal foreign bodies. *Tech Gastrointest Endosc*. 2014;16:32-9.
7. Sugawa C, Ono H, Taleb M, Lucas CE. Endoscopic management of foreign bodies in the upper gastrointestinal tract: A review. *World J Gastrointest Endosc*. 2014;6:475-81.
8. Telford JJ. Management of ingested foreign bodies. *Can J Gastroenterol*. 2005;19:599-601.

*Funding: None; Conflict of Interest: None Stated.*

**How to cite this article:** Nakahara F, Matsushima M, Ogiwara N, Mizukami H, Sano M, Yoshihara S, *et al.* Removal of accidentally ingested large foreign object via the anus after watchful waiting. *Indian J Case Reports*. 2019;5(5):484-486.

Doi: 10.32677/IJCR.2019.v05.i05.027