

Glanzmann's thrombasthenia: A rare case

Bijaya Mohanty¹, Ashok Sunder²

From ¹Consultant and Unit Head, ²Head of the Department, Department of Medicine, Tata Main Hospital, Jamshedpur, India

Correspondence to: Dr. Bijaya Mohanty, Consultant and Unit Head, Department of Medicine, Tata Main Hospital, Jamshedpur - 831001, Jharkhand, India. Email: bijayamohantytmh@gmail.com.

Received - 17 July 2019

Initial Review - 02 August 2019

Accepted - 21 August 2019

ABSTRACT

Glanzmann's thrombasthenia is an extremely rare autosomal recessive inherited bleeding disorder characterized by the impaired function of platelets leading to prolonged bleeding time. Patients may present with easy bruising, purpura, epistaxis, menorrhagia and gingival bleeding. Though the disease is rare, the prognosis is usually good with supportive care. Here, we report the case of Glanzmann's thrombasthenia in a young male who presented with complaints of gum bleeding, epistaxis and a history of easy bruising. The patient improved with symptomatic and supportive care. The patient got discharged and is doing well under regular follow-up.

Keywords: Bleeding gums, Epistaxis, Glanzmann's thrombasthenia

Glanzmann's thrombasthenia is a platelet function disorder that is caused by an abnormality in the genes for glycoproteins IIb/IIIa. These genes code for a group of linked proteins found on the surface of platelets, the glycoprotein IIb/IIIa receptor [1]. It is an extremely rare autosomal recessive disorder with an incidence of about 1 in 1,000,000 and an equal sex predilection. It is found more frequently in areas of the world where consanguineous marriage is common. Approximately, till now 500 cases have been reported in the literature but many cases go unreported [2].

The symptoms of Glanzmann's thrombasthenia usually begin at birth or shortly thereafter. Patients may present with easy bruising, purpura, epistaxis, gingival bleeding, and intermittent gastrointestinal bleeding. Sometimes they bleed profusely, especially after surgical procedures. The severity of the symptoms varies greatly depending on the type of the disease. Mortality due to hemorrhage in diagnosed patients is rare unless associated with trauma or other diseases. The prognosis is excellent with careful supportive care. Here, we report the case of Glanzmann's thrombasthenia in a young male who presented with complaints of gum bleeding, epistaxis and a history of easy bruising. He improved with symptomatic & supportive care and discharged. He is doing well & is under regular follow up.

CASE REPORT

A 14-year-old boy got admitted with complaints of bleeding gums and epistaxis for five days. He gives a history of mucosal bleeding and easy bruising off and on for the last 12.5 years. The first episode of epistaxis occurred at the age of fifteen months and he was treated at a local hospital with supportive care. His elder brother and sister died of epistaxis and massive haematemesis at 4.6

and 4 years respectively. So, his parents took him to a tertiary care centre where he was diagnosed as Glanzmann's thrombasthenia nine years back. He used to attend the local hospital for a follow-up though irregular. He is born of non-consanguineous marriage with uneventful vaccinations. His younger sister also gives a history of frequent episodes of epistaxis and bleeding after minor injury.

On examination, the patient is of average body built. There was mild pallor but no icterus, cyanosis, clubbing or lymphadenopathy. Pulse was 90/minute and regular, blood pressure was 110/70 mm-Hg. Systemic examination revealed no abnormality. Intraoral examination revealed spontaneous gingival bleeding from the upper and lower tooth causing stains all over the surface. Attached gingiva was firm and resilient in consistency (Fig. 1).

Blood examination showed haemoglobin of 12.4gm/dl, total leucocyte count of 13100/mm³ and platelet count of 303,000/mm³. Bleeding time was more than 15 minutes. His activated prothrombin time (aPTT) was 33.9 sec, International normalized ratio (INR) was 1.07 and thrombin time was 13.8 sec (All the parameters were in the normal range). His serum fibrinogen was 273.0 and clot retraction was absent. Platelet aggregometry showed a normal response to ristocetin and an abnormal response to collagen, adenosine diphosphate (ADP), arachidonic acid and epinephrine.

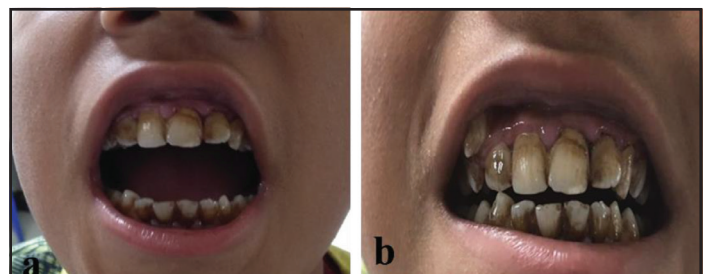


Figure 1: Gingival bleeding and stains

In view of normal platelet count and morphology, normal plasma clotting tests, normal levels of fibrinogen and deranged platelet function studies, the patient was diagnosed to have Glanzmann's thrombasthenia nine years back. Differential diagnoses considered were von Willebrand disease, Bernard-Soulier syndrome, and platelet secretory defects. Normal ristocetin induced platelet agglutination and normal platelet size ruled out Bernard-Soulier syndrome, a disorder of platelet adhesion. Factor VIII and von-Willebrand factor showed normal values. Flow cytometry expression of GP IIb/ IIIa was found to be 0% which confirmed the diagnosis of Glanzmann's Thrombasthenia.

The patient was treated with platelet transfusion and other supportive care, improved and discharged. He is under close follow-up and is doing well with supportive care. The patient was advised for transfusion with group-specific screened fresh blood/ FFP (Fresh frozen plasma)/ Cryoprecipitate and platelet-rich plasma or concentrate in the event of bleeding, prior to surgery or dental extraction. He was also advised to avoid intramuscular injection, aspirin and other drugs affecting platelet function. Importance of maintaining oral hygiene was explained to the patient and his parents.

DISCUSSION

Glanzmann's thrombasthenia was first documented in 1918 by Dr. Eduard Glanzmann, who described a functional abnormality of platelets with defective clot retraction [1]. It is an extremely rare autosomal recessive disorder with an incidence of about 1 in 1,000,000 with an equal sex predilection [2]. It is caused by an abnormality in the genes for glycoproteins IIb/IIIa which code for a group of linked proteins normally found on the surface of platelets. The gene responsible is carried on the long arm of chromosome 17 at q. George et al [3] divided Glanzmann's thrombasthenia into three groups as: Type- I: patients with less than 5% of GpIIb-IIIa, Type- II: patients with 5%-20% of GpIIb-IIIa and Type- III (variants) with normal amounts of GpIIb-IIIa, but functionally inactive. Our patient belongs to the type I category. Though this condition is more common in populations where intermarriage is common [4], our case is an exception.

This disease is characterised by normal or subnormal platelet count, prolonged bleeding time and a deficiency or absence of platelet aggregation [5,6]. This functional platelet deficiency manifests as a bleeding disorder characterized by mucocutaneous hemorrhage of varying severity like easy bruising, epistaxis and gingival hemorrhage, which was there in our patient. Bruising typically occurs following minor trauma [7]. It is characterised by prolonged bleeding time, decreased or absence of clot retraction, and abnormal platelet aggregation responses to physiologic stimuli which were positive for this patient. Glanzmann's thrombasthenia is definitively diagnosed by tests that determine the deficiency of the α IIb β 3 (GPIIb/ GPIIIa) receptor. These tests usually involve monoclonal antibodies and flow cytometry [8]. Genetic tests can identify the DNA mutations responsible for the disorder.

Spontaneous mucocutaneous bleeding is common and can lead to fatal bleeding episodes which happened in the siblings of our case. Control and prevention of bleeding among these patients pose a challenge to the treating physician. Treatment is primarily supportively mainly through local therapy, antifibrinolytics, and transfusions of fresh platelets or platelet concentrate [9,10]. Several reports suggest that platelet transfusion should be avoided except in case of severe bleeding as it may lead to platelet antibody development [11]. Tranexamic acid has also been used successfully in the form of a mouthwash or tablets after minor surgical procedures to inhibit postoperative bleeding episodes [12]. Prescribing medications that interfere in the normal function of platelets, such as aspirin and other nonsteroidal anti-inflammatory drugs (NSAIDs) should be avoided. Venkat V et al also reported a case of Glanzmann's thrombasthenia who presented with complaints of spontaneous gingival bleeding and improved with supportive care [13].

Gelatin sponge or gauze, antifibrinolytic agents such as topical thrombin, and YAG laser can be used to control minor bleeding. Desmopressin (DDAVP) has been tried in some patients with Glanzmann's thrombasthenia and may shorten the bleeding time in patients with Type 2 only. Bone marrow transplantation can be considered in patients with severe cases unresponsive to conventional therapies. Gene therapy and stem cell transplantation offer a potential cure for this disease, but both are costly and remain experimental at this point. Carrier detection by protein analysis and direct gene analysis is important to control the disorder in family members.

CONCLUSION

Spontaneous mucocutaneous bleeding is common and can lead to fatal bleeding episodes in patients with Glanzmann's Thrombasthenia. Although Glanzmann's thrombasthenia is one of the rare bleeding disorders, awareness of this condition is important. Early diagnosis and prompt treatment carry a good prognosis. People should be counseled to avoid consanguineous marriage. The patient and their caregivers should be educated to avoid bleeding episodes by avoidance of anti-platelet drugs, and trauma. Control and prevention of bleeding among these patients pose a challenge to the treating physician.

REFERENCES

1. Rao, A.K., Coller, B.S. Hereditary qualitative platelet disorders. In Williams Hematology, 9th Edition, Kaushansky, K., Lichtman, M.A., Prchal, J.T., Levi, M.M., Press, O.W., Burns, L.J., Caligiuri, M.A., eds. McGraw-Hill, Inc., New York, 2015, pps 2039-2071.
2. Mitchell WB and French DL. Glanzmann Thrombasthenia. In: The NORD Guide to Rare Disorders, Philadelphia: Lippincott, Williams and Wilkins; 2003:383-384.
3. George JN, Caen JP, and Nurden AT. Glanzmann's Thrombasthenia: The Spectrum of Clinical Disease Blood 1990;75:1383-95.
4. Patel N, Modi M, Asari.D. Glanzmann thrombasthenia: A rare autosomal recessive bleeding disorder. Int J Sci Res. 2015;4.

5. Sebastiano C, Bromberg M, Breen K, Hurford MT. Glanzmann's thrombasthenia Report of case and review of the literature. *Int J Clin Exp Pathol.* 2010;3:443-7.
6. Gopalakrishnan A, Veeraraghavan R, Panicker P. Hematological and surgical management in Glanzmann's thrombasthenia: A case report. *J Indian Soc Pedod Prev Dent.* 2014;32(2):181-4.
7. Bisch FC, Bowen KJ, Hanson BS, Kudryk VL, Billman MA. Dental considerations for a Glanzmann's thrombasthenia patient: case report. *J Periodontol.* 1996;67:536-40.
8. Solh T, Botsford A, Solh M. Glanzmann's thrombasthenia: Pathogenesis, diagnosis, and current and emerging treatment options. *J Blood Med.* 2015;6:219-7.
9. Mehta DN, Bhatia R. Dental considerations in the management of Glanzmann's thrombasthenia. *Int J Clin Pediatr Dent.* 2010;3:51-6.
10. Nurden AT. Glanzmann thrombasthenia. *Orphanet J Rare Dis.* 2006; 1:10.
11. Varkey I, Rai K, Hegde AM, Vijaya MS, Oommen VI. Clinical Management of glanzmann's thrombasthenia: A Case Report. *J Dent (Tehran).* 2014;11:242-7.
12. Sindet-Pedersen S, Ramstrom G, Bernvil S, Blomback M. Hemostatic effect of tranexamic acid mouthwash in anticoagulant-treated patients undergoing oral surgery. *N Engl J Med.* 1989;320:840-3.
13. Venkat V, Kalluri S, Hanumantha SRB. Glanzmann's thrombasthenia – A rare case report of spontaneous gingival bleeding. *J Indian Acad Oral Med Radiol* 2018;30:88-91.

Funding: None; Conflict of Interest: None Stated.

How to cite this article: Mohanty B, Sunder A. Glanzmann's thrombasthenia: a rare case. *Indian J Case Reports.* 2019;5(5):438-440.

Doi: 10.32677/IJCR.2019.v05.i05.013