

## Severe hypersensitivity reaction with erythromycin ethylsuccinate: A case report

Deep Inder<sup>1</sup>, Pawan Kumar<sup>2</sup>

From <sup>1</sup>Professor, Department of Pharmacology, Faculty of Dentistry, Jamia Millia Islamia <sup>2</sup>Additional Director, Department of Community Health Administration, Directorate General of Health Services, Karkardooma, New Delhi, Delhi, India.

**Correspondence to:** Dr. Deep Inder, Department of Pharmacology, Faculty of Dentistry, Jamia Millia Islamia, New Delhi - 110025, India. E-mail: drdeep73@gmail.com

Received - 26 July 2019

Initial Review - 19 August 2019

Accepted - 23 August 2019

### ABSTRACT

Erythromycin is considered to be one of the safest antimicrobials exhibiting good activity against Gram-positive aerobes and some Gram-negative aerobes but rare cases of hypersensitivity reactions to erythromycin alone or with its base (esteolate or ethylsuccinate) can occur. Here, we report the case of severe hypersensitivity reaction in a female patient with upper respiratory tract infection and underwent treatment with erythromycin ethylsuccinate (400mg TDS). Twenty-four hours after the initiation of therapy with erythromycin ethylsuccinate, the patient developed severe rash starting from the nape of the neck spreading throughout the body with generalized pruritus and mild icterus. Marked improvement was noticed within 2 days after cessation of erythromycin ethylsuccinate. Physicians must be aware of the adverse effects of erythromycin ethylsuccinate before prescribing the drug.

**Keywords:** Drug, Rash, Erythromycin ethylsuccinate, Hypersensitivity.

Erythromycin, the first macrolide introduced in 1952 is considered to be one of the safest antimicrobials exhibiting good activity against Gram-positive aerobes and some Gram-negative aerobes. Rare cases of hypersensitivity reactions (0.4% to 3%) to erythromycin alone or with its base (esteolate or ethylsuccinate) have been reported in the literature [1]. Erythromycin ethylsuccinate is an ester of erythromycin and suitable for oral administration. The patient exhibiting hypersensitivity reaction to one member of macrolides is likely to have cross-sensitivity to the other members of the same class [2,3]. The adverse effects of macrolides may manifest in the form of immediate or delayed type of hypersensitivity reactions e.g. anaphylaxis, angioedema, urticaria, maculopapular rash, fixed drug eruptions, contact dermatitis, toxic epidermal necrolysis, etc [4,5,6]. This aim of this case report is to sensitize and warn prescribers and consumers to be aware of serious adverse effects associated with erythromycin ethylsuccinate.

### CASE REPORT

A 29-years-old female patient reported to the department with erythematous maculopapular rash on the nape of her neck for 2 days. She had given history of upper respiratory tract infection (sore throat) with high-grade fever  $>101^{\circ}\text{F}$  and chills for the last two days, for which, she self-medicated with erythromycin ethylsuccinate (400mg twice a day) (Fig. 1) along with paracetamol (500mg thrice a day). Twenty-four hours after the start of erythromycin ethylsuccinate, the patient developed severe erythematous maculopapular rash on the nape of her

neck spreading throughout the body, with extensive generalized pruritus (Fig. 2 and 3). The patient started feeling dyspnoeic within 3 hours of the start of symptoms. The patient rushed to the casualty of a tertiary care teaching hospital in South Delhi. There was no history/evidence suggestive of allergy to any drug.

On clinical examination, the patient was highly anxious and dyspnoeic. The vital parameters were as follows: blood pressure-81/50 mm of Hg, pulse rate-68/min and respiratory rate of  $>26$ . Maculopapular rashes were seen throughout the body with generalized pruritus and redness. The patient developed some puffiness of the face and mild icterus in the eyes.

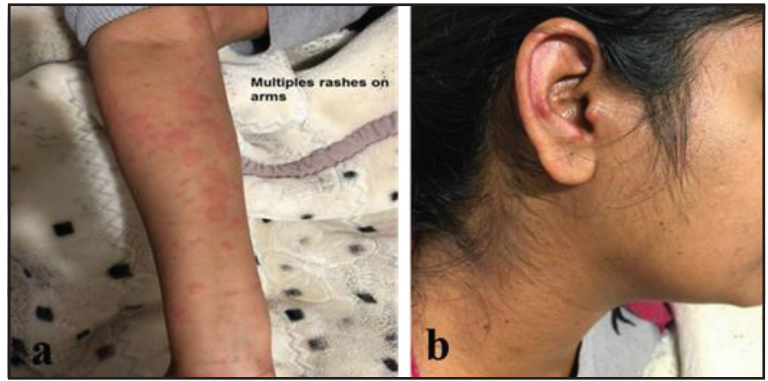
The patient was immediately put on oxygen through an oxygen mask and intramuscular injection of 0.5 ml of adrenaline (1:1000) was given followed by slow intravenous injection of chlorpheniramine (20mg), over 1 minute. Slow intravenous

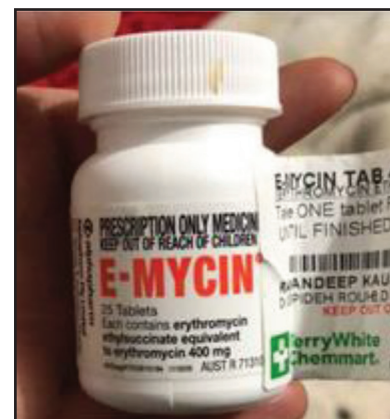
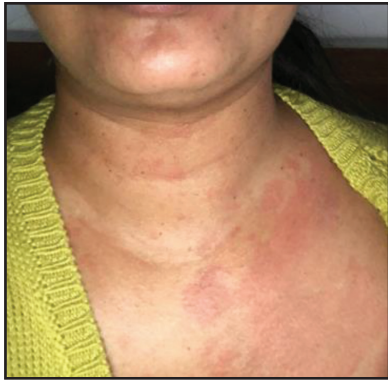
Figure 1: Erythromycin ethyl-succinate.



**Figure 2: Maculopapular rash on the body.**



**Figure 3: Maculopapular rashes on the (a) arms and (b) ear of the patient.**

injection of hydrocortisone (200mg) was added after 10 minutes. An extensive evaluation was done to determine the cause of an allergic response. Blood sample of the patient was collected for routine blood tests including liver function tests. Liver function tests were found to be slightly deranged (Alanine aminotransferase (ALT) was 29 IU/L, aspartate aminotransferase (AST) was 48 IU/L and alkaline phosphatase (ALP) was 142 U/L), with total bilirubin levels 1.9 mg/Dl, but could not be compared since base levels were not available.

Improvement started within 90 min of initiation of therapy. Marked improvement was noticed within 2 days after cessation of erythromycin ethylsuccinate. No rechallenge was given to the patient with erythromycin ethylsuccinate. Anti-streptolysin O titre was also done after 3 weeks to confirm likely streptococcal infection, which came out to be negative (<200 IU). Naranjo causality assessment scale [7] revealed the total score as 6, which falls under “Probable”, means that there is a probability that the above event is related to hypersensitivity to erythromycin ethylsuccinate. The patient was then labeled with a final diagnosis of “Erythromycin ethylsuccinate induced hypersensitivity reaction.” No untoward incident was reported during follow-up over 3 weeks.

## DISCUSSION

Adverse Drug Reactions (ADRs) are the leading cause of hospital admissions to the extent of 5-10% cases. Therefore, it is essential to recognize ADR and to establish the causal relationship between the drug and the adverse event [8]. Erythromycin ethylsuccinate is widely prescribed macrolide antimicrobial for upper and lower respiratory tract infections. ADRs are although rare but have been seen in patients with certain underlying associated risk factors such as middle-aged female, elderly, positive history of cardiac disease especially arrhythmias and patient with compromised renal and hepatic functions. As suggested from a case report published in the literature, macrolide antibiotics can interact to varying degrees with many commonly prescribed drugs due to inhibition of the CYP3A4 metabolic pathway [9].

The most commonly prescribed macrolide being erythromycin (esteolate or ethylsuccinate) tends to inhibit CYP3A4, thus liable to cause various drug interactions. The common interactions of erythromycin ethylsuccinate reported in the literature are

due to concomitant use of statins (risk of rhabdomyolysis and acute renal failure), triazolam, pimozide, warfarin, cyclosporine, theophylline, carbamazepine (increased plasma levels due to inhibition of drug metabolism), cisapride, quinidine and second-generation antihistaminics e.g. terfenadine, astemizole, cetirizine, levocetirizine (prolongation of QT interval in ECG, manifesting as tachycardia and cardiac arrhythmias) [10,11].

Patients receiving concomitant erythromycin ethylsuccinate and microsomal enzyme inhibitor drug have 5 times more risk of sudden deaths as compared to erythromycin ethylsuccinate alone [12,13]. Hence, it is advised not to prescribe erythromycin ethylsuccinate concomitantly with microsomal enzyme inhibitor drugs as mentioned above. Erythromycin ethylsuccinate alone can be prescribed if indicated in such cases with extreme caution by suggesting baseline ECG, electrolyte levels, liver, and renal function tests and also monitoring of the levels after intake of erythromycin. In patients with a history suggestive of skin rash following any macrolide dose, the offending drug should not be prescribed. Erythromycin ethylsuccinate in such cases should be replaced by another suitable antibiotic group [13].

In the present case report, the symptoms of the patient raise the possibility of likely immune-mediated hypersensitivity. Since the patient refused to take rechallenge with erythromycin in any form (esteolate or ethylsuccinate), it is difficult to comment whether the symptoms appeared due to hypersensitivity to erythromycin or its base ethylsuccinate. Limited data is available in the literature to support this fact.

## CONCLUSION

Erythromycin base (ethylsuccinate) must be incorporated into the list of drugs causing rash and liver function disturbances. Factors like self-medication and availability of antibiotics as over the counter drugs as in the present case report needs to be curbed in society at the earliest to prevent serious adverse effects including development of resistant strains in the community. Consumers and prescribers must be aware of likely ADRs encountered with the use of erythromycin or its base ethylsuccinate and to exercise caution before use or prescribing. There is a need to create awareness for right reporting of ADRs by drug manufacturers, prescribers and voluntary reporting by consumers so as to withdraw offending drug/base from the market by regulatory

authorities if adequate data gets generated at the global platform with significant adverse evidence.

## REFERENCES

1. Araujo L, Demoly P. Macrolides allergy. *Curr Pharm Des.* 2008;14:2840-62.
2. San Pedro de Saenz B, Gómez A, Quiralte J, Florido JF, Martín E, Hinojosa B. FDE to macrolides. *Allergy.* 2002;57:55-6.
3. Benahmed S, Scaramuzza C, Messaad D, Sahla H, Demoly P. The accuracy of the diagnosis of suspected macrolide antibiotic hypersensitivity: results of a single blinded trial. *Allergy.* 2004;59:1130-3.
4. Milković-Kraus S, Macan J, Kanceljak-Macan B. Occupational allergic contact dermatitis from azithromycin in pharmaceutical workers: a case series. *Contact Dermatitis.* 2007;56:99-102.
5. Mori F, Barni S, Pucci N, Rossi E, Azzari C, de Martino M, Novembre E. Sensitivity and specificity of skin tests in the diagnosis of clarithromycin allergy. *Ann Allergy Asthma Immunol.* 2010;104:417-9.
6. Seitz CS, Bröcker EB, Trautmann A. Suspicion of macrolide allergy after treatment of infectious diseases including *Helicobacter pylori*: results of allergological testing. *Allergol Immunopathol.* 2011;39:193-9.
7. Agbabiaka TB, Savovic J, Ernst E. Methods for causality assessment of adverse drug reactions: A systematic review. *Drug Saf.* 2008;31:21-37.
8. Sekhar MS, Mary CA, Anju PG, Hamsa NA. Study on drug related admissions in a tertiary care hospital in South India. *Saudi Pharm. J.* 2011;19:273-8.
9. Von Rosensteil NA, Adam D. Macrolide antibacterials. Drug interactions of clinical significance. *Drug Saf.* 1995;13:105-22.
10. Patel AM, Shariff S, Bailey DG, Juurlink DN, Gandhi S, Mamdani M, et al. Statin toxicity from macrolide antibiotic coprescription: a population-based cohort study. *Ann Intern Med.* 2013;158:869-76.
11. Abo-Salem E, Fowler J, Attari M, Cox C, Perez-Verdia A, Panikkath R, et al. Antibiotic-induced cardiac arrhythmias. *Cardiovasc Therapeut.* 2014; 32:19-25.
12. Ray WA, Murray KT, Meredith S, Narasimhulu SS, Hall K, Stein CM. Oral erythromycin and the risk of sudden death from cardiac causes. *N Engl J Med.* 2004;351:1089-96.
13. Svanstrom H, Pasternak B, Hviid A. Use of azithromycin and death from cardiovascular causes. *N Engl J Med.* 2013;368:1704-12.

*Funding: None; Conflict of Interest: None Stated.*

**How to cite this article:** Inder D, Kumar P. Severe hypersensitivity reaction with erythromycin ethylsuccinate: A case report. *Indian J Case Reports.* 2019;5(5):429-431.

Doi: 10.32677/IJCR.2019.v05.i05.010