

Parathyroid adenoma in a young female presenting with craniofacial brown tumor and acute pancreatitis – A case report

Arunabha Chakravarti¹, Indu Shukla², Pravesh Mehra³, Shailaja Shukla⁴

From ^{1,3,4}Director Professor, ²Senior Resident, Department of ^{1,2}Otorhinolaryngology and Head and Neck Surgery, ³Dental and Oral Surgery, ⁴Pathology, Lady Hardinge Medical College, New Delhi, India.

Correspondence to: Dr. Arunabha Chakravarti, Department of Otorhinolaryngology and Head and Neck Surgery, Lady Hardinge Medical College, Opposite Shivaji Stadium Bus Stand, New Delhi - 110001, India. E-mail: drachakravarti@yahoo.co.in

Received - 16 June 2019

Initial Review - 08 July 2019

Accepted - 13 August 2019

ABSTRACT

Solitary Parathyroid adenomas have a diverse clinical presentation. They may be asymptomatic or may sometimes lead to extensive bony resorption and replacement of bone by fibrous tissue, also known as a brown tumor. Brown tumor is a relatively rare presentation of primary hyperparathyroidism and is even rarer in a younger age group. Here, we report the case of a 20-year-old female presenting with craniofacial brown tumor and during the course of hospital stay; she also developed an attack of acute pancreatitis due to hyperparathyroidism. This case report emphasizes the importance of a complete investigative work up in patients presenting with maxillofacial bony lesions for early diagnosis and planning of definitive management.

Keywords: Brown tumor, Craniofacial, Parathyroid adenoma, Primary hyperparathyroidism.

Primary hyperparathyroidism is one of the most common causes of hypercalcemia with an estimated prevalence rate of one to seven per 1000 individuals [1]. It is caused by solitary parathyroid adenomas in about 85% of cases [2]. It is most commonly seen in females over 50 years of age and is usually asymptomatic or may present with non-specific systemic symptoms [3]. Elevated parathormone levels may also cause osteolytic lesions in bones surrounded by giant cells, a condition known as Brown tumor, which may be seen in around 5% cases of hyperparathyroidism [4].

We are presenting the case of a 20-year-old female patient who presented with a gradually progressive swelling over the mandible and palate. A complete investigative workup revealed a solitary left inferior parathyroid adenoma leading to primary hyperparathyroidism. This case report emphasizes on the importance of keeping a differential diagnosis of a parathyroid adenoma in mind in case of a patient presenting with unexplained bony lesions so that a timely intervention can be made before there is a multi-organ involvement and the prognosis becomes less favorable.

CASE REPORT

A 20-year-old female patient presented to the outpatient department with a complaint of swelling over the chin area for 3 months duration. It was gradually progressive in size and had led to facial disfigurement (Fig. 1a). The swelling was painful to touch but not associated with any discharge. Another swelling was noted by the patient over the left side of the palate for the last

2 months which was painless and did not cause any difficulty in chewing or swallowing food (Fig.1b). She also had complaints of lethargy and loss of appetite.

On general physical examination, the patient was of thin build with no pallor or lymphadenopathy. The vital signs were normal. On local examination, a diffuse, approximately 3 X 3 cm, bony-hard, tender swelling was present over the mandible with irregular margins and no erosion of overlying skin. No pus discharge was seen from the swelling. On oral cavity examination, an approximately 2 X 1 cm firm to hard swelling was seen on the left side of the palate which was non-tender and with no ulceration of the overlying mucosa.

The patient underwent routine blood investigations which revealed an elevated total calcium level of 14.5 mg/dL (normal range- 8.5-10.2 mg/dL) and ionized calcium of 2.2 mg/dL.

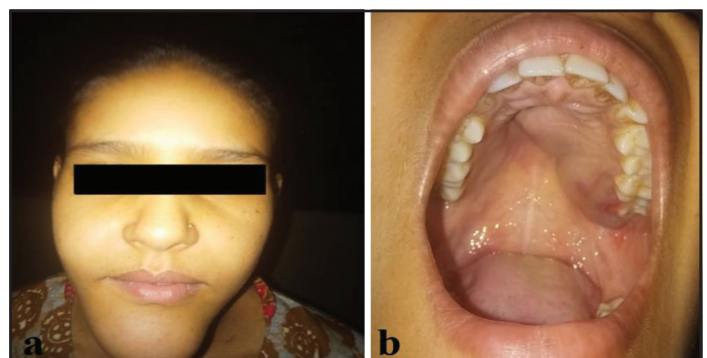

Figure 1: Clinical photograph of the patient showing (a) swelling over the mandible and (b) lesion over the left side of hard palate.

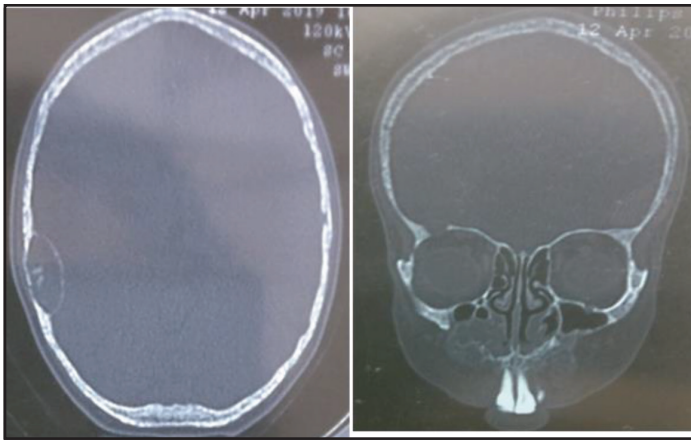


Figure 2: NCCT head showing osteolysis in right temporal bone and bilateral maxilla.

Fine needle aspiration cytology (FNAC) was done from the swelling over the mandible which was suggestive of Brown tumor of hyperparathyroidism. Serum parathyroid hormone levels were then investigated which came out to be 568 pg/ml (normal range-12-88 pg/ml). Vitamin D levels were 8.9 ng/mL. Thyroid function tests were within normal limits (Thyroid Stimulating Hormone- 4.25 mIU/ml). Liver function tests and renal function tests were also within normal limits (Blood urea-10 mg/dL, serum creatinine- 0.92 mg/dL). Plain radiographs of the skull revealed salt and pepper appearance of the skull along with osteolytic lesion in mandible and maxilla. Anon-contrast computed tomography (NCCT) scan of the head was suggestive of osteolytic lesions with cortical thinning and expansion of outer and inner table of the skull. Osteolytic lesions with multiloculations were also seen in maxilla and mandible (Fig. 2). These features were highly suggestive of craniofacial Brown tumor secondary to hyperparathyroidism. On further eliciting history to rule out any syndromic association, we found no symptoms of galactorrhea, menstrual irregularities or acral enlargement.

Ultrasound neck was suggestive of a well defined hypoechoic lesion of size 14 X 7 mm over the inferior pole of the left thyroid gland with internal vascularity suggestive of a parathyroid adenoma. Contrast-enhanced CT scan (CECT) of the neck showed a well-defined 10.4 X 8.8 X 17.7 mm lesion over the left lower pole of the thyroid gland with avid contrast uptake on arterial

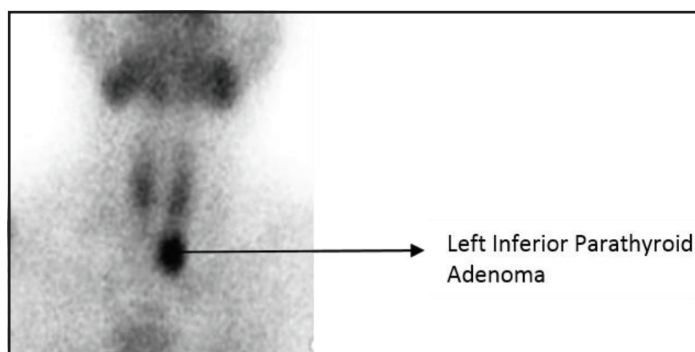


Figure 4: Tc99^m Sestamibi scan showing the left inferior parathyroid adenoma

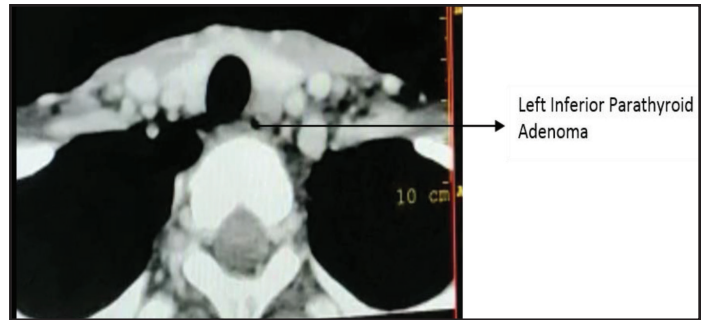


Figure 3: CECT Neck showing the left inferior parathyroid adenoma.

phase and washout on delayed phase suggestive of parathyroid adenoma (Fig. 3). A Technetium SESTAMIBI Tc99^m scanning was suggestive of an area of increased uptake at the lower pole of left thyroid lobe interpreted as left inferior parathyroid adenoma (Fig. 4).

During the course of hospital stay, the patient developed an attack of severe acute abdominal pain. Serum amylase and serum lipase levels were found to be elevated. CT scan of the abdomen was suggestive of focal pancreatic enlargement with indistinct margins due to inflammation. There was no evidence of renal calculi. A diagnosis of acute pancreatitis was made and she was administered intravenous antibiotics. She was given tablet alendronate sodium for a period of 10 days and tablet calcium with Vitamin D supplements. On stabilizing the general condition, she was taken up for left inferior parathyroidectomy under general anesthesia. Intraoperatively, the left inferior parathyroid gland could be identified at the lower pole of left thyroid lobe (Fig. 5a). It was removed in toto and the specimen was sent for the frozen section which was suggestive of parathyroid adenoma (Fig. 5b). The incision was closed after confirmation by frozen section. An intraoperative serum sample was sent for parathormone levels after the removal of the adenoma and the values came out to be 168 pg/ml which showed a marked decrease as compared to the preoperative values. Histopathological examination confirmed the diagnosis of parathyroid adenoma.

Parathormone levels on a postoperative day 1 were 7.6 pg/ml. Serum calcium levels were monitored postoperatively which showed a gradual decline to a level of 7.8 mg/dL on the third

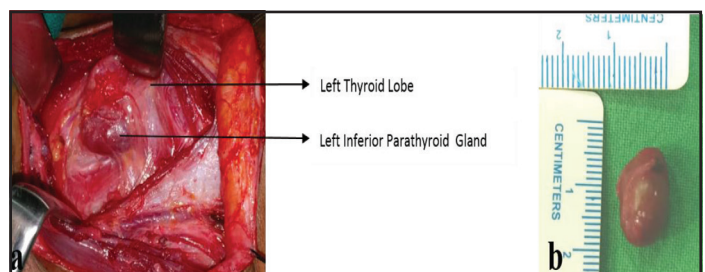


Figure 5: (a) Intraoperative photograph showing the left inferior parathyroid gland and (b) photograph of the excised parathyroid gland specimen

postoperative day. The patient was started on oral calcium and Vitamin D supplements and was discharged on postoperative day seven when the serum calcium levels were normalized. The patient has been on a regular follow-up since then and is currently asymptomatic.

DISCUSSION

Parathyroid adenomas are the most common cause of primary hyperparathyroidism [5]. They lead to an elevated level of parathyroid hormone in the blood which causes an increase in the serum calcium levels by increased osteolytic resorption of bones. These adenomas may be asymptomatic in nature or sometimes may present with non-specific systemic symptoms like lethargy, malaise, and loss of appetite. They are usually seen in the age group of 40-80 years with a female preponderance in the ratio of 3:1 [6]. Association with Brown tumor due to osteolytic resorption of bones and replacement by fibrous tissue is seen in only around 5% of cases [7].

Brown tumor is a non-neoplastic lesion which needs to be differentiated radiologically from bone cysts, fibrous dysplasia, and metastasis. They are encountered most commonly in patients with uncontrolled hyperparathyroidism either primary (3-4%) or secondary (1-2%) [8]. The case presented above describes a 20-year-old female patient with extensive craniofacial bony involvement. Brown tumor mostly involves the long bones and is infrequently encountered in the craniofacial region [9]. This case highlights the younger age of presentation, a comparatively rare clinical picture with craniofacial Brown tumor and the importance of a complete investigative workup required to find the cause of hypercalcemia and bony deformities.

Due to a paucity of knowledge regarding the diagnostic workup, many cases of parathyroid adenomas are not identified until a late stage where the prognosis becomes unfavorable due to multiple organ involvement. A definitive diagnosis is only possible after a thorough clinical, radiological and biochemical analysis. The definitive treatment of a parathyroid adenoma is surgical excision of the involved parathyroid gland to remove the focus of elevated parathyroid hormone. Postoperatively, the patient has to be monitored for 'hungry bone syndrome' wherein there is a decline in the serum calcium levels due to rapid resorption of calcium by the involved bones. Supplementation of calcium is usually required in the postoperative phase.

To summarise, a differential diagnosis of parathyroid adenoma should always be kept in mind in case of a middle-aged patient presenting with unexplained lytic bony lesions or pathological fractures to facilitate early diagnosis and definitive management.

CONCLUSION

This case report emphasizes the rare clinical presentation of parathyroid adenoma in a young female patient with craniofacial brown tumor and acute pancreatitis. It also highlights the importance of a complete diagnostic workup in patients with unexplained bony lesions to diagnose the etiology and to initiate timely intervention.

REFERENCES

1. Yeh MW, Ituarte PH, Zhou HC, Nishimoto S, Liu IL, Harari A, *et al.* Incidence and prevalence of primary hyperparathyroidism in a racially mixed population. *J Clin Endocrinol Metab.* 2013;98:1122-9.
2. Udelsman R. Six hundred fifty-six consecutive explorations for primary hyperparathyroidism. *Ann Surg.* 2002;235:665-70.
3. Adami S, Marcocci C, Gatti D. Epidemiology of primary hyperparathyroidism in Europe. *J Bone Miner Res: Off J Am Soc Bone Miner Res.* 2002;17: N18-23.
4. Chowdhury S, Aggarwal A, Mittal N, Shah A. Brown tumor of hyperparathyroidism involving craniomaxillofacial region: a rare case report and literature review. *Minerva Stomatol.* 2013;62(9):343-8.
5. Shetty AD, Namitha J, James L. Brown tumor of mandible in association with primary hyperparathyroidism: a case report. *J Int Oral Health.* 2015;7:50-2.
6. Keyser JS, Postma GN. Brown tumor of the mandible. *Am J Otolaryngol.* 1996;17:407-10.
7. Popovik-Monevska D, Bozovik-Dvojakovska S, Popovski V, Benedetti A, Grchev A, Koneski F. Brown Tumour in the Mandible and Skull Osteosclerosis Associated with Primary Hyperparathyroidism - A Case Report. *Open Access Maced J Med Sci.* 2018;6:406-9.
8. Goyal A, Boro H, Khadgawat R. Brown Tumor as an Index Presentation of Severe Vitamin D Deficiency in a Teenage Girl. *Cureus.* 2018;10:e2722.
9. Diani Kartini, Maria K. Siswiandari, Gunawan Wibisana, Erwin D. Yulian, Ahmad Kurnia, Sonar S. Panigoro, *et al.* Craniofacial Brown Tumor in Patients with Secondary Hyperparathyroidism to Chronic Renal Failure: Report of Two Cases in Cipto Mangunkusumo Hospital. *Case Rep Oncol Med.* 2018:1801652.

Funding: None; Conflict of Interest: None Stated.

How to cite this article: Chakravarti A, Shukla I, Mehra P, Shukla S. Parathyroid adenoma in a young female presenting with craniofacial brown tumor and acute pancreatitis – A case report. *Indian J Case Reports.* 2019;5(4):391-393.

Doi: 10.32677/IJCR.2019.v05.i04.033