

## Liver cirrhosis first time presented with delirium unveiled as accidental secondary hypothermia

Sayan Malakar<sup>1</sup>, Kailash Nath Sharma<sup>2</sup>, Bhagwan Das Negi<sup>1</sup>, Tarun Sharma<sup>3</sup>, Aradhna Sharma<sup>3</sup>

From <sup>1</sup>Junior Resident, <sup>2</sup>Professor, Department of Medicine, <sup>3</sup>Assistant professor, Department of Medicine and Pharmacology, Dr. Rajendra Prasad Government Medical College, Kangra, Himachal Pradesh, India.

**Correspondence to:** Dr. Tarun Sharma, Department of Medicine, Dr. Rajendra Prasad Government Medical College, Tanda Hospital Road, Kangra, Himachal Pradesh, India. E-mail: tarunpgi@gmail.com.

Received - 20 April 2019

Initial Review - 06 May 2019

Accepted - 30 July 2019

### ABSTRACT

Liver cirrhosis is a condition which is defined histopathologically but cannot be diagnosed clinically without any non-invasive tests. There are various etiologies of cirrhosis such as alcoholic liver disease, chronic viral hepatitis B, C, and non-alcoholic fatty liver diseases. Liver, not only function as an organ for detoxification, conjugation, and synthesis but also it regulates body heat. Cirrhosis patients thus are prone to body heat loss and hyperthermia. We present a case with undiagnosed liver cirrhosis patient, 1<sup>st</sup> time presenting with altered sensorium, revealed as accidental secondary hypothermia with ECG changes of hypothermia. The patient treated for hypothermia only after which she recovered.

**Keywords:** Cirrhosis, Hypothermia, Osborn wave.

Involuntary drop in core body temperature is a potentially harmful condition with significant morbidity and mortality [1,2]. Accidental hypothermia is defined by body core temperature less than  $<35^{\circ}\text{C}$  ( $95^{\circ}\text{F}$ ). Primary hypothermia occurs in otherwise healthy individuals where heat production mechanism is overcome by the stress or excessive cold; whereas, secondary hypothermia occurs in a patient with medical comorbidities.

Cirrhosis is one of such comorbidity since this counter-regulatory mechanism is hampered in such patients. The global prevalence of cirrhosis ranges from 4.5 to 9.5% in

autopsy studies in the general population. Patient with cirrhosis presenting with encephalopathy prompts physicians to search for hepatic encephalopathy and other causes. Apart from hepatic encephalopathy, hypoglycemia, meningitis, sepsis-associated encephalopathy, dyselectrolytemia, azotemia hypothermia may solely present with altered sensorium or may contribute to other causes for encephalopathy in cirrhosis patient.

Here, we are presenting this case as this patient was not a known case of cirrhosis presenting with altered sensorium which was attributed to hypothermia. After correcting hypothermia, the

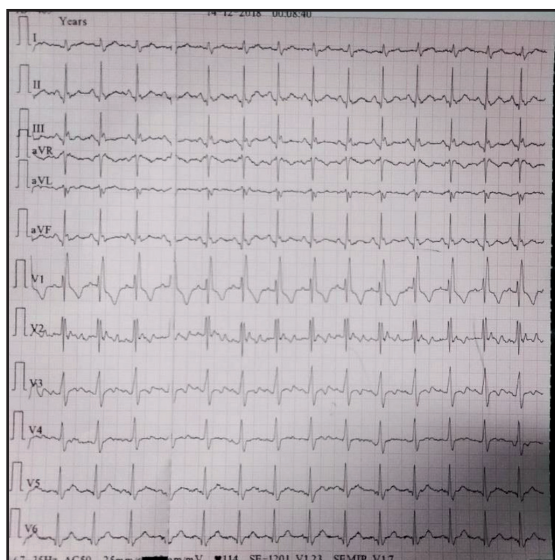


Figure 1: ECG showing Osborn waves.

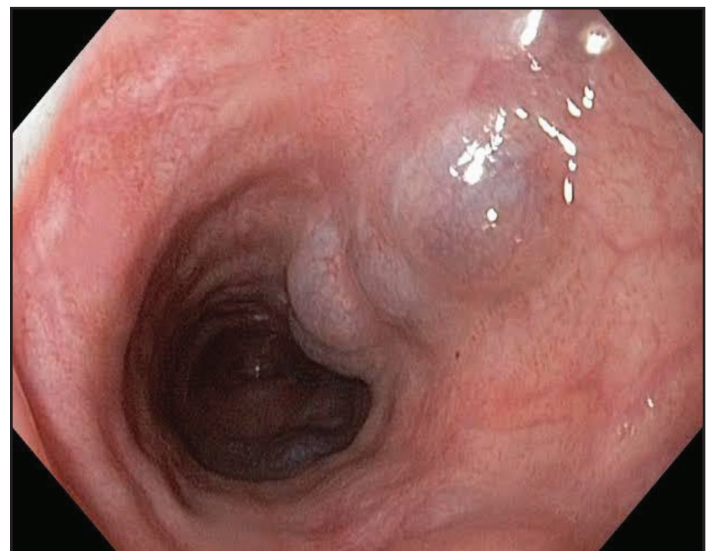


Figure 2: Upper GI endoscopy showing column I varices.

patient improved without additional drugs as most of the drugs don't even work in hypothermia. So in cirrhotic patients, routine checking of body core temperature is important which may reveal undiagnosed hypothermia leading to altered sensorium even in the absence of hepatic encephalopathy.

## CASE REPORT

A 42-year-old female homeless patient was brought to the emergency department by police. She was found in the footpath in an unconscious state at an environmental temperature of 20°C. On examination, her pulse was 102/min regular and blood pressure was 82/60mmHg. Random blood sugar was 132 mg/dL. Examination of cardiorespiratory and abdomen was normal. Neurological examination was normal except low Glasgow coma scale (GCS) score of 9/15.

Urgent non-contrast computed tomography (CT) head was normal. Serum sodium, potassium, calcium, magnesium were normal. Fundus examination was normal. Renal function tests were normal, liver enzymes showed alanine aminotransferase (ALT): 221 U/L and aspartate aminotransferase (AST): 65 U/L. Albumin was 3 g/dL. The international normalized ratio (INR) was 1.2, prothrombin time and bilirubin levels were normal. Sepsis was also ruled out. The anthropometric measurement did not reveal any suggestive clue for malnutrition. Blood culture, urine culture was sterile and procalcitonin was normal. Gastric lavage was also done keeping in view of poisoning. Arterial blood gas (ABG) analysis showed a pH of 7.36. Lactate, bicarbonate, PaO<sub>2</sub>, PaCO<sub>2</sub> and ammonia level was normal. Toxicology profile and cerebrospinal (CSF) examination were normal. Electrocardiography (ECG) showed Osborn wave and U wave (Fig. 1) and her core body temperature was documented to be 29.6 °C (rectal).

Based on the above-mentioned investigations, a diagnosis of mild hypothermia (Swiss staging system 2) was made. The patient was urgently managed with forced-air warming blanket and warm intravenous fluids. ECG normalized after rewarming. Central active warming was done by 42°C normal saline infusion as extra-corporeal membrane oxygenation (ECMO) was not available. The patient was also managed with passive external rewarming by insulating her in a warm environment with head covered. Rewarming rate was 1°C per hour. No drugs were administered. The temperature was monitored by the rectal and oral probe. The patient's hemodynamics were continuously monitored and no arrhythmia occurred. The patient gradually improved.

Fibroscan was done and liver stiffness was 21kPa. Upper gastrointestinal endoscopy shows small esophageal varices grade I (Fig. 2). The patient after regaining consciousness denied any illicit drug abuse except alcohol and smoking; though, her last alcohol consumption was 12 days ago. The patient gradually improved and discharged on day 7<sup>th</sup>. An electroencephalogram (EEG) was

also performed to rule out the hepatic encephalopathy, which came out to be normal. Psychometric hepatic encephalopathy score was done which did not reveal even minimal hepatic encephalopathy. The patient was evaluated for other possible causes of secondary hypothermia like Addison's disease, hypothyroidism, diabetes mellitus, hypoadrenalism; however, she had no other etiology of hypothermia.

## DISCUSSION

The liver has got a very important role to play in regulating core body temperature mainly through diet-induced thermogenesis. It is widely believed that energy expenditure plays an important role in regulating energy balance. Cold-induced, non-shivering thermogenesis and diet-induced thermogenesis are recognized as important components of energy expenditure. In genetically obese animals, one or both of these components are reduced. The energy cost of weight gain and maintenance is altered by manipulating the amount or composition of the diet. The close similarity between non-shivering, cold-induced thermogenesis and diet-induced thermogenesis was pointed out by Rothwell and Stock [3]. Since individual organs theoretically contribute to overall energy balance, the role of the liver in diet-induced thermogenesis was recently investigated by Berry and coworker [4].

Death in patients with secondary hypothermia is often caused by the underlying condition rather than by hypothermia. In all types of hypothermia, consciousness, breathing and circulation are initially intact but are impaired as the body cools [5]. As the patient was brought in casualty with promptness and patient's vitals didn't deteriorate, the patient was managed successfully without ECMO. Some patients with a core temperature of less than 28°C (82°F) engage in paradoxical undressing [6]. Atrial fibrillation is common when the core temperature is less than 32°C (90°F) and is not worrisome in the absence of other signs of cardiac instability. The risk of cardiac arrest increases as the core temperature drops below 32°C and increases substantially if the temperature falls below 28°C [7].

Hypothermia has been documented in the literature in patients with acute liver failure but in our patient, it was a case of compensated cirrhosis. Hypothermia is usually managed with continuous venovenous or arteriovenous rewarming. It can also be managed with hemodialysis or cardiopulmonary bypass. However, in resource-poor setting, it can be easily managed by passive external rewarming and warm saline infusion.

## CONCLUSION

Though the patient wasn't a known case of cirrhosis, a high index of suspicion for hypothermia should be kept in any known patient of cirrhosis with delirium. Core body temperature recording is very important and always should be checked.

## REFERENCES

1. Silfvast T, Pettilä V. Outcome from severe accidental hypothermia in Southern Finland – a 10-year review. *Resuscitation*. 2003;59:285-90.
2. Walpoth BH, Walpoth-Aslan BN, Mattle HP, Radanov BP, Schroth G, Schaeffler L, *et al.* Outcome of survivors of accidental deep hypothermia and circulatory arrest treated with extracorporeal blood warming. *N Engl J Med*. 1997;337:1500-5.
3. J. Hirrnns-Hagen. Brown Adipose Tissue Thermogenesis in Obese Animals. *Nutrition Reviews* 4. N.J. Rothwell and M.J. Stock: A Role for Brown Adipose Tissue in Diet-Induced Thermogenesis. *Nature* 1979;281:31-35.
4. Durrer B, Brugger H, Syme D. The medical on-site treatment of hypothermia: ICAR-MEDCOM recommendation. *High Alt Med Biol*. 2003;4:99-103.
5. Danzl DF, Pozos RS. Accidental hypothermia. *N Engl J Med*. 1994;331:1756-60.
6. Brändström H, Eriksson A, Giesbrecht G, Ångquist KA, Haney M. Fatal hypothermia: analysis from a sub-arctic region. *Int J Circumpolar Health*. 2012;71:1-7.
7. Danzl DF, Pozos RS, Auerbach PS, Glazer S, Goetz W, Johnson E *et al.* Multicenter hypothermia survey. *Ann Emerg Med*. 1987;16:1042-55

*Funding: None; Conflict of Interest: None Stated.*

**How to cite this article:** Malakar S, Sharma KN, Negi BD, Sharma T, Sharma A. Liver Cirrhosis First Time Presented with Delirium Unveiled as Accidental Secondary Hypothermia. *Indian J Case Reports*. 2019;5(4):354-356.

Doi: 10.32677/IJCR.2019.v05.i04.020