

## A case of typhoidal sacroiliitis

Garyll Ryan Tariang Blah<sup>1</sup>, Pulin Kumar Gupta<sup>3</sup>, Ramesh C Meena<sup>2</sup>, Priyanka K Gedam<sup>1</sup>, Bhumi Agarwal<sup>1</sup>

From <sup>1</sup>Postgraduate Resident, <sup>2</sup>Ex Senior Resident, <sup>3</sup>Professor, Department of Medicine, PGIMER & Dr. Ram Manohar Lohia Hospital, New Delhi, India.

**Correspondence to:** Dr. Garyll Ryan Tariang Blah, Department of Medicine, OPD Block, PGIMER & Dr. Ram Manohar Lohia hospital, New Delhi - 110001, India. E-mail: drgaryll913@gmail.com

Received - 20 May 2019

Initial Review - 13 June 2019

Accepted - 10 July 2019

### ABSTRACT

Sacroiliitis caused by *Salmonella typhi* is an unusual occurrence. *Mycobacterium tuberculosis* is the usual culprit in our country. We report this case of a 17-year-old young boy who presented with high-grade fever and hip pain. Imaging revealed sacroiliitis and culture grew *Salmonella typhi*. The patient was treated with parenteral antibiotics and later continued on oral antibiotics.

**Keywords:** *Antibiotics, Sacroiliitis, Salmonella typhi.*

**S**almonella infections cause acute gastroenteritis, lymphopenia, enteric fever, and localized infections. Bone-related infections are seen in <1% of cases<sup>1</sup>. The most common organisms apart from *Mycobacterium tuberculosis* implicated in sacroiliitis are *Staphylococcus aureus* and *Streptococci* and in intravenous drug users, the organism being *Pseudomonas aeruginosa*. Sacroiliitis with *Salmonella typhi* being the etiological agent is uncommon and only a few cases have been reported. Here, we present the case of a 17-year-old boy who presented with high-grade fever and hip pain.

### CASE REPORT

A 17-year-old boy presented with complaints of high-grade fever with chills for 10 days. He also had episodes of diarrhea, abdominal pain and the left hip pain since last one week. There was no history of recent trauma or injury or any recent intramuscular injection at that site.

At the time of admission, the patient had a temperature of 102°F. His pulse rate was 84/minute and blood pressure was 110/60 mmHg. General physical examination was normal. Per abdominal examination revealed mild generalized tenderness but no obvious clinical organomegaly or shifting dullness. External genitalia were normal. Rest of the systemic examination was unremarkable. Musculoskeletal examination revealed tenderness in the left hip joint elicited by direct pressure and the range of motion was terminally impaired in the left hip joint. Modified Schober's test revealed no restriction in lumbar Range of Motion (ROM). There was no obvious scar or bruise; however, tenderness was localized to the left sacroiliac joint with no bulge or swelling. There was no limb length discrepancy or distal neurovascular deficit. The straight leg raising test was also within normal limits.

Laboratory investigations an elevated Erythrocyte Sedimentation Rate (ESR) of 62mm/hour and rest normal blood

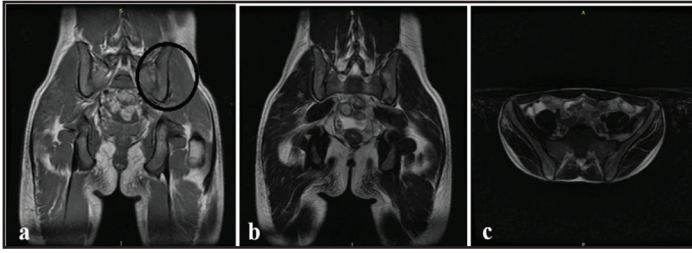
counts. His kidney function tests (urea-20mg/dl creatinine-0.9mg/dl uric acid-2.4mg/dl) and liver function tests (total bilirubin- 1.3mg/dl, alanine transaminase 40U/l aspartate transaminase 45U/l) were normal except for an elevated alkaline phosphatase. (524 U/L).

All other investigations as a part of fever workup including urine routine and culture, blood culture, chest X-ray, ultrasonography of the abdomen, tuberculin skin test, blood smears for malaria, NS1 antigen and dengue serology were normal. Tests for *Leptospira* and rickettsia were also negative. 2D ECHO to rule out infective endocarditis was also unremarkable. Widal test initial titers of TH were positive in 1:160 dilution and subsequent the titers rose to >1:640. IgM ELISA against *S. typhi* was positive. Blood cultures (done after 3 days of oral antibiotic therapy received prior to admission) came out to be sterile; however, bone marrow cultures (done from the right posterior iliac crest, on the 5<sup>th</sup> day of fever) grew *Salmonella typhi* sensitive to aminoglycosides, azithromycin, and ceftriaxone.

The patient was treated with intravenous ceftriaxone 2gm twice daily and intravenous azithromycin 1gm daily. The patient

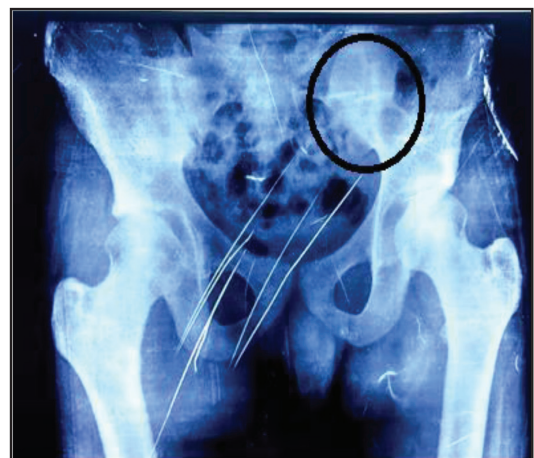

Figure 1: Left grade II sacroiliitis.

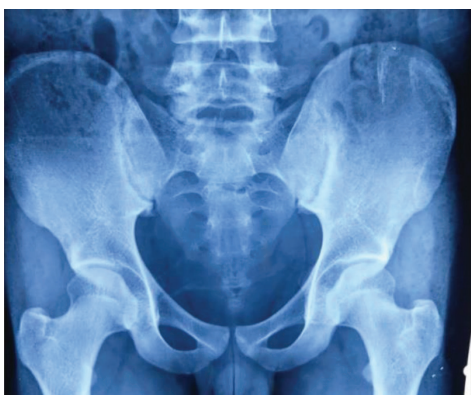

**Figure 2:** (a) Evidence of ill-defined T1 hypointensity noted in the periarticular bone in the lower 2/3<sup>rd</sup> of left sacroiliac joint (b) which is hyperintense on T2WI and (c) not suppressed on STIR images.

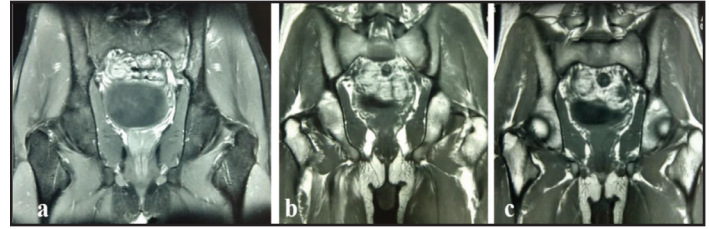
started responding clinically to the treatment by the 3<sup>rd</sup> day and symptomatically improved. He became afebrile on the 5<sup>th</sup> day, however, the patient continued to complain regarding the left hip pain. X-ray pelvis was suggestive of left-sided grade II sacroiliitis while the right sacroiliac joint was normal (Fig. 1). Contrast-enhanced magnetic resonance imaging (CE-MRI) of the pelvis revealed altered osseous marrow signals seen in the left sacrum and minimally into the iliac bone which revealed hyperintense signal on T2/T2 fat saturated and hypointense signal on T1 weighted images with irregular cortical margins and increased fluid in the left sacroiliac joint along with a loculated soft tissue collection in the left iliacus muscle. (Fig 2 a-c). Post-contrast study shows enhancement in the collection and effaced osseous elements. Ultrasound-guided aspiration of the collection was unsuccessful.

Sickling test and hemoglobin electrophoresis were also negative. Contrast-enhanced computed tomography (CECT) abdomen showed thickening of the terminal ileum with abdominal lymphadenopathy. No ascites was seen. Tests for hepatitis B (HBsAg), hepatitis C (anti-HCV), and human immunodeficiency virus (anti-HIV) were negative. Brucella serology was negative. HLA-B27, anti-nuclear antibody (ANA) and IGRAs tests were also negative.

Hence, the patient was diagnosed as a case of enteric fever with abdominal lymphadenopathy with iliacus muscle collection (possibly abscess) with probable typhoidal sacroiliitis. The patient was continued on intravenous antibiotics for 2 weeks and later switched over to oral antibiotics for the next two months. One month after the presentation, the patient recovered clinically and was pain-free with no limitation of movements or tenderness. A repeat X-ray Pelvis after completion of treatment was normal



**Figure 3:** Repeat X-ray Pelvis after completion of treatment.



**Figure 4:** (a-c) Repeat CE MRI pelvis showing hip joints and sacroiliac joints bilaterally appearing normal.

(Fig. 3). A repeat contrast-enhanced MRI examination after 12 weeks found no significant erosion or fluid except subtle hypointensities in T1 as well as T2 images; probably with signs of residual sclerosis (Fig 4 a-c). A repeat CECT abdomen did not reveal any abnormality and the ileal thickening and lymphadenopathy resolved within 3 months.

## DISCUSSION

Salmonella serotypes often produce typical clinical syndromes, including gastroenteritis, enteric fever, bacteremia and vascular infection apart from localized infections. Joint involvement is seen in less than 1% of the cases and usually in patients having risk factors such as connective tissue disease, sickle cell disease, HLA-B27 positive spondylitis and presence of a prosthetic joint. The joints commonly involved include knee, ankle, wrist and sacroiliac joint (most often unilateral) [1].

Inflammatory sacroiliitis (like in SpA, PsA or IBD associated) is usually bilateral although the unilateral presentation is not uncommon. However, unilateral sacroiliitis is mostly attributed to infectious causes including neoplastic destruction process, reactive arthritis, tuberculosis, pyogenic septic arthritis and especially brucellosis in a country like India where a large population reside in villages and are exposed to cattle and drink raw milk [2].

Salmonella as an etiologic factor for septic arthritis is not commonly seen as compared to other gram-negative bacteria like *Shigella flexneri*, *Campylobacter* species and *Yersinia enterocolitica*. Predisposed individuals with diabetes mellitus, malignancy, hemoglobinopathy, HIV infection and other immune suppressive states may develop salmonella arthritis. No such predisposition was seen in our patient, however, a delayed diagnosis could have been a factor in our case. Direct salmonella infections of bone typically involve the long bones, the chondrosternal junctions, the knee, the shoulder, the hip, the sacroiliac joints and the spine, although any skeletal site can become infected [3].

Salmonella arthritis can be due to infection of the joint per se or it can be reactive arthritis. Reactive arthritis may follow a gastrointestinal infection with *Salmonella* species and appears 1 to 4 weeks after the same. Tests for HLA-B27 antigen are usually positive in 50% of population-based cohorts and 70% of hospital-based cohorts.

Extra-articular manifestations may include psoriasis, balanitis, iritis or inflammatory bowel disease. Acute asymmetric inflammatory oligoarthritis, enthesitis and buttock pain is generally

observed in reactive arthritis. However, in our case monoarticular involvement of the left hip joint was observed and HLA-B27 was negative. Apart from that no enthesitis or uveitis was present and all of these observations together favor direct septic arthritis rather than reactive arthritis. The most important factor to suggest this is not reactive arthritis would be the time gap between the infection and the episode. Notably, the possible infective appearance which was enhanced on contrast which is never a feature of reactive arthritis since it is per se a sterile inflammation. Approximately, 60% of persons affected with salmonella reactive arthritis can have episodes of joint pain when interviewed 4–5 months after treatment [4].

MRI features of the bone and soft tissue lesions in unilateral sacroiliitis have been seen to aid in the differentiation between infectious sacroiliitis and reactive arthritis. Amongst various findings, periarticular muscle edema was the found to be the single most important predictor of infectious sacroiliitis, [5] which was probably seen as iliacus collection in our case. The diagnosis of salmonellosis depends on cultures being drawn up before antibiotic therapy is started. Blood cultures are usually positive. Most cases are hematogenous in origin as evident by the high incidence of positive cultures in both Salmonella associated osteomyelitis and septic arthritis [6]. If blood cultures are negative then bone marrow cultures can be positive in spite of up to 5 days of prior antibiotic usage [7].

Among all documented case reports of typhoidal sacroiliitis, blood culture grew salmonella typhi and all the cases responded to antimicrobial therapy [8-10]. In our case, though blood cultures were negative, the bone marrow culture grew Salmonella typhi. The seeding of bacteria probably led to the development of sacroiliitis, however, we could not prove it as the sacroiliac joint aspiration was dry. The duration of treatment of patients with Salmonella sacroiliitis varies. Most of the patients received a protocol involving intravenous antibiotics followed by oral treatment for a total of 6-8 weeks. In view of widespread resistance to fluoroquinolones [11], recommended antibiotics are now cephalosporins.

In our case, the presence of sclerotic changes could also indicate a preexistent sacroiliitis, which was an incidental during the current illness. Subclinical disease in spondyloarthritis is a well-known entity, with a median disease duration before a diagnosis of 5-10 years. The authors acknowledge this fact and cannot rule out this possibility.

## CONCLUSION

Reactive arthritis of the sacroiliac joint following Salmonella infection is a known clinical entity in patients who are positive for HLA-B27 antigen. However, pyogenic sacroiliitis due to Salmonella is unusual. This case is being reported to highlight the rare presentation of salmonella sacroiliitis. Correct diagnosis and longer than normal duration of treatment saved the affected sacroiliac joint and prevented any future disability.

## REFERENCES

1. Pegues DA, Miller SI. Salmonella species. In: Mandel GL, Douglas RG, Bennett JE, editors. Principles and Practice of Infectious Diseases. 8<sup>th</sup> ed. Edinburgh: Churchill Livingstone. 2014. pp 2559-68.
2. Vyskocil JJ, McIlroy MA, Brennan TA, Wilson FM. Pyogenic infection of the sacroiliac joint. Case reports and review of the literature. *Medicine (Baltimore)*. 1991;70:188-97.
3. Ulug M, Celen MK, Geyik MF, Hosoglu S, Ayaz C. Sacroiliitis caused by Salmonella typhi. *J Infect Dev Ctries*. 2009;3:564-8
4. Gaston JSH. Reactive Arthritis In: Firestein GS, Budd RC, Gabriel SE, McInnes IB, O'Dell JR, editors. Kelley and Firestein's Textbook of Rheumatology, 10<sup>th</sup> ed. Philadelphia: Elsevier; 2017. pp 2087-2094
5. Kang Y, Hong SH, Kim JY *et al.* Unilateral Sacroiliitis: Differential Diagnosis Between Infectious Sacroiliitis and Spondyloarthritis Based on MRI Findings. *AJR Am J Roentgenol*. 2015;205:1048-55.
6. Kim AY, Goldberg MB, Rubin RH. Salmonella Infections. In: Gorbach SL, Barlett JG, Blacklow NR editors. *Infectious Diseases*. 3<sup>rd</sup> ed. Philadelphia, PA: Lippincott Williams & Wilkins; 2004. pp 618-632
7. Pegues DA, Miller SI. Salmonellosis In: Kasper DL, Hauser SL, Jameson JL, Fauci AS, Longo DL, Loscalzo J editors. *Harrison's Principles of Internal Medicine*. 19<sup>th</sup> ed. McGraw Hill 2015. pp 1049-1054
8. Menon KP, Gupta A. Atypical salmonellosis: two cases of sacroiliitis. *Indian J Pathol-Microbiol*. 1993;36:84-6.
9. Alsoub H. Sacroiliitis due to Salmonella typhi: a report of two cases. *Ann Saudi Med*. 1997;17:331-3.
10. Feldman LS. Salmonella septic sacroiliitis: case report and review. *Pediatr Infect Dis J*. 2006;25:187-9.
11. Threlfall EJ, Ward LR. Decreased susceptibility to ciprofloxacin in salmonella enterica serotype Typhi, United Kingdom. *Emerg Infect Dis*. 2001;7:448-50.

*Funding: None; Conflict of Interest: None Stated.*

**How to cite this article:** Blah GRT, Gupta PK, Meena RC, Gedam PK, Agarwal B. A Case of Typhoidal Sacroiliitis. *Indian J Case Reports*. 2019;5(4):338-340.

Doi: 10.32677/IJCR.2019.v05.i04.014