

Salvage of a fifteen days old thrombosed dialysis fistula: A case report

Agamy Saxena¹, Padma Mishra²

From ¹Consultant Radiologist, ²Medical Director, Department of Interventional Radiology, Noble Hospital, Misrod, Bhopal, Madhya Pradesh, India

Correspondence to: Dr. Agamy Saxena, Department of Interventional Radiology, C-10, 3rd Floor, Gulmohar Block, Green Meadows, Arera Hills, Jail Road, Bhopal - 462011, Madhya Pradesh, India. E-mail: agamy.saxena@gmail.com

Received - 30 April 2019

Initial Review - 17 May 2019

Accepted - 27 June 2019

ABSTRACT

Hemodialysis fistulae are important conduits for successful long-term dialysis in chronic kidney disease patients. More often than not, these fistulae are prone to get thrombosed or stenosed, especially at the juxta-anastomotic sites. The venous outflow is a commoner site, as rapid arterial inflow leads to a higher incidence of neointimal hyperplasia. Early signs of stenosis or thrombosis are easy to detect viz. decrease/loss of thrill, slow hemodialysis filtration rate resulting in unusually longer time spans for a dialysis session or inadequate dialysis overall. Early detection can help planning an early radiological intervention in the form of thromboaspiration, thrombolysis, balloon angioplasty or stenting. However, the older a thrombus, the harder it is to get rid of. We present here a case of fifteen days old thrombosis of a radio-cephalic fistula, which underwent thromboaspiration and balloon angioplasty, with a satisfactory result. Dialysis fistula is the “life-line” of chronic kidney disease patients; and in line with the “fistula first” initiative, our case exemplifies its motto.

Keywords: *Failing fistula, Fistula angioplasty, Fistula salvage, Hemodialysis fistula, Thrombosed fistula.*

Hemodialysis access is the “lifeline” of End-Stage Renal Disease (ESRD) patients, whether they are transplant candidates or not. The natural history of a vascular access graft or fistula is the progressive development of neointimal hyperplastic stenoses that reduces blood flow and compromises the performance of the vascular access. Primary patency of hemodialysis shunts is low: approximately 65% of Brescia-Cimino shunts and 50% of polytetrafluoroethylene (PTFE)-covered shunts exhibit primary patency after 1 year, and the numbers sink after 2 and 4 years to 60% and 45% for Brescia-Cimino shunts and to 43% and 10% for PTFE-covered shunts [1]. If left untreated, these lesions will eventually lead to thrombosis of the vascular access. Early detection and treatment of hemodynamically significant stenosis is a primary tenet of a vascular access management program.

Angioplasty remains the most important technique for treating neointimal hyperplastic stenoses associated with hemodialysis grafts and fistulas. Older thrombi (usually more than seven days old) are difficult to remove, and most such patients are subjected to new fistula formation, sacrificing the existing one. Our case represents a successful outcome, and good flow establishment in a relatively old thrombus, and delineates the importance of “salvaging” a fistula, rather than sacrificing one.

CASE REPORT

A 62-year-old male had been on regular hemodialysis (twice a week) at our hospital since last three years. He was undergoing dialysis for the last two and a half years through a left forearm radio-cephalic fistula. On grounds of a sudden absence of thrill,

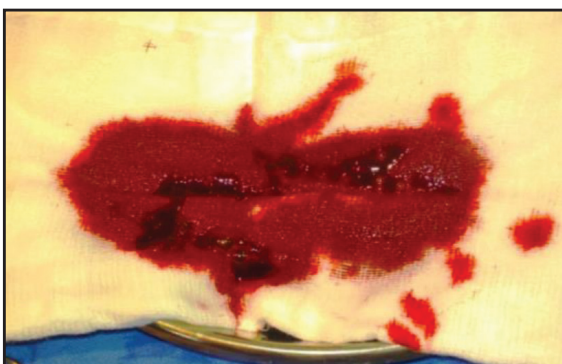

Figure 1: Photograph showing multiple clots retrieved from thrombosed fistula.

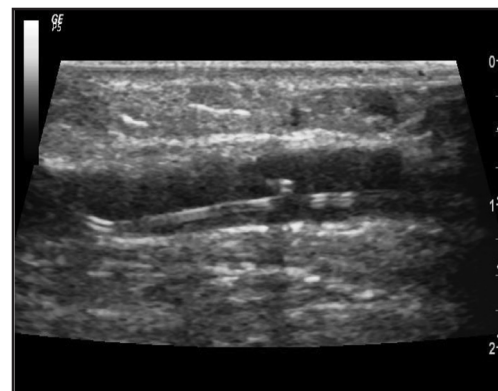


Figure 2: Ultrasound image of guidewire in the radial artery.

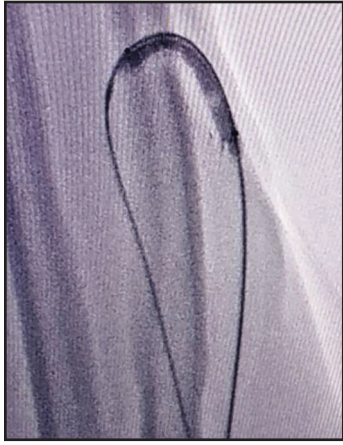


Figure 3: Fluoroscopy image of dilated high-pressure balloon across the fistula.

no pulsatility and poor flow through draining vein about two days back, the dialysis technician and concerned nephrologist diagnosed him with possible thrombosis of fistula.

On examination, the patient was vitally stable, with a blood pressure of 140/100mm Hg, heart rate of 82/min and was afebrile. He was then referred to the department of interventional radiology for a colour Doppler examination. The colour Doppler revealed a partially occluding short-segment (approx. 2.2cm long) hyperechoic thrombus causing flow limitation, and poor waveforms in draining vein. The clot was in the juxta-anastomotic site, beginning approximately 1 cm from fistula site. A suggestion of urgent fistula salvage procedure (thrombo-aspiration and angioplasty) was given to the patient. The patient denied this procedure on grounds of personal and financial issues. He was then dialysed through a temporary jugular catheter. Twelve days later, he developed chills and high-grade fever with the temporary catheter in-situ. The patient was counseled again for the fistula salvage procedure, and this time he consented for it.

Fifteen days after the initial thrombotic event, he was taken up for fistula salvage procedure. Coagulation parameters and renal function tests (especially serum potassium levels) were tested before the procedure. Just before the procedure, ultrasound (USG)-guided brachial plexus nerve block was administered to prevent pain during fistula dilatation. USG-guided access was obtained in the draining vein, at the level of the elbow with a 6F radial sheath. After initial administration of 3000 units of unfractionated heparin, a continuous infusion of heparin was started at the rate of 1000units/hour through the side arm of the sheath, and was continued throughout the procedure.

Using a 0.035" angled-tip glidewire (Terumo) and 6F JR shaped guide catheter, manual thrombo-aspiration was performed with a 50cc luer lock syringe and few clots were retrieved (Fig. 1). However, there was a significant residual stenosis in the affected part of the draining vein. Pharmacological thrombolysis was not attempted as the clot was too old for it to be successful. The glidewire was further negotiated across the fistula, and its tip placed in the mid-radial artery (Fig. 2). The glidewire was then exchanged with a 0.035" angled tip, Amplatzultra stiff wire (Cook). Over this wire, serial dilatations of the affected part of

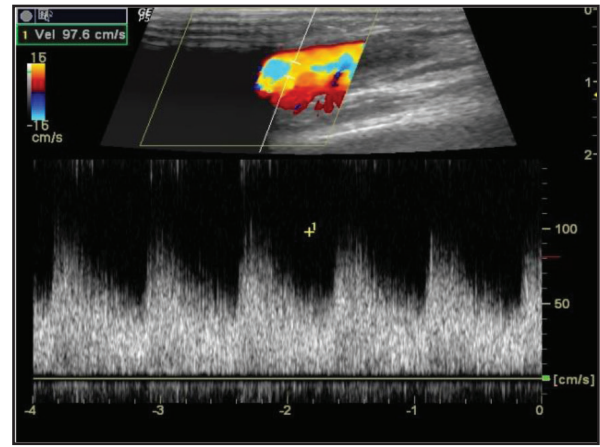


Figure 4: Post-angioplasty Doppler image showing adequate low resistance flow in draining vein.

the vein were performed using 5x40mm balloon (Rival, BD) and 6x40mm high-pressure balloon (Conquest, BD) (Fig. 3).

The whole procedure was done in USG and plain fluoroscopy guidance, without any contrast injection. The stenotic lesion was identified on colour Doppler and was marked using a metallic needle holder, to be visible on fluoroscopy. This guided us to choose the correct site of balloon inflation. A satisfactory post-angioplasty result was proved, when Peak Systolic Velocity (PSV) in the draining vein was comparable to the PSV across fistula (Fig. 4). In total, 9000 units of heparin were injected during the whole procedure, and the sheath was removed once Activated Clotting Time (ACT) was less than 200 seconds.

The post-procedure hospital stay was uneventful. The fistula thrill was now well palpable, and the patient achieved satisfactory dialysis flow rates on the next day. He was discharged on short term anti-inflammatory and analgesic drugs and long-term dual antiplatelet therapy.

DISCUSSION

The criteria that define failing vascular access and the indications for the percutaneous or surgical repair are described in the National Kidney Foundation (NKF) Clinical Practice Guidelines for Vascular Access [2]. Primary indications for percutaneous intervention of either polytetrafluoroethylene (PTFE) grafts or arteriovenous fistulas (AVFs) include documentation of a clinical or hemodynamic abnormality and a stenosis causing over 50% reduction in luminal diameter. Intervention is not indicated unless the clinical and angiographic findings are both abnormal and correlative.

Clinical examination of the shunt and especially palpation of the venous outflow tract gives an impression of the type of occlusion and its location and is an inevitable part of the clinical checkup prior to an intervention. When in doubt, sonography and duplex sonography may help determine the extent of thrombosis and its location.

Several clinical studies have reported that periodic assessment of intra-access blood flow may be the most reliable method for early detection of developing stenosis [3-5]. Intra-access blood flow is measured during hemodialysis, and if intra-access blood

flow is less than 600 mL/min, a fistulogram is recommended to evaluate the entire vascular access circuit [2]. AVFs that have failed to mature within 3 months of creation should undergo fistulography to determine whether angioplasty or surgical revision would be beneficial. Shunt occlusions in Brescia-Cimino fistulas, especially in the very early phase, may be due to only a very short plug-like thrombus selectively obstructing the arteriovenous anastomosis or a segment of the venous outflow.

In those cases, the draining shunt vein is soft and compressible at palpation. If digital manipulation to remove the thrombus fails, this type of obstruction is an ideal candidate for percutaneous transluminal angioplasty (PTA), since the small thrombus can be macerated by balloon inflation alone, and flow can be restored immediately. Treatment, however, should be started soon to avoid propagation of thrombosis. A therapeutic window considered good is an interval of 24 to 48 hours after thrombosis, although there is a divergence in the literature, with some authors showing good results even after this period [6,7].

The extent and type of angiography supplies are dependent on physician preference and the variety of procedures performed. A selection of multipurpose angiographic catheters, guidewires, and vascular sheaths is necessary for basic interventional procedures. High-pressure angioplasty balloons with rated burst pressures of greater than 15 atm are often required for effective treatment of neointimal hyperplastic stenoses. For very fibrotic and resistant stenoses, a peripheral cutting balloon may be useful. A stent can oppose elastic recoil, optimize endoluminal dimensions, and improve blood flow through the vascular access. However, the majority of clinical studies have reported that stents do not provide superior long-term patency and that the results are similar to those obtained with angioplasty alone [8,9].

According to the national guidelines, the expected 6-month primary patency rate is 40% to 50% after angioplasty of stenosis associated with a failing hemodialysis graft or fistula [2]. Duque *et al* have reported a case of multiple juxta-anastomotic stenosis causing primary fistula failure, treated with angioplasty [10]. The reported 2-month primary patency rates range from 23% to 51% [11]. Inevitably, the treated stenosis will recur or a new stenosis will develop at a second site along the vascular access circuit. Scenarios of recurrent graft thrombosis have also been reported in patients having hyperhomocysteinemia [12]. Long-segment thrombosis of Brescia-Cimino fistulas present with enlarged and incompressible veins that appear rather hard during palpation. PTA alone is mostly insufficient in these cases.

Published literature describes a number of approaches to treating clotted native fistulas including thrombolysis and spray-lysis, mechanical thrombectomy, balloon angioplasty, aspiration thrombectomy, hydrodynamic thrombectomy, mechanical clot dissolution and stent placement. Clot removal may be also performed using a simple 7F to 9F end-hole aspiration catheter.

The technique used is similar to arterial thrombosuction. If a residual flow is present, arterial inflow should be interrupted by digital compression to facilitate aspiration of a clot. It is a simple and cost-effective technique to remove clot effectively. The only absolute contraindication to percutaneous intervention is infected vascular access. Relative contraindications include allergy to a contrast agent, intervention on a newly placed graft or fistula; and long-segment venous stenosis (more than 7cm) and occlusions.

CONCLUSION

Fistula salvage techniques have evolved tremendously over the last few decades. The described case signifies that in suitable patients, even late presentation of fistula thrombosis can be dealt with endovascular means. However, the importance of early clot removal and angioplasty cannot be overemphasized.

REFERENCES

1. Zibari GB, Rohr MS, Landreneau MD, *et al*. Complications from permanent hemodialysis vascular access. *Surgery*. 1988;104:681-6
2. National Kidney Foundation, Vascular Access 2006 Work Group: Clinical practice guidelines for vascular access. *Am J Kidney Dis*. 2006;48:S176-247
3. McCarley P, Wingard RL, Shyr Y, *et al*. Vascular access blood flow monitoring reduces access morbidity and cost. *Kidney Int*. 2001;60:1164-72
4. Sands JJ. Vascular access monitoring improves outcomes. *Blood Purif*. 2005;23:45-9
5. Schwab SJ, Oliver MJ, Suhocki P, McCann R. Hemodialysis arteriovenous access: detection of stenosis and response to treatment by vascular access blood flow. *Kidney Int*. 2001;59:358-62
6. El-Damanawi R, Kershaw S, Campbell G, Hiemstra TF. Successful restoration of arteriovenous dialysis access patency after late intervention. *Clin Kidney J*. 2015;8:82-6.
7. Hsieh MY, Lin L, Chen TY, Chen DM, Lee MH, Shen YF, *et al*. Timely thrombectomy can improve patency of hemodialysis arteriovenous fistulas. *J Vasc Surg*. 2018;67:1217-26.
8. Gray FRJ. Angioplasty and stents for peripheral and central venous lesions. *TechVasc Interv Radiol*. 1999;2:189-98
9. Lorenz J. Use of stents for maintenance of hemodialysis access. *Semin Intervent Radiol*. 2004;21:135-40
10. Duque JC, Tabbara M, Martinez L, Cardona J, Vazquez-Padron RI, Salman LH. Dialysis Arteriovenous Fistula Failure and Angioplasty: Intimal Hyperplasia and Other Causes of Access Failure. *Am J Kidney Dis*. 2017;69:147-51. doi: 10.1053/j.ajkd.2016.08.025. Epub 2016 Oct 27. PubMed PMID: 28084215; PubMed Central PMCID: PMC5240806.
11. Vesely TM. Percutaneous transluminal angioplasty in the treatment of failing hemodialysis grafts and fistulae. *Semin Dial*. 1998;11:351-359
12. Allon M. A Patient with recurrent arteriovenous graft thrombosis. *CJASN*. 2015;10(12):2255-65, doi: 10.2215/CJN.00190115

Funding: None; Conflict of Interest: None Stated.

How to cite this article: Saxena A, Mishra P. Salvage of a fifteen days old thrombosed dialysis fistula: A case report. *Indian J Case Reports*. 2019;5(4):323-325.

Doi: 10.32677/IJCR.2019.v05.i04.008