

A case of brain abscess caused by actinomyces mimicking glioma: A rare presentation

Manika Khare¹, Zai Wade¹, Himanshu Gupta², Lalit Bhardwaj², Nauratmal Kumawat³, Vipin Ola³

From Consultant, ¹Department of Pathology, ²Department of Neurosurgery, ³Department of Radiology, Apex hospitals, Industrial Area, Malviya Nagar, Jaipur, Rajasthan, India.

Correspondence to: Dr Manika Khare, Department of Pathology, 3/293 Malviya Nagar, Jaipur - 302017, Rajasthan, India. E-mail: drmanika09@gmail.com

Received - 18 April 2019

Initial Review - 7 May 2019

Accepted - 23 May 2019

ABSTRACT

Actinomycosis is a rare, chronic and slowly progressive granulomatous disease, caused by filamentous Gram-positive anaerobic bacteria from Actinomycetaceae family (genus Actinomyces) belonging to endogenous flora of mucous membranes. Actinomycosis infection to the Central Nervous System is generally secondary to hematogenous dissemination from the primary infection in the lung, abdomen, pelvis or by continuity in a cervical, oral or facial infection, since it is closely related to mycobacteria in the mouth and gastrointestinal tract. Actinomyces abscess of the brain can at times be confused with space-occupying lesions (SOL), tuberculosis as was seen in this case. A biopsy is essential for the diagnosis as if treated early these patients have a good prognosis. We present a case of 28 years male presented with frontal SOL which came out as actinomycosis on biopsy.

Keywords: Abscess, Actinomyces, Brain, Space occupying lesion.

Actinomycosis is a rare, chronic and slowly progressive granulomatous disease, caused by filamentous Gram-positive anaerobic bacteria from Actinomycetaceae family (genus Actinomyces) belonging to endogenous flora of mucous membranes [1]. Actinomycosis is a relatively rare infection that occurs 1 in 300,000 persons per year. Men are affected three times more than women [2]. The clinical picture and radiologic findings are unspecific and are similar to any pyogenic abscess [3].

Actinomycosis infection to the Central Nervous System is generally secondary to hematogenous dissemination from the primary infection in the lung, abdomen, pelvis or by continuity in a cervical, oral or facial infection since it is closely related to mycobacteria in the mouth and gastrointestinal tract [4,5]. Actinomyces abscess of the brain can be confused with space-occupying lesions (SOL), tuberculosis as was seen in this case. A biopsy is essential for the diagnosis as if treated early these patients have a good prognosis. We present the case of a 28-years-old male presented with frontal SOL which came out as actinomycosis on biopsy.

CASE REPORT

A 28-years-old male came with altered sensorium in neurosurgery outpatient department. The patient had a history of continuous headache for 3 months and had seizures last night. On examination, the patient was conscious but not oriented to time, place and person. Vitals were stable.

On investigation, the patient had neutrophilic leucocytosis (Total Leukocyte Count 18,000/cumm, neutrophils 90%, lymphocytes 07%, monocytes 03%) otherwise unremarkable blood investigations. Computed tomography (CT) of the patient was done which showed

anirregular isointense mass in left high frontal lobe involving both grey and white matter, with marked perilesional edema (Fig. 1). Based on CT findings, the possibility of glioma was given. The patient had a past history of lung lesions for which he was getting antitubercular treatment but was not responded for the same.

The patient was operated, in which craniotomy was done and per operatively an abscess was identified at the site of the lesion which was suctioned and drained and sent for histopathological examination. On histopathological examination, the brain tissue showed intense acute and chronic inflammatory infiltrate with features of gliosis (Fig. 2). No granulomatous lesion was seen. Periodic acid-fast (PAS) stain was done on the slides which showed filamentous colonies of actinomyces (Fig. 3). Hence, the final diagnosis of actinomycosis added was given. The patient was followed up on a monthly basis

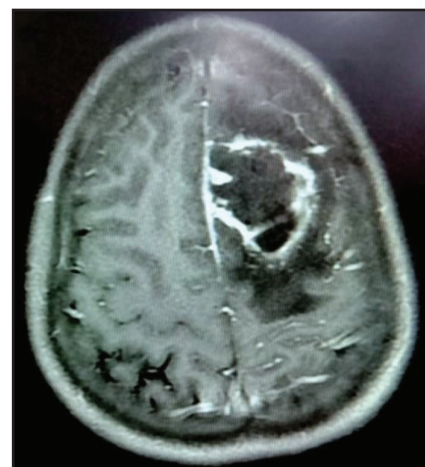


Figure 1: CT image showing an irregular isointense mass in left high frontal lobe involving both grey and white matter.

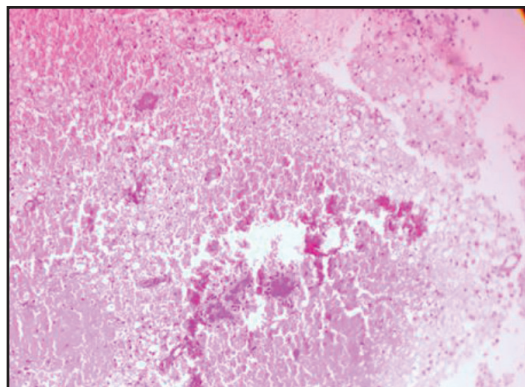


Figure 2: H&E stained smears showing intense acute and chronic inflammatory infiltrate with areas of necrosis.

for 6 months and the patient is doing well after treatment. His lung lesions are also reduced now.

DISCUSSION

Actinomycosis is an infrequent and slow-progression infection which originates partially from the normal buccal flora. A crucial step in the development of the infection is the loss of the mucosal barrier [6]. Sites of infection are in the head and neck (50%), abdomen (20%), thorax (15%), pelvis, heart, and brain (15%). Central nervous system infection is rare and it occurs in less than 5% of cases. In cerebral actinomycosis, common clinical features are headache and focal neurological signs [7], and symptoms may be present for a long time and fever may not occur.

In the brain, the disease usually occurs as brain abscess, meningitis/meningoencephalitis, actinomycoma, subdural empyema or epidural abscess [8]. Actinomyces occipital or parietal brain abscesses have been attributed to direct cranial extension from the oral cavity, however, little is known about the virulence factors that enable Actinomyces to invade tissues in this way [9]. Patients who present with actinomycotic brain lesions often have concomitant lung disease. In some instances, this presentation has been misdiagnosed as lung cancer with brain metastasis. In our case also, the patient was having the lung lesion which might be due to actinomyces [10].

Brain imaging is not helpful into differentiate among other infectious and noninfectious diseases; CT scan or magnetic resonance imaging (MRI) may report an irregular nodular ring-shaped thick wall lesion [11]. CT scan identifies cerebral and cerebellum abscesses which are generally solitary but may be multiple (in combination with a granuloma) and present homogeneous enhancement with a thick wall and perilesional edema. But these findings may give the possibility of granuloma or SOL as was seen in our case, therefore, the gold standard for diagnosis is histopathology. Vasquez *et al* [12] and Hwang *et al* [13] have also reported actinomyces presenting as brain abscess.

Despite the availability of various therapeutic options, the choice therapy seems to consist of high doses of beta-lactams, to which we firstly added rifampicin, in order to amplify the

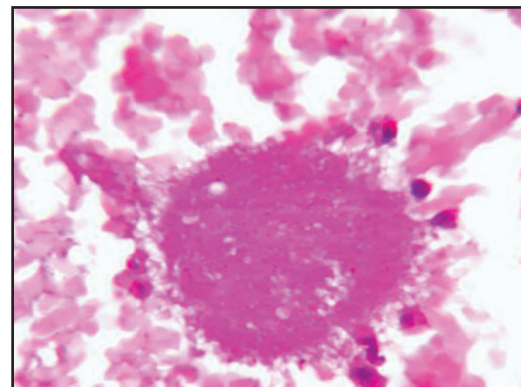


Figure 3: PAS stained smear showing PAS positive filamentous structures consistent with actinomyces.

bactericidal effect and diffusion in the CNS. Although variable, the duration of therapy should be a long-term therapy, up to 12 months.

CONCLUSION

Despite a good prognosis, actinomyces brain abscess, if not treated on time, can be fatal to the patient. Thus early diagnosis and treatment is necessary.

REFERENCES

1. Mandell GL, Bennet JE, Dolin R. Principles and practice of Infectious Diseases. (7th edn), Elsevier Churchill Livingstone 2010;51:636-7.
2. Van Dellen JR. Actinomycosis: an ancient disease difficult to diagnose. *World Neurosurg* 2010;74:263-4.
3. Riesgo P, Orozco M, Piquer J, Cortés F, Botella C, Navarro J, Cabanes J. Absceso cerebral actinomicótico: caso clínico. *Neurocirugía* 1996;7:230-4.
4. Ewald C, Kuhn S, Kalf R. Pyogenic infections of the central nervous system secondary to dental affections. A report of six cases. *Neurosurg Rev* 2006;29:163-7.
5. Nithyanandam S, D'Souza O, Rao SS, Battu RR, George S. Rhinorbitocerebral actinomycosis. *Ophthalm Plast Reconstr Surg* 2001;17:134-6.
6. Roth J, Ram Z. Intracranial infections caused by Actinomyces species. *World Neurosurg* 2010;74:261-2.
7. Akhaddar A, Elmostarchid B, Boucetta M. Primary subdural empyema after spontaneous vaginal delivery. *Surg Infect* 2009;10:363-4.
8. Wong VK, Turmezei TD, Weston VC. Actinomycosis. *BMJ* 2011;343:d6099.
9. Clancy U, *et al.* Actinomycetomeyeri brain abscess following dental extraction. *BMJ Case Rep* 2015;doi:10.1136/bcr-2014-207548.
10. Kononen E, Wade WG. Actinomyces and related organisms in human infections. *Clin Microbiol Rev* 2015;28:419-42.
11. Soto-Hernández JL, Morales VA, Lara Giron JC, Balderrama Bañares J: Cranial epidural empyema with osteomyelitis caused by Actinomyces, CT, and MRI appearance. *Clin Imaging* 1999;23:209-14.
12. Vazquez Guillamet LJ, Malinis MF, Meyer JP. Emerging role of *Actinomycetomeyeri* in brain abscesses: A case report and literature review. *IDCases* 2017;10:26-29.
13. Hwang CS, Lee H, Hong MP, Kim JH, Kim KS. Brain abscess caused by chronic invasive actinomycosis in the nasopharynx: A case report and literature review. *Medicine (Baltimore)* 2018;97:e0406.

Funding: None; Conflict of Interest: None Stated.

How to cite this article: Khare M, Wade Z, Gupta H, Bhardwaj L, Kumawat N, Ola V. A case of brain abscess caused by actinomyces mimicking glioma: A rare presentation. *Indian J Case Reports*. 2019;5(3):215-216.

Doi: 10.32677/IJCR.2019.v05.i03.005