

Isolated multiple cutaneous verruciform xanthomas

Hari S Pathave, Vivek V Nikam

From Department of Dermatology, Seth GS Medical College and KEM Hospital, Mumbai, India.

Correspondence to: Dr. Hari S Pathave, Department of Dermatology, Seth GS Medical College & KEM Hospital, Parel, Mumbai - 400012, India. E-mail: haripathave@gmail.com.

Received - 21 March 2019

Initial Review - 05 April 2019

Accepted - 29 April 2019

ABSTRACT

Verruciform xanthoma (VX) is a rare benign skin condition, primarily of the oral mucosa that can also affect the skin and genital mucosa. The etiology is not yet completely understood; though its association with conditions of chronic inflammation or trauma, chronic lymphedema, chronic graft versus host disease and CHILD syndrome are mentioned in the literature. Here, we report the case of multiple verruciform xanthomas on the bilateral forearms and upper back of a 25-year-old man in the absence of chronic skin disease or systemic disease and surprisingly, he didn't have mucosal VX too. Histopathology of the lesion showed nodular dense infiltrate of foamy macrophages in the papillary dermis which stained positive for CD68.

Keywords: Foamy macrophages, Upper extremity, Verruciform xanthoma.

Verruciform xanthoma (VX) is a rare benign proliferative lesion of the oral cavity, mostly seen in middle-aged to elderly men with some predisposing factors. Most commonly, the lesion has a verruciform appearance, but it may appear polypoid, papillomatous, or sessile. An incidence rate of VX is about 0.025-0.05% of all the pathology cases and hence, are usually diagnosed clinically as papillomas [1]. The presence of large numbers of CD68 positive lipid-laden foamy histiocytes in the dermal papillae form the hallmark in its diagnosis [2].

CASE REPORT

A 25-year-old male presented to the department with a complaint of mild pruritic multiple warty skin lesions present on bilateral

forearms and upper back. One year ago, he noticed a few asymptomatic elevated skin lesions on both forearms without underlying chronic skin disease. Over a period of time, the lesions increased in size and similar lesions appeared on other areas of forearms and upper back. There was no history of trauma, insect bite or photosensitivity. He denied a history of similar lesions in the past and had no other dermatologic complaint. There was no family history of similar lesions. There was no history of the oral or genital mucosal lesion. There was no history of lymphedema, bone marrow or organ transplant in the patient.

On general examination, the patient didn't show any significant abnormalities and his vitals were stable. Cutaneous examination revealed multiple skin-coloured to brown papules of size ranging from 1mm to 7mm on apparently normal skin on the bilateral

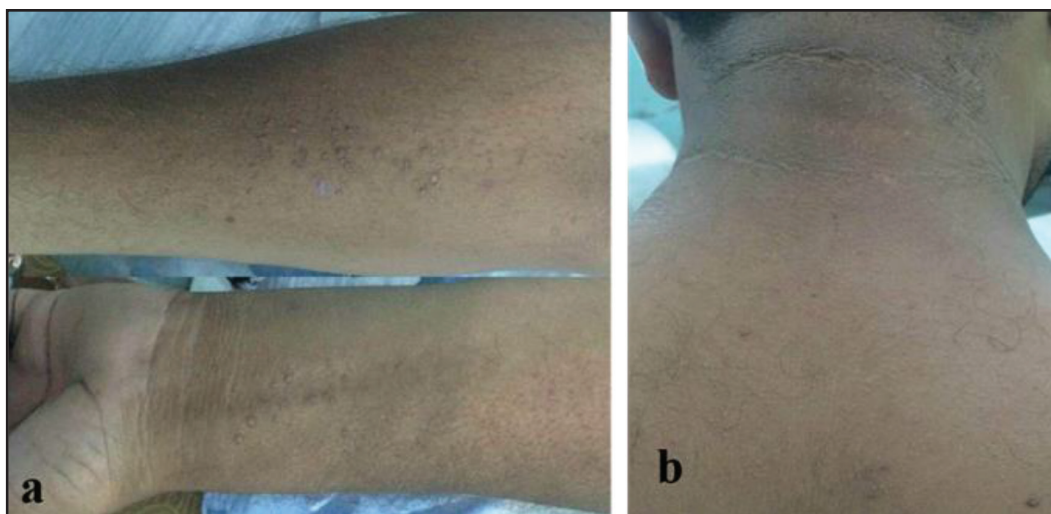


Figure 1: (a) Multiple skin coloured to brown verrucous papules on an apparently normal skin on the bilateral forearms; (b) Discrete verrucous papules on the upper back

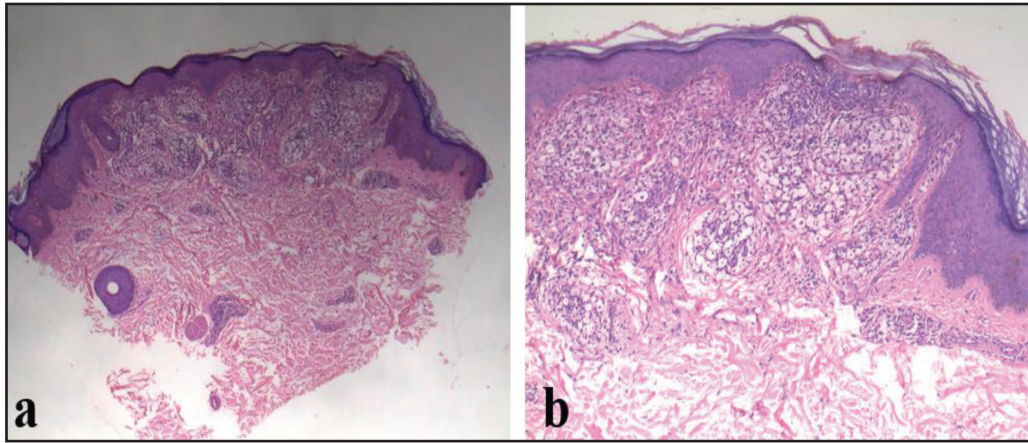


Figure 2: (a) Mild orthohyperkeratosis, foci of parakeratosis, gentle mammillation of surface, acanthosis, foamy macrophages in papillary dermis and non-exophytic nature of lesion (H and E, x4); (b) Dense infiltrate of foamy macrophages filling up the papillary dermis with elongated and incurved rete ridges at the margin (H and E, x10)

forearms and upper back (Fig. 1). The surface of the papules was rough and verrucous with a hyperpigmented rim. Some of them were arranged in a linear fashion. On the basis of clinical appearance and the history of the rapid evolution of the lesions, a provisional diagnosis of verruca vulgaris was considered. An excisional biopsy was performed from the largest lesion of the forearm. Oral and genital mucosae were normal.

Histopathology showed mild orthohyperkeratosis, foci of parakeratosis, gentle mammillation of surface and acanthosis (Fig. 2a). Characteristic dense infiltrate of foamy macrophages was seen filling up the papillary dermis with elongated and incurved rete ridges at the margin (Fig. 2b). The reticular portion of the connective tissue was free of these foamy macrophages. Furthermore, the immunohistochemical staining for CD68 was positive for these macrophages (Fig. 3). There were no koilocytes or vacuolated keratinocytes in the epidermis. Hence a diagnosis of VX was made. The affected extremities didn't show edema or erythema. Thorough systemic examination didn't reveal any abnormality. Fasting lipid profile was within normal limit. We performed surgical excision of all VX lesions, but he didn't follow up with us, hence we couldn't interpret about the recurrence of lesions.

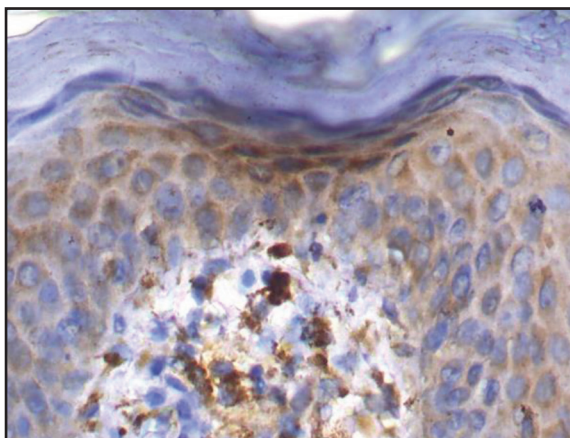


Figure 3: Foamy cells with strong cytoplasmic CD68 immunostaining (IHC stain, x40)

DISCUSSION

Verruciform xanthoma (VX) was first named in 1971 by Shafer [2]. VX is an uncommon clinicopathologic entity that predominantly affects the oral cavity and sometimes skin and genital mucosa [3]. Clinically, VX appears as a papule or single plaque showing verrucous or papillomatous growth that may be mistaken for a viral wart, benign, premalignant and malignant conditions. Differential diagnosis includes verruca vulgaris, verrucous carcinoma and other verrucous dermatoses. The lesions of verruca vulgaris are usually circumscribed, firm, elevated papule with the papillomatous hyperkeratotic surface [4]. Furthermore, histopathology of verruca vulgaris lesions has characteristic koilocytes or vacuolated keratinocytes. Verrucous carcinoma lesions are almost always large, exophytic, soft, fungating, slow-growing neoplasms with a pebbly mamillated surface [5]. Differentiation is made on the basis of histopathology. In our case, multiple verrucous papules and small plaques were present on upper extremity and upper back and a few of them were arranged in a linear fashion, hence wart was the differential diagnosis.

Histologically, VX is characterized by the presence of parakeratinized epithelium showing papillary or verrucous growth with thin rete ridges and connective tissue papillae extending up to the surface. The papillae are characteristically filled with foam cells also called xanthoma cells (Xanthos = yellow). These cells are not seen beneath the level of the adjacent rete ridges and may completely fill the papilla. The diagnostic hallmark of VX is the presence of xanthoma cells within the dermal papillae [6].

Nowparast *et al.* [7] demonstrated three architectural appearances of VX when viewed under a light microscope: (a) a warty or verrucous appearance; (b) a papillary or cauliflower architecture and (c) a slightly raised or flat lesion. Three histological subtypes (types A, B, and C) have been described based on the texture of the surface epithelium. Lesions of the verrucous type (A) have hyperparakeratosis, verrucous type acanthosis, and elongation of the rete ridges. The papillary form

(B) has many finger-like projections composed of stratified squamous epithelium containing connective tissue cores. In the flat type (C), mild acanthosis and subtle thin parakeratosis with variable elongation of rete ridges are commonly observed [8]. In our case, histopathology showed mild hyperkeratosis and foci of parakeratosis, mild papillomatosis and acanthosis with foamy macrophages in connective tissue papillae and elongated incurved rete ridges. These findings were consistent with VX of type C.

The etiopathogenesis of verruciform xanthoma remains unclear. Postulated factors include immunologic factors, local inflammation and viral etiology. Ultrastructure and in situ hybridization from lesions of verruciform xanthoma have failed to demonstrate human papilloma virus making a viral etiology unlikely [9].

VX of extramucosal sites and mostly of the extremity is present on chronic skin diseases, such as lichen sclerosus, recessive dystrophic epidermolysis bullosa, and pemphigus vulgaris. Epidermolysis bullosa [10], CHILD syndrome [11], GVHD [12] and lymphedema [13] are some associations of VX on the extremity. But in our case, even though there were multiple VX on upper extremity and upper back, a thorough examination didn't reveal any chronic skin disease or syndrome. Blankenship *et al.* [14] described a similar case of solitary VX on upper extremity without chronic skin disease or syndrome. Treatment of verruciform xanthoma includes pulse dye laser, cryosurgery, electrocautery and surgical excision. Successful treatment with imiquimod is also reported [15].

CONCLUSION

Verruciform xanthoma is often encountered on the gingival mucosa. Our case is a rare presentation of multiple verruciform xanthomas on the upper extremity and back. This case also goes counter to the belief that verruciform xanthoma cannot arise as a distinct clinical entity but must be a manifestation of an underlying skin disorder. This condition present on the extramucosal areas is a diagnostic challenge for dermatologists.

REFERENCES

- Hegde U, Doddawad VG, Sreeshyla HS, and Patil R. Verruciform xanthoma: A view on the concepts of its etiopathogenesis. *J Oral Maxillofac Pathol.* 2013;17:392-6.
- Shafer WG. Verruciform xanthoma. *Oral Surg Oral Med Oral Pathol.* 1971;31:784-89.
- Damm DD, Fantasia JE. Rough white patch of gingiva. Verruciform Xanthoma. *Gen Dent.* 2002;50:378-80.
- Desai VD, Sharma R, Bailoor DN. Extensive mucocutaneous verruca vulgaris in a non-immunocompromised patient. *Int J Clinic Paediatric Dent.* 2011;4:65-8.
- Walvekar RR, Chaukar DA, Deshpande MS, Pai PS, Chaturvedi P, *et al.* Verrucous carcinoma of the oral cavity: A clinical and pathological study of 101 cases. *Oral Oncol.* 2009;45:47-51.
- Yu CH, Tsai TC, Wang JT, Liu BY, Wang YP, Sun A. Oral verruciform xanthoma: a clinicopathologic study of 15 cases. *J Formos Med Assoc.* 2007;106:141-7.
- Nowparast B, Howell FV, Rick GM. Verruciform xanthoma: A clinicopathologic review and report of fifty four cases, *Oral Surg Oral Med Oral Pathol.* 1981;51:619-25.
- Bhalerao S, Bhat P, Chhabra R, Tamgadge A. Verruciform xanthoma of buccal mucosa: A case report with review of literature. *Contemp Clin Dent.* 2012;3(2):57-9.
- Sah K, Kale AD, Hallikerimath S. Verruciform xanthoma: Report of two cases and review on pathogenesis. *J Oral Maxillofac Pathol.* 2008;12:41-4.
- Murat-Susic S, Pastar Z, Dobric I *et al.* Verruciform xanthoma in recessive dystrophic epidermolysis bullosa hallopeau-siemens. *Int J Dermatol.* 2007;46(9):955-9
- Hashimoto K, Prada S, Lopez AP, Hoyos JG, Escobar M. CHILD syndrome with linear eruptions, hypopigmented bands, and verruciform xanthoma. *Pediatr Dermatol.* 1998;15:360-6.
- Helm KF, Hopfl RM, Kreider JW, Lookingbill DP. Verruciform xanthoma in an immunocompromised patient: a case report and immunohistochemical study. *J Cutan Pathol.* 1993;20(1):84-6.
- Snider RL. Verruciform xanthomas and lymphedema. *J Am Acad Dermatol.* 1992;27:1021-3.
- Blankenship DW, Zech L, Mirzabeigi M, Venna S. Verruciform xanthoma of the upper-extremity in the absence of chronic skin disease or syndrome: a case report and review of the literature. *J Cutan Pathol.* 2013;40:745-52.
- Guo Y, Dang Y, Toyohara JP, Geng S. Successful treatment of verruciform xanthoma with imiquimod. *J Am Acad Dermatol.* 2013;69(4):184-6.

Funding: None; Conflict of Interest: None Stated.

How to cite this article: Pathave HS, Nikam VV. Isolated multiple cutaneous verruciform xanthomas. *Indian J Case Reports.* 2019;5(3):211-213.

Doi: 10.32677/IJCR.2019.v05.i03.004