

A rare case of unruptured rudimentary horn pregnancy

Triveni GS¹, Nihita Pandey², Prabha Lal³, Abha Singh⁴

From ¹Assistant Professor, ²Senior Resident, ³Professor, ⁴Director Professor and HOD, Department of Obstetrics & Gynaecology (OBG), Lady Hardinge Medical College, Shaheed Bhagat Singh, Road, DIZ Area, Connaught Place, New Delhi, India.

Correspondence to: Dr Nihita Pandey, Department of Obstetrics & Gynaecology (OBG), Flat B-06, Vrindavan Apartment, Plot No.1, Dwarka Sector 6, New Delhi, Delhi - 110001, India. E-mail: kneeheeta@gmail.com

Received - 29 April 2019

Initial Review - 18 May 2019

Accepted - 23 May 2019

ABSTRACT

Mullerian anomalies are a rare disorder and pregnancy in a rudimentary horn is one of the rarest forms of an ectopic pregnancy. This rarity proves to be an obstacle in the timely diagnosis and management of such cases. Thereby, it often culminates in catastrophic events such as rupture of the rudimentary horn which can claim the life of the mother. In this case report, we study the presentation of a 27-year-old primigravida who was presented at 16 weeks gestation, with an intrauterine fetal demise and failed induction of labor. This case report highlights how the diagnosis of a rudimentary horn pregnancy is often missed and the pregnancy was prolonged. We also aim to emphasize the importance of keeping the possibility of a rudimentary horn pregnancy in mind while dealing with the failure of second-trimester pregnancy termination.

Keywords: Ectopic pregnancy, Extrauterine pregnancy, Mullerian anomaly, Rudimentary horn pregnancy.

Mullerian anomalies develop in a female due to non-fusion of the paramesonephric duct or failure of its resorption during embryonic development [1]. Uterine congenital anomalies are a rare entity with Mullerian defects being detected in only 3.2% of the fertile population [2]. The incidence of a unicornuate uterus is even rarer, accounting for only 2.4%-13% of all Mullerian defects [2]. However rarer, still is the phenomenon of pregnancy in a non-communicating horn of a unicornuate uterus [3]. It has been stipulated that the incidence of rudimentary horn pregnancy ranges from 1 in 76000 to 1 in 140000 pregnancies [4,5]. These pregnancies characteristically progress undetected until they rupture in the 2nd or 3rd trimester leading to life-threatening intra-peritoneal hemorrhage. Hence, it is imperative that we diagnose these pregnancies in the pre-rupture phase and avoid imminent catastrophe. Here we present a case of 27-year old female who was brought primigravida to our hospital.

CASE REPORT

A 27-year-old primigravida was presented to a tertiary care hospital at 16 weeks gestation with complaints of lower abdominal pain since the past 5 days and an intra-uterine fetal demise. The patient had previously been admitted at a private hospital where induction of labour was attempted. She was given 4 doses of Tab Misoprostol 400 mcg followed by syntocinon augmentation. When she did not respond, the decision of D & E was taken under USG guidance but had to be abandoned because the cervix could not be negotiated. Dinoprostone gel was instilled but since the patient did not respond to it either, the further procedure was

abandoned and the patient was referred to our center, which is a tertiary care hospital.

On admission, her vitals were stable. On abdominal examination, uterus was 16 weeks old, relaxed, non-tense and non-tender. On speculum examination, there was no bleeding or discharge. On vaginal examination, cervical os was closed and mid-posed, cervix was 3 cm in length.

Her investigations showed a hemoglobin of 11.3 gm/dl, total leucocyte count of 10,500/cu.mm and a platelet count of 1.86 lakh/cmm. Her coagulation profile, liver, and renal tests were within normal limits. Her trans abdominal ultra sound showed a single intra-uterine pregnancy with a fetus of 15 weeks with absent cardiac activity. Amniotic fluid was normal and the placenta was situated anteriorly.

A transvaginal scan by a senior gynecologist revealed an empty uterine cavity adjacent to the cavity containing the fetus,

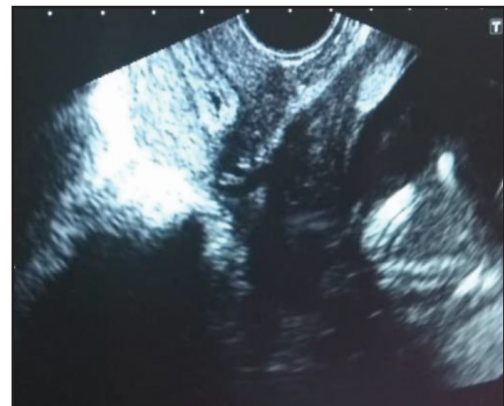


Figure 1: Ultrasound image showing empty uterine cavity at left upper corner and the extrauterine fetus in the right lower corner.

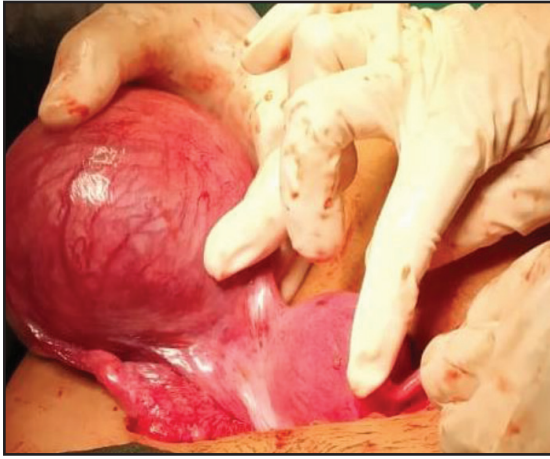


Figure 2: Unicornuate Uterus with Non-Communicating Rudimentary Horn with pregnancy

there by signifying a pregnancy in a rudimentary uterine horn with a differential diagnosis of a secondary abdominal pregnancy (Fig. 1). The patient was counseled for a laparotomy.

On exploratory laparotomy, a unicornuate uterus with a right-sided non-communicating rudimentary horn was seen. The rudimentary horn measuring 8 x 7 cm carried the pregnancy and was as yet unruptured. Bilateral tubes and ovaries were normal. The rudimentary horn was excised along with the fetus inside. The right-sided fallopian tube, round ligament and utero ovarian ligament was clamped, cut and excised followed by clamping and cutting the base of the rudimentary horn. The resultant defect was then sutured in two layers. The unicornuate uterus with the non-communicating horn is shown in Fig. 2 and the extracted fetus is shown in Fig. 3.

The patient had an uneventful postoperative period and was discharged on day 10 after suture removal. She was counseled for the need of good antenatal care and elective cesarean delivery in the subsequent pregnancy.

DISCUSSION

A unicornuate uterus with a rudimentary horn develops when there is incomplete development of one Mullerian duct along with an incomplete fusion of this duct with the contralateral site. As per the American Fertility Society Classification of Mullerian Anomalies, a non-communicating rudimentary horn comes under class 2B. The rudimentary horn in a unicornuate uterus is non-communicating 83% of the times [6]. Many imaging modalities such as 2D or 3D Ultrasonography, CT scan, MRI and laparoscopy, can be used to aid the diagnosis of this rare congenital abnormality [7]. Many researchers such as Fedele *et al* have found ultrasonography to be a useful method in the diagnosis of the rudimentary horn. Although it has been postulated that the sensitivity of this procedure is only 26% and progressively decreases as the gestational age increases [8,9].

Pregnancy in a non-communicating rudimentary horn occurs as a result of transperitoneal migration of either the spermatozoa or the fertilized ovum, which then enters the contra lateral tube and implants in the rudimentary horn [10]. Tsafirir *et al* reported

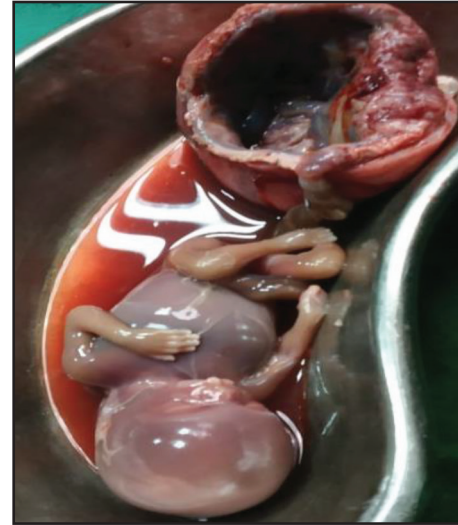

Figure 3: Excised rudimentary horn with fetus

2 cases of rudimentary horn pregnancy and laid down the criteria for diagnosing it using the following ultrasonographic features- 1) a pseudo pattern of asymmetric bicornuate uterus; 2) absent visual continuity of the tissue surrounding the gestational sac and the uterine cervix; and 3) presence of myometrial tissue surrounding the gestational sac [11]. In spite of this there is a full possibility of this diagnosis to remain elusive. Often, labour inducing agents are used for terminating pregnancy in an undiagnosed case of rudimentary horn pregnancy which leads to failure of termination or may at times lead to rupture of the horn [12]. A similar case was reported by Ambusaidi *et al* wherein, a patient presented at 23 weeks with fetal demise and failure of labour induction [13]. In our case also, the patient was induced with prostaglandins and D & E had been attempted which was unsuccessful. These interventions could have caused a possible rupture of the horn, but her timely diagnosis prevented this mishap. This highlights the importance of maintaining a high index of suspicion in cases where labour induction has failed.

Surgery is the modality of treatment, even in unruptured cases [9]. The choice of laparoscopic removal or exploratory laparotomy depends on the skill set of the surgeon as well as the availability of necessary facilities. Laparoscopic removal is usually possible only in early pregnancy when the size of the rudimentary horn and the accompanying fetus is not too large [14]. It is also imperative that patients should be evaluated for renal anomalies since they are usually co-existent [9].

CONCLUSION

This case highlights the importance of maintaining a high index of suspicion and investigating accordingly whenever a patient presents with a failure of labour induction in the second trimester. With the advent of newer imaging modalities, it is now possible to diagnose this condition with increasing accuracy, provided this differential has been entertained by the health provider. Timely diagnosis and management can avert imminent catastrophe and contribute to improving the obstetric outcome of the patient. Wherever possible, a rudimentary horn should be excised in the non-pregnant state itself.

REFERENCES

1. Oza H.V., Vohra H.M. *et al.* Pregnancy in Rudimentary Horn: A rare entity. Gujarat Medical Journal 2015;70:65-6.
2. Simon C, Martinez L, Pardo F, Tortajada M, & Pellicer A. Mullerian defects in women with normal reproductive outcome. Fertility and Sterility 1991;56:1192-3.
3. Tufail A, Hashmi HA. Ruptured ectopic pregnancy in rudimentary horn of the uterus. J Coll Physicians Surg Pak 2007;17:105-6.
4. Johansen K. Pregnancy in a rudimentary horn: two case reports. Obstet Gynecol 1969;34:805-8
5. Nahum GG. Rudimentary uterine horn pregnancy: a case report on surviving twins delivered eight days apart. J Reprod Med 1997;42:525-32.
6. Heinonen PK: Unicornuate uterus and rudimentary horn. Fertil Steril 1997;68:224-30.
7. Nanda S, Dahiya K, Sharma N, Aggarwal D, Sighal SR, Sangwan N. Successful twin pregnancy in a unicornuate uterus with one fetus in the non-communicating rudimentary horn. Arch Gynecol Obstet 2009;280: 993-5.
8. Fedele L, Dorta M, Vercellini P, Brioschi D, Candiani GB. Ultrasound in the diagnosis of subclasses of unicornuate uterus. Obstetrics and Gynecology 1988;71:274-7.
9. Jayasinghe Y, Rane A, Stalewski H, Grover S. The presentation and early diagnosis of the rudimentary uterine horn. Obstetrics and Gynecology 2005;105:1456-67.
10. Scholtz M. A full-time pregnancy in a rudimentary horn of the uterus. British Journal of Obstetrics & Gynaecology 1951;58:293-6.
11. Tsafirir A, Rojansky N, Sela H Y, Gomori J, Nadjari M. Rudimentary horn pregnancy: first-trimester prerule sonographic diagnosis and confirmation by magnetic resonance imaging. Journal of Ultrasound in Medicine 2005;24:219-23.
12. Kanagal DV, Hanumanalu LC. Ruptured Rudimentary Horn Pregnancy at 25 Weeks with Previous Vaginal Delivery: A Case Report. Case Reports in Obstetrics and Gynecology 2012; Article ID 985076:4.
13. Ambusaidi Q, Jha S. Pregnancy in the rudimentary horn. Sultan Qaboos Univ Med J 2014;14:e134-8.
14. Dicker D, Nitke S, Shoenfeld A, Fish B, Meizner I, Ben-Rafael Z. Laparoscopic management of rudimentary horn pregnancy. Human Reproduction 1998;13:2643-44.

Funding: None; Conflict of Interest: None Stated.

How to cite this article: Triveni GS, Pandey N, Lal P, Singh A. A rare case of unruptured rudimentary horn pregnancy. Indian J Case Reports. 2019;5(3): 271-273.

Doi: 10.32677/IJCR.2019.v05.i03.026