

Laparoscopic management of early stage primary fallopian tube carcinoma

Kavitha Yogini Duraisamy¹, Devi Balasubramaniam², Karthikha Ravi³, Aravinth Balasubramaniam⁴

From ¹Head of Department, ²Consultant, ³Resident, Department of Endogynaecology, ⁴Consultant, Department of Pathology, Gem Hospital and Research Centre, Coimbatore, Tamil Nadu, India

Correspondence to: Dr. Karthikha Ravi, Department of Endogynaecology, Gem Hospital and Research Centre, 45, Pankaja Mills Road, Ramanathapuram, Coimbatore - 641045, Tamil Nadu, India. E-mail: karkate29@yahoo.co.in

Received - 02 February 2019

Initial Review - 21 February 2019

Accepted - 31 March 2019

ABSTRACT

Primary fallopian tube cancer (PFTC) is a rare malignancy with an incidence of 0.14-1.8% of all genital malignancies. Presentations of fallopian tube cancer are mostly nonspecific and include abdominal pain, profuse watery or serosanguinous discharge. Here, we present the case of a 51-year-old patient with FIGO stage 1A PFTC. It was diagnosed as hematosalpinx intraoperatively, during total laparoscopic hysterectomy and diagnosed as PFTC on histopathology. Further management was by laparoscopic staging. A high index of suspicion is needed in peri and postmenopausal women who present with unexplained uterine bleeding, profuse discharge, pelvic pain, adnexal mass or abnormal pap smear.

Keywords: Histopathology, Primary fallopian tube cancer, Staging laparoscopy.

Primary fallopian tube cancer (PFTC) is the least common of all gynecological malignancies with an incidence of about 3.6 per million women per year. It accounts for 0.14-1.8% of all female genital malignancies [1]. More than 90% of fallopian tube carcinomas are serous or high-grade endometrioid adenocarcinoma. The peak incidence is between 60-64 years of age, with a mean age of incidence of 55 years (range 17-88 years) [2]. Etiology remains unclear and it could be due to hormonal, reproductive or genetic factors. There is a correlation with nulliparity, infertility, and pelvic inflammatory disease. High parity has been reported to be protective while the use of oral contraceptives and pregnancy decreases the risk of PFTC [1]. Hereditary factors constitute 10 % of fallopian tube cancer and include mutations in BRCA1 (20-50%), BRCA 2(10-20%), type 2 Lynch syndrome, an inherited mutation in ARID1 [3]. Hence, patients with a strong family history are advised to have risk-reducing bilateral salpingo-oophorectomy after completing childbirth. The incidence of PFTC in risk-reducing surgeries in BRCA was 5.7% and distal fallopian tube seemed to be the dominant site of malignancy [4].

Early stage PFTC is very rare as most fallopian tube cancers are identified at later stages. A high index of suspicion is needed in peri and postmenopausal women presenting with recurrent vaginal discharge with normal endometrial histopathology. We present the case of a 51-year-old patient with PFTC.

CASE REPORT

A 51-year-old P3L2A1 woman, postmenopausal since 3 years presented with complaints of blood-stained discharge per vagina for 2 months and was not associated with pruritus or foul-smell.

She had no history of abdominal pain, postmenopausal bleeding or perimenopausal abnormal uterine bleeding (AUB). Bowel and bladder habits were normal. She was on treatment for palpitation and hypothyroidism. History of open sterilization 23 years ago and laparoscopic cholecystectomy 10 years ago were present. She has no family history of malignancy. She attained menarche at 12 years of age, married at 18 years of age, attained menopause at 48 years of age. The obstetric score was P3L2A1, NVD, last childbirth (LCB) at 28 years, age at first childbirth was 19 years of age.

She was overweight on examination with Body mass index (BMI) 29. There was no pallor, no pedal edema or lymphadenopathy. The blood pressure was 130/80 mmHg, pulse rate 92/min and SpO₂-97% in room air. Abdominal examination showed 3 cm suprapubic transverse scar. On per speculum examination, the cervix was healthy and no discharge was noted. On bimanual pelvic examination, the uterus was bulky, no adnexal mass or tenderness was present.

Pap smear was negative for intraepithelial lesion or malignancy, endometrial biopsy showed proliferative endometrium. Ultrasound (USG) revealed bulky uterus with 2 small intramural fibroids. Computed Tomography (CT) scan showed bulky uterus with small fibroid and ovaries were normal.

In view of persistent blood stained discharge, the patient was advised total laparoscopic hysterectomy (TLH) with bilateral salpingo-oophorectomy. She was counseled regarding the rare chance of malignancy and need for revision surgery. TLH with bilateral salpingo-oophorectomy and uterosacral colpopexy was done. Intraoperative findings were as follows: uterus was bulky, multiple small fibroids were present, and the largest fibroid was in the anterior wall of about 3 x 2cm in size. Right tube and both

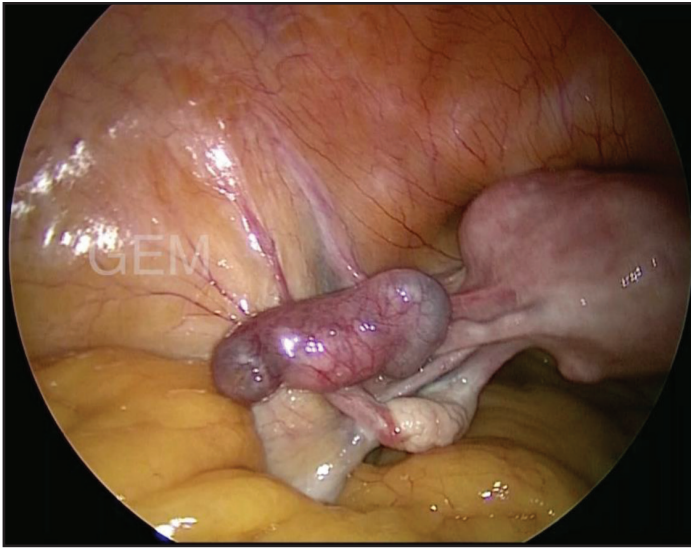

Figure 1: Intraoperative finding of the left fallopian tube with primary fallopian tube carcinoma

ovaries were normal. Left tube was enlarged in size (3 x 2 cm), which was suggestive of hydrosalpinx (Fig. 1).

The specimen was sent for histopathology. Macroscopic findings on histopathological examination (HPE) were leiomyoma uterus, 5 x 2cm left tube and 2 x 2 cm mass occupying the center of the fallopian tube. It was pale, homogenous with cystic and hemorrhagic degeneration. Microscopic examination shows that the left fallopian tube serosa was intact and there was high-grade serous carcinoma with no surface involvement P (T1aNx), (Fig. 2).

Staging laparoscopy with transperitoneal high paraaortic lymphadenectomy (A2, B1), bilateral pelvic lymphadenectomy with infracolic omentectomy, peritoneal washing, and peritoneal biopsy was done on the 9th postoperative day (POD). CA125 done was 65.1 mU/ml. Histopathology of lymph node was negative for malignancy. As it was diagnosed as PFTC stage 1A, high-grade serous, postoperatively chemotherapy was advised. A follow-up of the patient was scheduled after 3 months but unfortunately, the patient lost to follow-up.

DISCUSSION

Clinical presentations of fallopian tube cancer are non-specific and include abdominal pain, profuse watery or pinkish discharge, adnexal mass, and abnormal vaginal bleeding. Latzko's triad of symptoms consisting of intermittent profuse serosanguinous vaginal discharge, colicky abdominal pain relieved by discharge and abdominal or pelvic mass has been reported in 15% of cases. Hydrops tubae profluens, a pathognomonic feature is characterized by intermittent discharge of clear or blood-tinged fluid spontaneously or on pressure followed by shrinkage of the adnexal mass and occurs in 5% of patients [5]. The rate of preoperative diagnosis is very less and is about 0-10% [6]. In our case, only profuse discharge was present.

As PFTC has a worse prognosis compared to Epithelial Ovarian Cancer (EOC) in advanced stages, a high index of

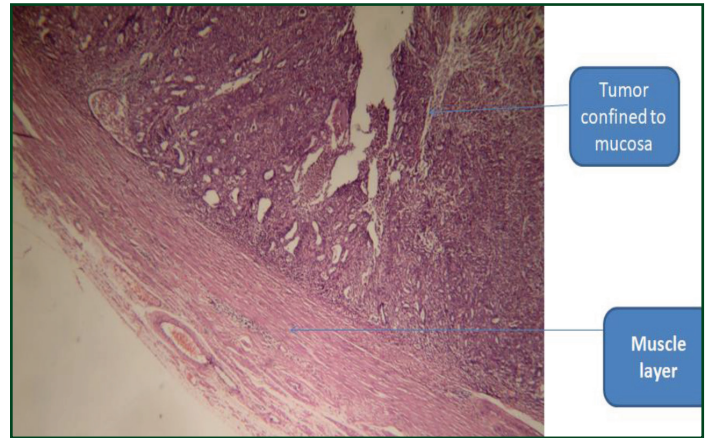


Figure 2: Histology showing tumor confined to the mucosa

suspicion is needed for the diagnosis of PFTC. It has been previously presumed that fallopian tube malignancies were rare. However, it has now been challenged and studies show that many tumors that were classified as serous carcinomas of the ovary or peritoneal cancers appear to have their origin in the fallopian tube. This led to the International Federation of Gynaecology and Obstetrics (FIGO) to stage all three carcinomas similarly. Hence, there is a strict criterion for the diagnosis of PFTC. The diagnostic criteria for PFTC were first established by Hu et al and modified by Sidles. PFTC is diagnosed if: grossly, the main tumor is in the tube and arises from the endosalpinx; the histological pattern reproduces the epithelium of tubal mucosa; transition from benign to malignant tubal epithelium should be demonstrated and ovaries and endometrium should be either normal or have a much smaller tumor volume than that of the tube [7].

Preoperative diagnosis may be picked up by imaging. On USG, findings of tubal carcinoma are nonspecific and appear similar to an ovarian tumor or tubo-ovarian abscess. Suspicious findings are a cystic mass with spaces and mural nodules, a sausage-shaped mass or a multilobular mass with a cog-and-wheel appearance [8]. CT and magnetic resonance imaging (MRI) are better modalities in the diagnosis of PFTC. MRI may also be helpful in detecting adjacent soft tissue involvement. Serum CA125 done preoperatively has been found to be an additional independent prognostic factor in overall survival rate and disease-free interval [9]. It also has a high sensitivity (92%) and specificity (90%) for follow-up.

Initial management of PFTC is surgical, similar to that of ovarian carcinoma management. After surgical staging, postoperative chemotherapy with a platinum-based regimen is usually recommended in patients, except in those diagnosed with well-differentiated Stage IA and B disease. In cases of incidentally picked up PFTC in specimen done for benign cases, completion staging must be done. In patients with apparent early-stage carcinoma not willing for surgery, adjuvant chemotherapy is recommended, as there is a 33% incidence of upstaging [10].

In advanced stages, treatment is optimal cytoreductive surgery followed by adjuvant platinum-based chemotherapy. Surgical staging, optimal cytoreduction, grade, lymph node status and pathologic type are important factors in influencing the survival rate. Also, pelvic lymphadenectomy [11] and para-aortic lymphadenectomy [12] is necessary for comprehensive staging and improves survival rate. The lymphatic flow from the fallopian tubes drains to the pelvic nodes through lymphatic channels located near the proximal part of the uterus and the distal part of the tubes and fimbria have lymphatic channels connected to the para-aortic nodes. Even though there are few studies on the lymphatic spread of PFTC, it is estimated that pelvic and para-aortic lymphadenectomy was equally significant for halting the lymphatic spread. Sometimes para-aortic lymphadenectomy might be more important than pelvic lymphadenectomy [12].

Most of the reports in the literature include surgery by laparotomy. We have managed our case with TLH with bilateral salpingo-oophorectomy and followed it up with staging laparoscopy. It has been demonstrated that laparoscopy is as efficacious as laparotomy in the management of selected patients of early ovarian carcinoma [13] and fallopian tube carcinoma. The 5-year survival rate as per FIGO is 65% in stage 1, 50-60% in stage 2 and 10-20% for stage 3 and 4. Follow-up is by history, clinical examination, imaging with USG or CT and CA125. Follow up is done 3 monthly for the first 2 years, 6 monthly till 5 years and then annually.

CONCLUSION

Primary fallopian tube carcinoma is a rare malignancy that accounts for less than 1% of gynecological malignancies. Preoperative diagnosis of fallopian tube carcinoma is difficult due to nonspecific symptoms and is usually diagnosed on histopathology. PFTC histologically and clinically resembles epithelial ovarian carcinoma and is now included in the same staging system as per FIGO staging. A high index of suspicion is needed in peri and postmenopausal women who present with unexplained uterine bleeding and discharge.

REFERENCES

1. Riska A, Leminen A. Determinants of incidence of primary fallopian tube carcinoma (PFTC). *Methods Mol Biol* 2009;472:387-96.
2. Cohen CJ, Thoas GM, Hagopian GS, Kufe DW, Pollock RE, Holland JF, *et al.* Neoplasms of the fallopian tube cancer medicine. 5th ed. Canada, B.C: Decker Inc 2000;1683.
3. Zweemer RP, Van Diest PJ, Verheijen RH, Ryan A, Gille JJ, Sijmons RH, *et al.* Molecular evidence linking primary cancer of the fallopian tube to BRCA1 germline mutations. *Gynecol Oncol* 2000;76:45-50.
4. Callahan MJ, Crum CP, Medeiros F, Kindelberger DW, Elvin JA, Garber JE, *et al.* Primary fallopian tube malignancies in BRCA-positive women undergoing surgery for ovarian cancer risk reduction. *J Clin Oncol* 2007;25:3985-90.
5. Kalampokas E, Kalampokas T, Tourontous I. Primary fallopian tube carcinoma. *Eur J Obstet Gynecol Reprod Biol* 2013;169:155-61.
6. Koo YJ, Im KS, Kwon YS, Lee IH, Kim TJ, Lim KT, *et al.* Primary fallopian tube carcinoma: a clinicopathological analysis of a rare entity. *Int J Clin Oncol* 2011;16:45-9.
7. Hu CY, Taymor ML, Hertig AT. Primary carcinoma of the fallopian tube. *Am J Obstet Gynecol* 1950;59:58-67
8. Balaya V, Metzger U, Lecuru F. Ultrasonographic features in the preoperative diagnosis of primitive fallopian tube carcinoma. *J Gynecol Obstet Biol Reprod (Paris)*. 2016;45:11-20.
9. Hefler LA, Rosen AC, Graf AH, Lahousen M, Klein M, Leodolter S, *et al.* The clinical value of serum concentrations of cancer antigen 125 in patients with primary fallopian tube carcinoma: a multicenter study. *Cancer* 2000;89:1555-60.
10. di Re E, Grosso G, Raspagliesi F, Baiocchi G. Fallopian tube cancer: incidence and role of lymphatic spread. *Gynecol Oncol* 1996;62:199-202.
11. Yu AJ, Fang SH, Gao YL. Analysis of therapeutic result and prognostic factor in primary fallopian tube carcinoma. *Zhonghua Zhong Liu Za Zhi* 2007;29:789-93.
12. Koo YJ, Kwon YS, Lim KT, Lee KH, Shim JU, Mok JE. Para-aortic lymphadenectomy for primary fallopian tube cancer. *Int J Gynaecol Obstet* 2011;112:18-20.
13. Ghezzi F, Cromi A, Uccella S, Bergamini V, Tomera S, Franchi M, *et al.* Laparoscopy versus laparotomy for the surgical management of apparent early-stage ovarian cancer. *Gynecol Oncol* 2007;105:409-13.

Funding: None; Conflict of Interest: None Stated.

How to cite this article: Duraisamy KY, Balasubramaniam D, Ravi K, Balasubramaniam A. Laparoscopic management of early stage primary fallopian tube carcinoma. *Indian J Case Reports*. 2019;5(2):148-150.

Doi: 10.32677/IJCR.2019.v05.i02.018