

## Surgical management of penile Mondor's disease: Case report and brief review of literature

Sumit Gahlawat<sup>1</sup>, Deepanshu Gupta<sup>2</sup>, Anuj Kumar<sup>2</sup>, Rajeev Sood<sup>3</sup>

From <sup>1</sup>Assistant Professor, <sup>2</sup>Senior Resident, <sup>3</sup>Professor and Head, Department of Urology and Renal Transplant, PGIMER & Dr. RML Hospital New Delhi, India

**Correspondence to:** Dr. Sumit Gahlawat, Department of Urology and Renal Transplant, PGIMER & Dr. RML Hospital, New Delhi-110001, India. E-mail: sumitgahlawat26@gmail.com

Received - 31 January 2019

Initial Review - 15 February 2019

Accepted - 20 March 2019

### ABSTRACT

Penile Mondor's disease (PMD) is a rare condition characterized by thrombosis of superficial dorsal vein of the penis. PMD is usually caused due to vigorous sex or repeated trauma to the penis leading to painful swelling of the penis. Most of the patients improve gradually on conservative treatment. Very rarely cord like lesion persists and causes painful erection and intercourse, meriting surgical management. Here, we report the case of a traumatic Thrombophlebitis of Superficial Dorsal Vein of Penis managed surgically along with a brief explanation of the surgical technique. Color Doppler was helpful in delineating the whole extent of thrombus in the vein. Excision of the whole length of the thrombosed vein was done. Abstinence from sex was advised for six weeks and the patient improved symptomatically.

**Keywords:** *Penile Mondor's disease, Surgery, Technique, Thrombophlebitis.*

**T**hrombophlebitis of superficial dorsal vein of the penis also known as Mondor's disease of the penis is a rare genital condition affecting young men. It usually presents as a painless or tender cord-like lesion involving the coronal sulcus in a circumferential manner, or rarely the prepuce and the distal part of the penile shaft.

Isolated thrombosis of the dorsal superficial vein of the penis was first reported and defined as Penile Mondor's disease (PMD) by Helm and Hodge in 1958 [1]. Very few cases on PMD are published in the world literature. Hakan Ozturk published in 2014 that only 53 cases of PMD are reported in the literature [2]. Most of the patients improve spontaneously or with medical management only and a very small fraction of the patient requires surgical management [3]. We present a case of traumatic superficial thrombophlebitis of the dorsal vein of the penis which was managed surgically along with a brief explanation of the surgical technique.

### CASE REPORT

A 24-year-old newly married healthy male presented to the urology outpatient department with a complaint of mild pain on the dorsolateral aspect (left side) of the penis during erection and intercourse since last three months. The patient gave a history of the overnight bus journey while sleeping in a prone position and the next morning after the journey, the patient developed penile swelling along with pain. The pain was severe in intensity, so the patient started taking oral analgesics and anti-inflammatory

agents over a week leaving behind a cord-like structure on the dorsolateral aspect of the penis.

On examination, the vitals were stable. Genitourinary examination revealed a palpable cord on the left dorsolateral aspect of the distal penis (Fig. 1). Mild tenderness of the penile shaft was noted mainly over the thrombosed vein. Testicular examination revealed no swelling or pain on palpation. A clinical differential diagnosis of penile Mondor's disease was made.

Routine laboratory investigations were normal. Color Doppler of the penis (Fig. 2) was done to ascertain the location and extent of the thrombus in the superficial dorsal vein of the penis which revealed the presence of two thrombi in the left side superficial dorsal vein of the penis. The larger thrombus was approximately 7 cm away from the external pudendal vein and measured 5 mm. The other thrombus measured 3 mm and was just distal to the larger one.

Resection of the thrombosed part of the superficial dorsal vein of the penis was planned as the patient did not improve on medical management over the last three months. The thrombosed vein was marked with a marker pen as it is important to ensure the complete excision of the thrombosed part of the vein and to avoid the persistence of symptoms which occurred while leaving behind the thrombosed part of the vein. Circumcoronal incision was given and the penis was degloved (above buck's fascia) to the base of the penis. Identification of the thrombosed vein the dartos layer of degloved penile skin was attempted but, the thrombosed vein was adherent to the penile skin and was difficult to locate and dissect away. To ensure the complete excision of

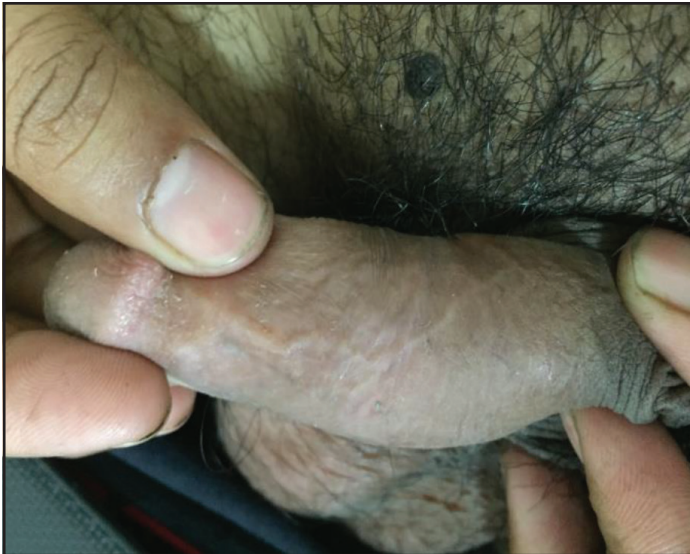

Figure 1: Thrombosed superficial dorsal vein of the penis

the thrombosed vein, a stab incision was made on the penile skin at the marked proximal limit of thrombus and ligation of the vein at the proximal end was done. The vein was lifted and separated from the dartos layer from the proximal to the distal end (Fig. 3). Gradually, the whole length of the thrombosed vein was excised. Degloved skin was sutured back. The patient was advised to abstain from sex for six weeks. Postoperative period was uneventful. Histopathological examination of the resected vein confirmed the clinical diagnosis. The patient improved symptomatically. Palpable cord-like structure vanished and there was no pain on erection. A follow-up of the patient after 6 months revealed no recurrence of symptoms.

## DISCUSSION

Penile superficial venous thrombosis is an uncommon and little known benign genital condition. One of the most

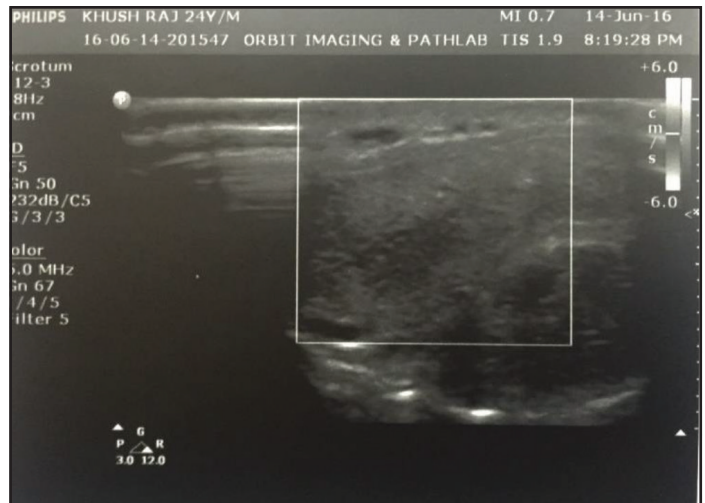


Figure 2: Doppler showing thrombosed superficial dorsal vein of the penis

common causes of PMD is vigorous sex and other causes are penile trauma, local (e.g. syphilis, candida infections) or distant infections, history of sexually transmitted diseases, thrombophilia, repair of inguinal hernia, orchiopexy, varicocele, use of intracavernous drugs, cancer in the pelvic region, metastatic pancreas cancer and migratory phlebitides due to paraneoplastic syndromes neoplasm [4,5]. This condition usually involves the dorsal vein of the penis but may also involve the superficial external pudendal [6].

A rare case of traumatic Thrombophlebitis of Superficial Dorsal Vein of Penis (TSDVP) was published by Bird V *et al* in 1997 as an occupational hazard in a cab driver following repeated injury to the penis by a coin-filled pouch [7]. In the present case the patient was newly married, so maybe vigorous sexual activity and overnight travel in a prone position suffering violent movements and jerks in the bus have exaggerated the condition causing the traumatic TSDVP.

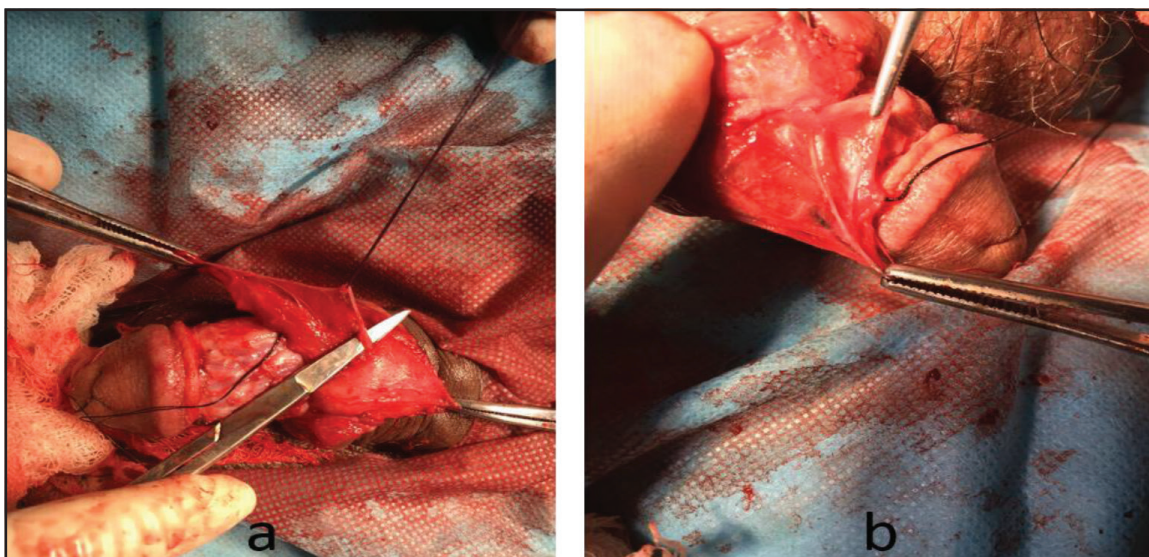


Figure 3 (a and b): Thrombosed vein dissected from the dartos layer of degloved penile skin

During an acute phase of the disease, Mondor's disease has to be differentiated from a penile fracture as it is also associated with penile trauma or vigorous sex followed by painful swelling of the penis. Sclerosing lymphangitis and Peyronies disease may also be considered as a differential diagnosis for patients with painful, fibrotic lesion of the penis as seen in the chronic phase of Mondor's disease.

PMD can be diagnosed easily from medical history and a physical examination. Patients consistently present with a rope-like cord on the dorsum of the penis. However, the diagnostic significance of ultrasound in penile Mondor's disease is paramount as it shows a non-compressible penile vein without flow and it can also diagnose rare skip thrombosis which can have an implication in the length of vein excised during surgery. In the present case also, the patient persistently felt tender cord-like structure on the dorsum of the penis and we detected skip thrombus with the help of penile doppler.

Most of the patients improve conservatively in 4-6 weeks. Only a very few require surgical treatment. Surgical treatment can be provided in the form of thrombectomy or resection of the thrombosed vein. In one of the largest case series of 25 patients on Mondor's disease of the penis reported by Al-Mwalad *et al* in 2006, they observed that improvement with conservative treatment was shown in 23 of 25 patients, with only two patients requiring surgical intervention, demonstrating that Mondor's disease of the penis is a relatively benign condition [8]. Similarly, Sasso F *et al* did dorsal vein resection in two out of ten patients and the rest of the patients were managed conservatively [9]. In 2015, Burak Ozkan *et al* reported in a case series of 30 patients that none of the patients required surgical treatment, all the thirty patients were managed conservatively and were asymptomatic with normal erectile function at the end of 2 months [10]. In the present case also, the patient was asymptomatic and having normal sexual life after six months of follow-up.

## CONCLUSION

Surgical management of PMD is seldom required. Excision of the complete thrombosed vein is important and leaving behind any thrombosed part of the vein may lead to recurrence or persistence of symptoms. Color Doppler is helpful in delineating the whole extent of thrombus in the vein.

## REFERENCES

1. Helm JD, Jr, Hodge IG. Thrombophlebitis of a dorsal vein of the penis: report of a case treated by phenylbutazone (Butazolidin) J Urol 1958;79:306-7.
2. Öztürk H. Penile Mondor's disease. Basic and Clinical Andrology 2014;24:5.
3. Hamilton J, Mossanen M, Strote J. Mondor's Disease of the penis. West J Emerg Med 2013;14:180. doi:10.5811/westjem.2012.8.13276.
4. Griger DT, Angelo TE, Grisier DB. Penile Mondor's disease in a 22-year-old man. Journal of the American Osteopathic Association 2001;101:235-7.
5. Zor M, Tahmaz L, Basal S, Irkilata HC, Dayanc M. Penile Mondor's disease in a 32-year-old man. Türkiye Klinikleri Journal of Medical Sciences 2009;29:1751-3.
6. Conkbayır I, Yanik B, Keyik B, Hekimoğlu B. Superficial dorsal penile vein thrombosis (Mondor disease of the penis) involving the superficial external pudendal vein. Journal of Ultrasound in Medicine 2010;29:1243-5.
7. Bird V, Krasnokutsky S, Zhou HS, Jarrahy R, Khan SA. Traumatic thrombophlebitis of the superficial dorsal vein of the penis: an occupational hazard. Am J Emerg Med 1997;15:67-9.
8. M. Al-Mwalad, H. Loertzer, A. Wicht, and P. Fornara, Subcutaneous penile vein thrombosis (Penile Mondor's Disease): pathogenesis, diagnosis, and therapy. Urology 2006;67:586-8.
9. Sasso F, Gulino G, Basar M, Carbone A, Torricelli P, Alcini E. Penile Mondors' disease: an underestimated pathology. Br J Urol 1996;77:729-32.
10. Ozkan B, Coskuner ER, Turk A, Akkus E, Yalcin V. Penile Mondor's disease and its effect on erectile function: results on 30 patients. Urology 2015;85:113-7.

*Funding: None; Conflict of Interest: None Stated.*

**How to cite this article:** Gahlawat S, Gupta D, Kumar A, Sood R. Surgical management of penile mondor's disease: Case report and brief review of literature. Indian J Case Reports. 2019;5(2):137-139.

Doi: 10.32677/IJCR.2019.v05.i02.014