

## An unusual case of vulval tuberculosis in pregnancy

Neena Gupta<sup>1</sup>, Uruj Jahan<sup>2</sup>, Fatima Usmani<sup>2</sup>, Shweta Rathore<sup>3</sup>

From <sup>1</sup>Professor, <sup>2</sup>Assistant Professor, <sup>3</sup>Junior Resident, Department of Obstetrics and Gynecology, Ganesh Shankar Vidarthi Memorial Medical College, Kanpur, Uttar Pradesh, India

**Correspondence to:** Dr. Uruj Jahan, Department of Obstetrics and Gynecology, Ganesh Shankar Vidarthi Memorial Medical College, Kanpur, Uttar Pradesh, India. E-mail: druruj@gmail.com

Received - 12 December 2018

Initial Review - 27 December 2018

Accepted - 21 February 2019

### ABSTRACT

Tuberculosis (TB) continued to be a major health problem throughout the world, especially affecting developing countries. India and China together account for 40% of the world's TB burden. Here, we present a rare case of genital TB in a 24-year-old pregnant woman (G2P1 + 0.34 weeks of pregnancy) with chronic vulval ulcer of 2 years. Histopathological examination was suggestive of TB, but acid-fast bacilli culture of biopsy specimen was found negative. The patient was started on anti-TB therapy. After 3 months, there was a remarkable improvement in her symptoms and >50% regression of the lesion.

**Key words:** *Pregnancy, Tuberculosis, Ulcer, Vulva*

Tuberculosis (TB) continued to be a major health problem throughout the world, especially affecting developing countries. India and China are together responsible for 40% of the world's TB burden [1,2]. Female genital TB (FGTB) is a common form of extrapulmonary TB (EPTB), accounting 27% of case of EPTB. The incidence of FGTB varies from 1% to 19% in various parts of India [3,4].

FGTB most frequently affect the upper genital tract, fallopian tube, and endometrium. Vulval TB is very rare, accounting for <1% of FGTB [5]. Due to the bizarre presentation, it is a challenge to the clinician for diagnosis and proper management. No age is immune from this disease, but peak age frequency ranges between 21 and 31 years [6]. Here, we present a rare case of genital TB in a pregnant woman with chronic vulval ulcer of 2 years.

### CASE REPORT

A 24-year-old female patient from a rural background presented in the outpatient department (OPD) with a diagnosis of G2P1 + 0.34 weeks of pregnancy with an ulcer on vulva for 2 years. She had no antenatal complaints apart from the ulcer. She received several courses of antibiotics, antifungals, and steroids both topical and systemic, but the ulcer remained. There was no history suggestive of TB in the past and in the family. The previous delivery was uneventful, full-term normal vaginal delivery 3 years back.

General examination and vitals were unremarkable. The patient was thin built and normotensive. The ulcer was painful, gradually increasing in size, and associated with itching and discharge. Fundal height is suggestive of 32 weeks of pregnancy in cephalic presentation with a relaxed uterus and regular cardiac activity. On local examination, a single, depigmented, hypertrophic ulcer

(6 cm × 5 cm) was present on the right labia majora and mons extending to the left labia majora with undermined edges, indurated margin, and serous discharge (Fig. 1). There was 1 cm × 1 cm palpable right inguinal lymph node. Node was firm, mobile, and non-tender. The internal examination was unremarkable. Genital examination of her husband was found normal, no evidence of tubercular epididymitis.

Her routine investigations were normal. Human immunodeficiency virus and venereal disease and research laboratory testing of the couple were non-reactive. Mantoux test showed a reaction with 13 mm induration. Ultrasound was suggestive of 32 weeks of pregnancy with no other abnormality. Sputum for acid-fast bacilli (AFB) was negative. In these circumstances, a biopsy of the ulcer edge was planned. Histopathological examination revealed subepidermal epithelioid granuloma with Langhans giant cells, suggestive of TB (Fig. 2), but AFB culture of biopsy specimen was found negative.

Meanwhile, the patient delivered by lower segment cesarean section at 37 weeks, with an indication of fetal distress. Chest X-ray done postnatally was unremarkable. Anti-TB therapy (ATT) 2RHZE/4RHE was started on the basis of histopathology after delivery. ATT drugs included rifampicin (R), isoniazid (H), pyrazinamide (Z), and ethambutol (E). The intensive phase of ATT for 2 months was started including drugs rifampicin, isoniazid, pyrazinamide, and ethambutol daily. The patient was on continuous treatment at nearby directly observed treatment short course center. The patient came to OPD after 3 months with remarkable improvement in her symptoms and >50% lesion regression (Fig. 3). However, the patient did not come for further follow-up as she belongs to the remote rural area.

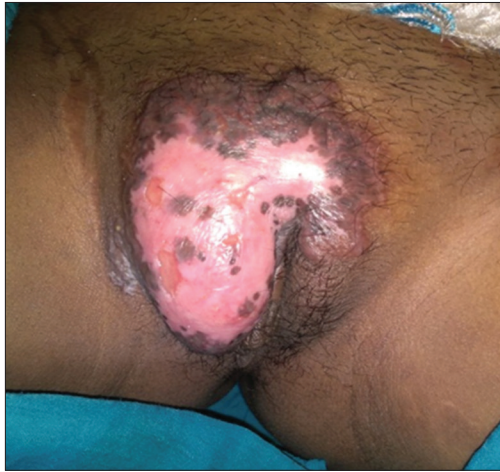

Figure 1: Vulval ulcer before treatment

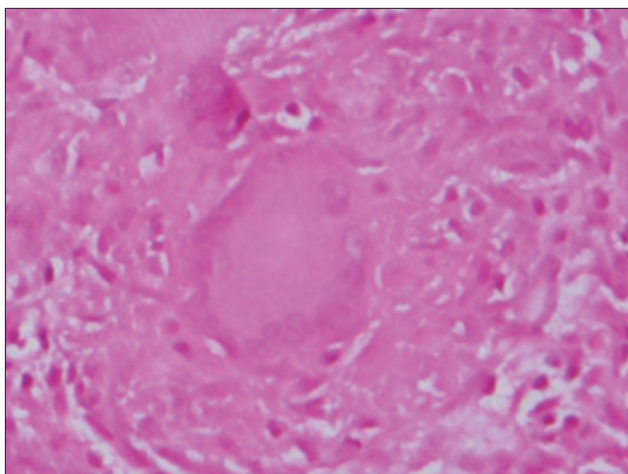


Figure 2: Histopathological report of vulval ulcer showing epithelioid granuloma

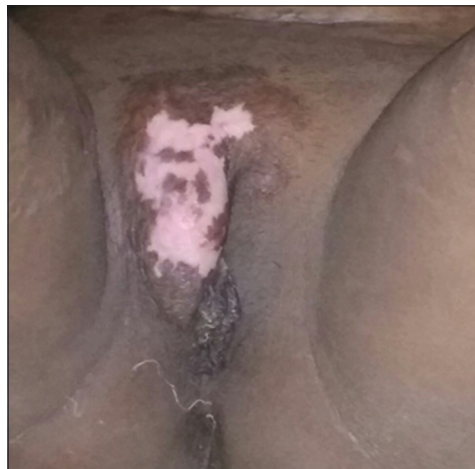

Figure 3: Vulval ulcer after 3 months of treatment antituberculosis therapy

## DISCUSSION

FGTB is secondary to other organ involvement sites of body [7]. Vulval TB was first described in 1881. Hematogenous is the most common mode of spread from an active site of infection to

female genital tract. It may also spread by direct extension from the lesion in the genital tract and exogenously from sputum used as a lubricant during intercourse or sexual contact with a person harboring epididymal TB lesions or renal TB [8].

Tubercular lesion is usually ulcerative, but it may present as hypertrophy, multiple sinus tracts, lymphedema, or rarely as elephantiasis [8-10]. Suppuration and ulceration may occur of the inguinal lymph nodes. It can be underdiagnosed as chronic infection and sexually transmitted diseases or overdiagnosed as malignancy. The diagnosis usually confirmed by biopsy. AFB staining is not very useful in diagnosis and mostly biopsy specimens are culture negative. The gold standard for diagnosis is the isolation of *Mycobacterium bacillus* which is merely found in FGTB [8]. Most authors agree that histopathological examination and presence of atypical granuloma may be sufficient for diagnosis and response to ATT further confirms the diagnosis as in our case [8,10]. The optimal duration of the treatment of vulval TB is not known. Most will follow the treatment duration of non-pulmonary TB, that is, 6–9 months [11].

## CONCLUSION

TB should be kept in mind whenever a young patient even in pregnancy presents with chronic ulcerative lesion of vulva fails to respond to empirical treatment and should proceed for biopsy.

## REFERENCES

1. Dye C, Watt CJ, Bleed DM, Hosseini SM, Raviglione MC. Evolution of tuberculosis control and prospects for reducing tuberculosis incidence, prevalence and deaths globally. *JAMA* 2005;293:2790-3.
2. World Health Organisation. Global Tuberculosis Control: A Short Update to the 2009 Report. WHO/HTM/TB 2009,426. Geneva: World Health Organisation; 2009.
3. Jindal UN. An algorithmic approach to female genital tuberculosis causing infertility. *Int J Tuberc Lung Dis* 2006;10:1045-50.
4. Gupta N, Sharma JB, Mittal S, Singh N, Misra R, Kukreja M, *et al.* Genital tuberculosis in Indian infertility patients. *Int J Gynecol Obstet* 2007;97:135-8.
5. Mondal SK. Histopathologic analysis of female genital tuberculosis: A fifteen years retrospective study of 110 cases in Eastern India. *Turk Patoloji Derg* 2013;29:41-5.
6. Nwachokor FN, Thomas JO. Tuberculosis in Ibadan, Nigeria a 30 year review. *Cent Afr J Med* 2000;46:287-92.
7. Mondal SK, Dutta TK. A ten year clinicopathological study of female genital tuberculosis and impact on fertility. *JNMA J Nepal Med Assoc* 2009;48:52.
8. Agarwal J, Gupta JK. Female genital tuberculosis a retrospective clinic-pathological study of 501 cases. *Int J Pathol Microbiol* 1993;36:389-97.
9. Chatterjee G, Kundu A, Das S. Vulval tuberculosis. *Ind J Dermatol* 1999;44:193-4.
10. Guruvare S, Kushtagi P. Genital tuberculosis manifesting as sinus tract. *Int J Gynaecol Obstet* 2007;7:89-91.
11. Lam SK, Chan KS, Chin R: A rare case of vulval tuberculosis. *Hong Kong J Gynaecol Obstet Midwifery* 2007;7:56.

Funding: None; Conflict of Interest: None Stated.

**How to cite this article:** Gupta N, Jahan U, Usmani F, Rathore S. An unusual case of vulval tuberculosis in pregnancy. *Indian J Case Reports*. 2019;5(1):82-83.

Doi: 10.32677/IJCR.2019.v05.i01.028