

Snakebite presenting as acute coronary syndrome: An interesting diagnosis and management

Abhimanyu Patial¹, Purnima Patial¹, Aradhna Sharma², Tarun Sharma³, Dhiraj Kapoor⁴

From ¹Junior Resident, ²Assistant Professor, ⁴Professor and Head, Department of Medicine, ³Assistant Professor, Department of Pharmacology, Dr. Rajendra Prasad Government Medical College Kangra, Sadarpur, Himachal Pradesh, India

Correspondence to: Dr. Tarun Sharma, Department of Pharmacology, Dr. Rajendra Prasad Government Medical College, Tanda Kangra, Sadarpur, Himachal Pradesh, India. E-mail: tarunpgi@gmail.com

Received - 24 November 2018

Initial Review - 10 December 2018

Accepted - 14 February 2019

ABSTRACT

Snakebite is a common presentation in India, especially in the Sub-Himalayan region. The most common presentation of snakebite is neurotoxic and hematologic complications. Acute coronary syndrome after a snakebite is rare. This case report explicitly explains a patient presenting as acute coronary syndrome after a snakebite with dynamic electrocardiogram changes. Later on, the anti-snake venom therapy was given to the patient and her condition improved. It should be kept in mind that, since the pathology of snakebite-induced myocardial infarction is different, its management will also be different.

Key words: *Acute coronary syndrome, Hematotoxic, Thrombolysis, Viper*

Snakebite is one of the most common causes of reptile bite in India, especially in the Sub-Himalayan region [1]. Local and systemic complications of snakebites such as neurotoxicity and hematotoxicity are well known. There are very few case reports depicting acute myocardial infarction (MI) that too presents with complete left bundle branch block (LBBB) pattern.

Here, we present a case report describing the acute coronary syndrome in a patient of viper bite with no underlying risk factors for heart disease.

CASE REPORT

A 42-year-old female was working in fields when she complained of a bite by a snake on the left foot. Patient was taken to primary care facility and was given first aid in form of tourniquet proximal to site of bite and oral antibiotics with analgesics and tetanus injection. Patient was referred to higher center.

On presentation to our department, the patient was conscious, well-oriented to time, place, person, and looked apprehensive. The patient was complaining of pain at the bite site and hematuria. The patient was not a known hypertensive, diabetic, smoker and there was no history of premature coronary artery disease in the family. Nor the patient had underlying ischemic heart disease.

On general examination, the patient had a blood pressure of 100/64 mmHg, a pulse rate of 103/min, respiratory rate of 20/min, and room air saturation of 94%. The patient complained of suffocation and mild chest discomfort, so she was admitted in the intensive care unit and 100U adaptive support ventilation (ASV) was given diluted in saline.

Electrocardiogram (ECG) done at presentation was normal (Fig. 1). In the next 3 h, patient's condition deteriorated and complained of increased shortness of breath on lying down and heaviness in the chest. On examination, her blood pressure fell to 84/56 mmHg, and on auscultation, bilateral lower lobe fine inspiratory crept appeared. ECG showed new onset LBBB pattern (Fig. 2a). Inotropes were started and the patient was given ASV 100 U over next 4 h along with oxygen at 3 L/minute. Troponin I test was done which was strongly positive (32,000). A possibility of the acute coronary syndrome was made, but in view of hematuria, antiplatelet and heparin were not started.

Chest discomfort improved and blood pressure also increased to 92/60 mmHg. Repeat ECG (Fig. 2b) showed the disappearance of LBBB and ST-T depressions appeared over anterior leads v2–v6. Repeat troponin after 6 h was 30,000. A dose of 100 U of ASV was given over the next 4 h. Total ASV given was 300 U. ECG repeated after 6 h was normal (Fig. 3). Two-dimensional echocardiogram was done which showed no regional wall motion abnormality and ejection fraction was 56%. Angiography was planned, but the patient did not give consent. The patient was discharged in a hemodynamically stable pain-free condition. At present, she is on regular follow-up.

DISCUSSION

Viper bites are very common in India. They mainly cause neurotoxicity and hematotoxicity. The main etiology considered behind MI or ECG changes is thought to be toxin-induced coronary vasospasm [1]. Snake venom can cause direct coronary spasm and ECG changes along with pain

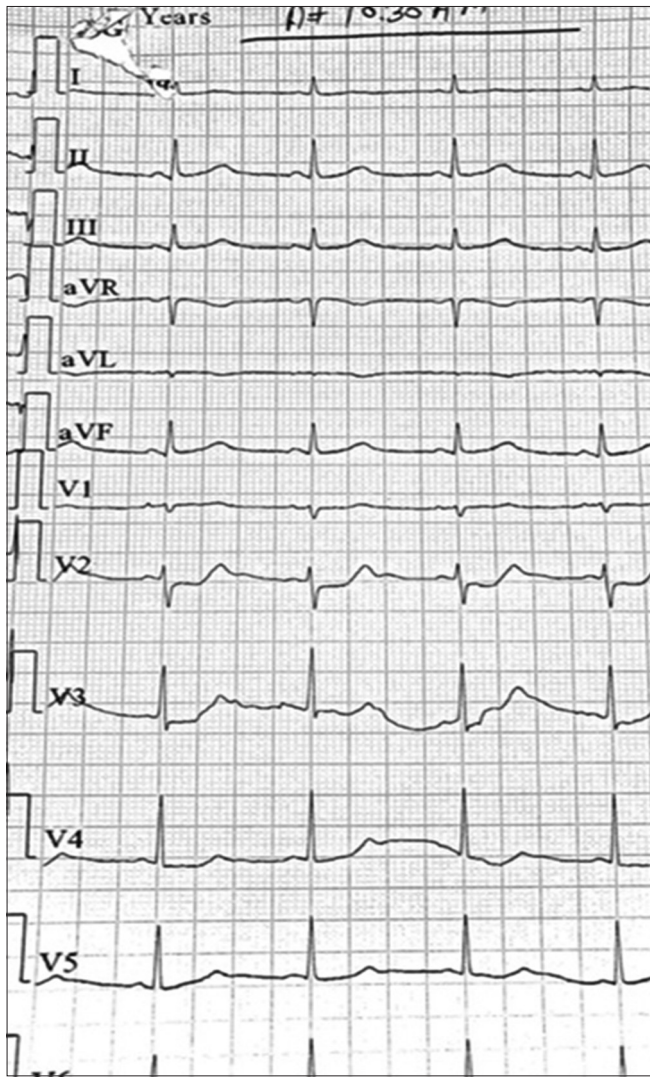


Figure 1: Electrocardiogram before treatment

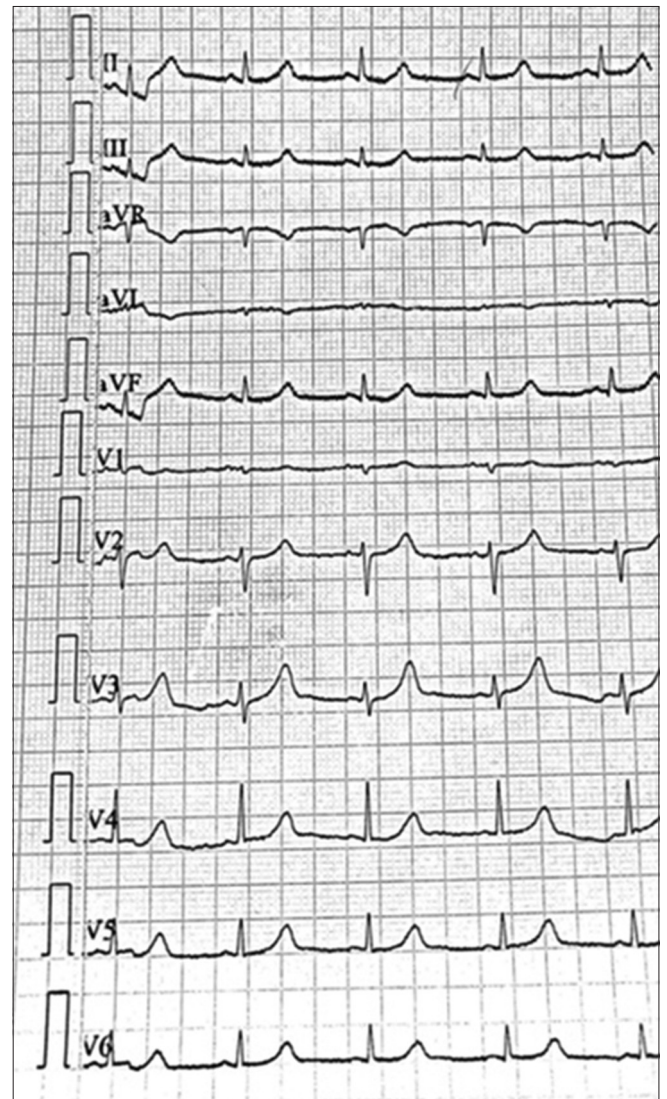


Figure 3: Repeat electrocardiogram after 6 h

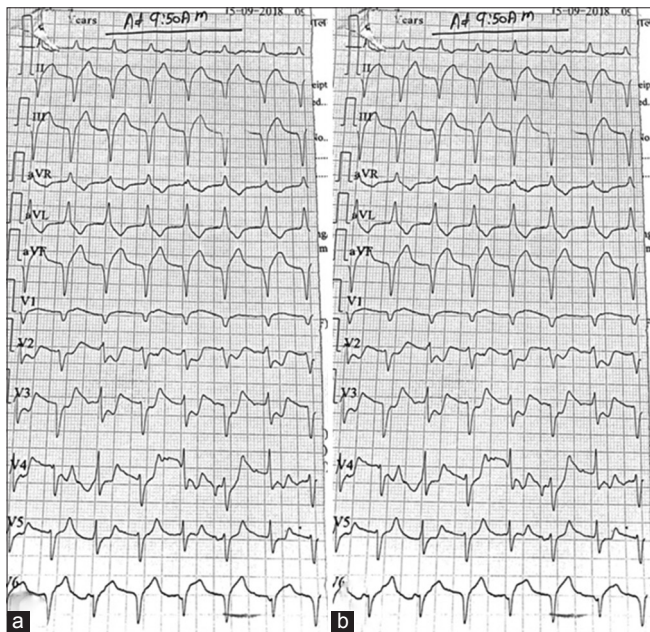


Figure 2: (a) Electrocardiogram (ECG) with left bundle branch block pattern; (b) ECG with ST-T depression

and symptoms as in our case. Other theories proposed are myocarditis and myocardial necrosis. Thrombosis could be due to hypercoagulability, hemoconcentration, and hyperviscosity after snakebite. Snakebite secretes toxin hemorrhagings which cause increased vascular permeability, endothelins or sarafotoxins, or anxiety [2]. Procoagulants such as arginine esterase coagulase cause hypercoagulability [3], which can cause disseminated intravascular coagulation further leading to thrombosis. The direct effect of snake venom on cardiac muscle can cause myocarditis [4]. Hypovolemic shock due to bleeding (bleeding due to hemorrhagins) or toxic vasculitis is also one of the causes [5].

The best therapy in these type of cases is not thrombolysis and antiplatelet or anticoagulants but anti-snake venom because all the effects like ischemia and STEMI are because of snake-venom induced coronary vasospasm [5] and not because of atherosclerosis. Hence, the role of statins, antiplatelet agents, and anticoagulants is not proven because it will increase the chance of life-threatening bleeds which

will further cause hemoconcentration. In the literature, some case reports have mentioned thrombolysis in such cases, but there are no guidelines that these should be thrombolysed [6]. Even after thrombolysis and angiography, there was no lesion and TIMI 3 flow was there suggesting only vasospasm in these cases.

This case report is very important for primary care physicians and doctors working in emergency room since the mechanisms and management of MI with snakebite are different and it is one of the conditions in cardiology in which, in spite of new-onset ECG changes (LBBB in our case), thrombolysis is not indicated and can even be counterproductive.

CONCLUSION

This case report explicitly explains snakebite-induced acute coronary syndrome and the management. Antiplatelet agents and thrombolytics are not to be used in the management. Mechanism of cardiac injury is different. Hence, treatment is mainly ASV and supportive.

REFERENCES

1. Maheshwari M, Mittal SR. Acute myocardial infarction complicating snake bite. *J Assoc Physicians India* 2004;52:63-4.
2. Wöllberg Z, Bdolah A, Kochva E. Calcium channel modulators in heart and smooth muscle. In: Abrahams S, Amitai G, editors. *Cardiovascular effects of Mammalian Endothelins and Snake Venom Sarafotoxins*. Deerfield Beach, FL: Vancouver Coastal Health; 1990. p. 283-99.
3. Niraj M, Jayaweera JL, Kumara IW, Tissera NW. Acute myocardial infarction following a Russell's viper bite: A case report. *Int Arch Med* 2013;6:7.
4. Blondheim DS, Plich M, Borman M, Khair G, Tzvig L, Ezri J, *et al.* Acute myocardial infarction complicating viper bite. *Am J Cardio* 1996;78:492-3.
5. Tony JC, Bhat R. Acute myocardial infarction following snakebite. *Trop Doct* 1995;25:137.
6. Chakrabarti S, Biswas P, Patil S. Acute myocardial infarction following viper bite: A rare case scenario. *Heart India* 2015;3:18-20.

Funding: None; Conflict of Interest: None Stated.

How to cite this article: Patial A, Patial P, Sharma A, Sharma T, Kapoor D. Snakebite presenting as acute coronary syndrome: An interesting diagnosis and management. *Indian J Case Reports*. 2019;5(1):70-72.

Doi: 10.32677/IJCR.2019.v05.i01.024