

Primary malignant melanoma of breast: A unique case report

Rajas B Patel¹, Boman N Dhabhar², Arun Behl³

From ¹Senior Resident, ²Consultant, ³Consultant, Department of Oncology, Fortis Hospital, Mulund, Mumbai, India

Correspondence to: Dr. Rajas B Patel, Department of Oncology, FORTIS Hospital, Mulund Goregaon Link Rd, Industrial Area, Mulund West, Mumbai, Maharashtra – 400 078. E-mail: rajas.patel@gmail.com

Received – 29 October 2018

Initial Review – 14 November 2018

Accepted – 05 February 2019

ABSTRACT

Malignant melanoma is a clinical entity that occurs commonly in the skin, mucous membrane, and choroid; its occurrence in breast tissue is extremely rare. Evidence suggests that most malignant melanoma cases present as a metastatic manifestation of primary cutaneous melanoma. It is rare to find primary malignant melanoma of breast tissue. There is a dearth of data on this topic in the academic literature; moreover, there are no standard guidelines or consensus statements available on the management of primary malignant melanoma of the breast. Therefore, we, herein, report one such rare case of malignant melanoma with breast as its primary site.

Key words: *Pleomorphism, Immunohistochemistry, Adjuvant therapy, Radical mastectomy*

Malignant melanoma usually presents as a primary cutaneous malignancy [1,2]. It is a malignant skin tumor derived from the melanocytes. It is highly malignant due to its rapid growth and early metastasis. Approximately 160,000 new cases of malignant melanoma are diagnosed annually worldwide [3]. Apart from the skin, it also arises in other organs and tissues including the oral cavity, paranasal sinuses, esophagus, larynx, vagina, and anorectal region [4]. Approximately 5% of all malignant melanomas originate from primarily non-cutaneous sites [5].

Malignant melanoma of the breast tissue has diversified manifestations and can present as primary cutaneous melanoma, primary glandular melanoma, metastatic melanoma, and in-transit metastases to the breast [6]. Primary malignant melanoma of the breast (PMMB) is a very rare clinical condition accounting for 3%–5% of all melanomas and for <0.5% of malignant breast carcinomas. The PMMB may arise from the cutaneous aspect of the breast or from breast parenchyma. <200 cases of PMMB are reported till date, based on literature search [7]. Here, we report one such rare case of malignant melanoma with breast as its primary site in a 43-year-old female.

CASE REPORT

A 43-year-old female patient presented with a hard, non-tender lump in her left breast for 6 months, along with redness with no discharge from the nipple. Her medical history was not significant, and her family history was non-contributory. On examination, the patient was vitally stable, pulse 88, blood pressure of 120/70 mmHg, and respiratory rate 16. Local examination of the breast revealed a hard lump in her left breast with inflamed but intact skin and normal nipple and areola (Fig. 1).

On investigation, the breast ultrasound showed a solid, heterogeneous mass (lesion) measuring 7 cm × 4 cm in the upper outer quadrant at 2–3 O'clock position in the left breast with minimal central vascularity, nipple, and both the axillae and the right breast appeared normal.

Fine-needle aspiration cytology of the lump showed the presence of scattered and poorly differentiated malignant cells, suggestive of malignant melanoma; hence, core biopsy of the lump was advised. Histopathology of the core biopsy report was suggestive of malignant melanoma.

A positron emission tomography-computed tomography (PET-CT) was performed to determine baseline staging of the primary malignant melanoma of the left breast (PMMB). The scan showed local disease in the left breast with no

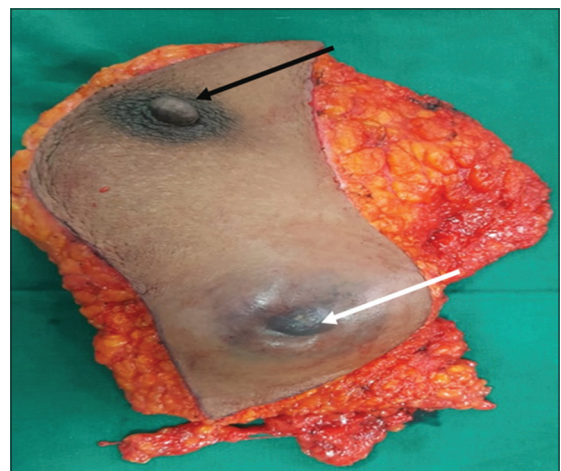


Figure 1: Surgical specimen of the breast melanoma (black arrow showing the nipple and white arrow showing the protruding melanoma)

nodal or distant metastases. The patient underwent modified radical mastectomy with axillary node dissection after a multidisciplinary opinion. The surgical histopathological report stated that a well-circumscribed malignant melanoma of size 10 cm × 10 cm × 7 cm was present, which did not involve the base, skin, or nipple. Tumor cells were oval, polyhedral, and fusiform with marked nuclear anaplasia and multiple bizarre tumor giant cells. 1/22 lymph nodes showed metastatic malignant melanoma without perinodal infiltration. Immunohistochemistry report revealed a vimentin-, melanosome-HMB-45-, MART-1 MELAN-A-, and SOX-10-positive malignant melanoma that

was focally positive for cytokeratin, European Medicines Agency, and S-100 (Fig. 2).

The disease was staged as per the staging guidelines for melanoma of the American Joint Committee on Cancer as pT_{4a}, pN_{1a}, and M₀, i.e., Stage IIIC [8]. B-RAF V600 mutation studies were negative. Adjuvant therapy options with nivolumab versus ipilimumab were discussed with the patient. However, the patient was not willing for any other treatment due to financial constraints. On the 4 months of follow-up visit, the patient presented with local and contralateral axillary nodal radiological recurrence, pancreatic, and lower pole of kidney metastases, as shown on the follow-up PET-CT.

DISCUSSION

The key diagnostic aids in the assessment of PMMB include pathological morphology, immunohistochemistry, and electron microscopy. The important diagnostic features of PMMB include pleomorphism of tumor cells and nuclear atypia; scattered intracellular pigment granules; positive expression of the proteins S-100, HMB-45, and melan-A on immunochemistry; electron microscopy findings of melanosome and former melanosome; changes in the edge of the tumor tissue and normal breast tissue; and exclusion of tumor metastases and tumor invasion from neighboring sites [6].

The treatment of PMMB requires special attention in view of the rarity of the disease and the complex anatomy of the breast. Evidence from the available case reports suggests that radical surgical resection with free margins combined with axillary node resection or axillary sentinel node resection constitutes the primary treatment of choice in PMMB patients. Mastectomy and

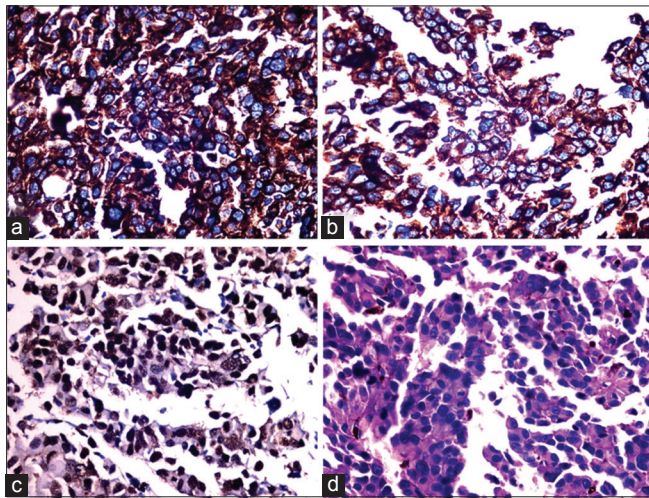


Figure 2: Image of immunohistochemical (IHC) staining showing (a and b) Melan-A-positive malignant melanoma tumor cells; (c) SOX-10-positive malignant melanoma tumor cells; (d) IHC staining of malignant melanoma tumor cells

Table 1: Examination findings and treatment of PMMB case reports

Previous case reports	Examination findings	Treatment
A 56-year-old woman presented with mass in the left breast that was detected 4 months back. The patient also had complaints of shoulder pain [5]	5 cm×5 cm, firm, well-defined, and tender mass in the upper outer quadrant of the left breast that was not attached to the skin. A large lymph node was palpable in the left axilla	Mastectomy and axillary lymph node dissection and systemic chemotherapy
A 26-year-old woman presented with painless mass in the left breast for 3 months [6]	3 cm×2 cm firm irregular mass in the upper inner quadrant of the left breast. There was no change in the appearance of the local skin, no discharge from, or retraction of, the nipple. A small number of lymph nodes were palpated in the left axilla	The patient refused surgery and further treatment and succumbed after 2 months due to widespread metastasis
A 54-year-old woman presented with large palpable mass in the left breast [7]	Ultrasonography of the left breast revealed a homogenous, diffuse echogenic lesion in the outer upper quadrant with sharp borders and 10 cm in the largest diameter	The patient was treated with mastectomy, axillary sentinel lymph node excision after peritumoral injection of 5 ml of 99 m technetium-marked albumin and primary reconstruction
A 59-year-old woman presented with a black pigmented skin lesion in the right breast. She revealed that the lesion had appeared at birth but grew rapidly and bled recently [9]	The lesion was 2.0 cm×1.5 cm in size and located on the periareolar skin in the upper inner quadrant of the right breast which is not associated with any breast mass. The axillary lymph node was not palpated and there was no nipple discharge or retraction	The patient underwent wide local excision of the lesion, including removal of normal appearing skin and underlying subcutaneous tissue to provide a safety margin
A 46-year-old female patient presented with complaints of breast mass in the right breast. She had no other complaints [12]	Well-circumscribed nodule measuring 2 cm in diameter in the upper outer quadrant of the right breast and a palpable 1.5-cm lymph node in the right axilla was noted	Excision of breast lesion and axillary lymph node was performed

PMMB: Primary malignant melanoma of the breast

regional dissection of the internal mammary chain are not of significance in the management of PMMB [9].

Adjuvant treatment strategies for PMMB usually adhere to treatment approach suggested by the standard melanoma guidelines. According to the melanoma guidelines, interferon alpha is considered as the standard of care in high-risk patients such as those with regional lymph node metastasis, deep infiltration, and ulceration. Although adjuvant radiotherapy improves lymph node field control in patients at high risk of relapse, there is not much improvement in overall survival. Therefore, the use of radiotherapy following lymphadenectomy in the treatment of patients at increased risk of developing lymph node and distant recurrence remains debatable [7-10].

Management strategies for primary advanced and recurrent PMMB also follow the standard melanoma guidelines and include treatment with immunotherapies such as ipilimumab, vemurafenib, and systemic chemotherapy with dacarbazine, temozolomide, cisplatin, and paclitaxel. Therapeutic equipotency in the case of cutaneous PMMB may still be considered; however, for cases of PMMB arising from the glandular parenchyma of the breast, the management remains a big challenge [11-14].

There are very few clinical case reports involving primary cutaneous malignant melanoma of the breast. Findings and treatment of few case reports similar to the current case study are shown in Table 1. In the present study, the first symptom that was noted by the patient was a painless lump in the left breast. Based on clinical examination, histopathological features, and results from immunohistochemical staining, the patient was diagnosed with PMMB. She was treated with surgical approach; however, adjuvant therapy was not administered, as she was not willing for the same.

CONCLUSION

PMMB is a particularly rare type of malignancy with poor prognosis. Early diagnosis, correct surgical resection, and comprehensive adjuvant therapy are crucial to achieve a better clinical outcome in these patients.

REFERENCES

1. Allen AC, Splitz S. Malignant melanoma a clinicopathological analysis of the criteria for diagnosis and prognosis. *Cancer* 1953;6:1-45.
2. Peng J, Han F, Yang T, Sun J, Guan W, Guo X. Primary malignant melanoma of the lung. *Medicine* 2017;96:1-4.
3. Parkin DM, Bray F, Ferlay J, Pisani P. Global cancer statistics, 2002. *CA Cancer J Clin* 2002;55:74-108.
4. Yamamoto Y, Kodama K, Maniwa T, Takeda M, Tanaka Y, Ozawa K, *et al.* Primary malignant melanoma of the lung: A case report. *Mol Clin Oncol* 2017;7:39-41.
5. Kim SY, Baek MD, Lee MS, Cho MS, Song OP. A case of malignant melanoma presenting as a breast mass. *J Korean Breast Cancer Soc* 2003;6:35-8.
6. He Y, Mou J, Luo D, Gao B, Wen Y. Primary malignant melanoma of the breast: A case report and review of the literature. *Oncol Lett* 2014;8:238-40.
7. Drueppel D, Schultheis B, Solass W, Ergonenc H, Tempfer CB. Primary malignant melanoma of the breast: Case report and review of the literature. *Anticancer Res* 2015;35:1709-13.
8. Edge SB, Compton CC. The American joint committee on cancer: The 7th edition of the AJCC cancer staging manual and the future of TNM. *Ann Surg Oncol* 2010;17:1471-4.
9. Kim SK, Kim YW, Youn HJ, Park HS, Jung SH. Primary cutaneous malignant melanoma of the breast. *J Korean Surg Soc* 2012;83:388-92.
10. Edge SB, Byrd DR, Compton CC, Fritz AG, Greene FL, Trotti A. *AJCC Cancer Staging Manual*. 7th ed. New York: Springer; 2010.
11. Kurul S, Taş F, Büyükbabani N, Mudun A, Baykal C, Çamlıca H. Different manifestations of malignant melanoma in the breast: A report of 12 cases and a review of the literature. *Jpn J Clin Oncol* 2005;35:202-6.
12. Pressman PI. Malignant melanoma and the breast. *Cancer* 1973;31:784-8.
13. Somanathan T, Mathews A, Kattoor J, Vasudevan J. Malignant melanoma of breast: A unique case with diagnostic dilemmas'. *Indian J Pathol Microbiol* 2014;57:287.
14. Nagata Y, Yoshioka M, Uramoto H, Tsurudome Y, Yamada S, Hanagiri T, *et al.* Malignant melanoma of the nipple: A case report. *J Breast Cancer* 2018;21:96-101.

Funding: None; Conflict of Interest: None Stated.

How to cite this article: Patel RB, Dhabhar BN, Behl A. Primary malignant melanoma of breast: A unique case report. *Indian J Case Reports*. 2019;5(1):64-66.

Doi: 10.32677/IJCR.2019.v05.i01.022