

## Acute pancreatitis associated with dengue fever: An interesting and rare complication of dengue virus

Arvind Mishra<sup>1</sup>, Rohin Saini<sup>2</sup>, Monika Kallani<sup>2</sup>

From <sup>1</sup>Professor, <sup>2</sup>Resident, Department of Medicine, King George Medical University Lucknow, Uttar Pradesh, India

Correspondence to: Dr. Arvind Mishra, H. No - A-1/94, Viram Khand 1, Gomti Nagar, Lucknow – 226010, Uttar Pradesh, India.

E-mail: anuarvindmisra@gmail.com

Received - 16 November 2018

Initial Review - 01 December 2018

Accepted - 08 January 2019

### ABSTRACT

In humans, infections with dengue viruses range from mild fever with thrombocytopenia to life-threatening forms like vasodilatory shock with hemorrhagic manifestations. Of the many complications known of dengue fever, pancreatitis is a rarely discussed event. We would like to present a rare and unusual complication of this common disease. A 17 year old female with past history of tuberculosis was admitted with complains of pain abdomen and fever along with thrombocytopenia. Besides features of dengue fever, the presence of typical abdominal pain, high serum amylase, ultrasound, and computerized tomography scan features suggested the diagnosis of an acute pancreatitis. This complication developed in the initial phase of the illness. The patient had mild-to-moderate pancreatitis that recovered uneventfully with conservative treatment. The awareness of this complication in dengue fever is necessary for timely management of patients which will aid in reducing mortality.

**Key words:** *Acute pancreatitis, Dengue fever, Inflammation, Rash*

Acute pancreatitis is defined as the inflammation of the pancreas. It has multiple known etiologies such as gallstone disease, autoimmune, and ethanol. Rarely, infective etiologies such as viruses and bacteria have also been responsible for infective pancreatitis. Infective pancreatitis is caused due to various bacteria (mycoplasma, legionella, and leptospira), parasites (toxoplasma cryptosporidium and Ascaris), and virus (Coxsackie B4, measles, mumps, Epstein Barr, rubella, and hepatitis B) [1]. Clues to the infectious nature of pancreatitis lie in the characteristic signs and symptoms of the disease produced by organism and features of inflammation of pancreas occurring concurrently [2].

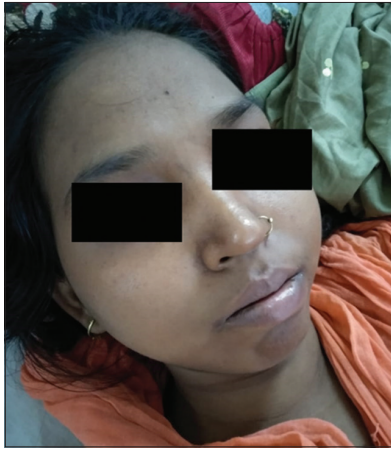Dengue is a mosquito-borne arthropod illness prevalent in tropical countries transmitted primarily by *Aedes mosquito*. Its manifestations vary from mild fever with malaise to hemorrhagic shock and death [3]. Various atypical complications of dengue fever such as Guillain-Barre Syndrome, viral encephalitis, and myocarditis have been documented [4]. Out of the abdominal complaints associated with the dengue illness, gastritis, enteritis, and acute liver failure have been reported, but the involvement of pancreas has been a rarely informed abdominal complaint. We would like to report the occurrence of acute pancreatitis in a 17-year-old adult who presented with fever with thrombocytopenia and petechiae rash along with diffuse, dull-aching, and epigastric pain abdomen radiating to the back.

### CASE REPORT

A 17-year-old female was admitted to the hospital with complaints of malaise and headache, followed by high-grade, continuous fever with chills and rigors, myalgia, and headache since 5 days. She also complains of acute onset, severe, continuous, and dull-aching epigastric pain radiating to the back region since 3 days. The patient also gave a history of the passage of black-tarry stools since past 3 days along with five episodes of non-bilious vomiting containing food particles since past 1 day. There was no history of jaundice, drug intake, and alcohol intake in the past.

On examination, the patient was conscious, oriented to time, place and person and had a blood pressure of 90/60 mm-Hg, respiratory rate of 22/min, and pulse rate of 110/min. Significant pallor was present along with a diffuse petechial rash on lower extremities and maculopapular rash over the face (Fig. 1). Abdominal examination revealed a distended abdomen with tenderness, guarding in the epigastrium with no rebound tenderness and bluish discoloration around the umbilicus. There was no palpable mass, organomegaly or free fluid present. Bowel sounds were absent. Other systems were within normal limits.

A provisional diagnosis of acute febrile illness with thrombocytopenia with pancreatitis was made, and the patient was further evaluated. The blood investigations of the patient were given in Table 1. Electrocardiogram showed sinus tachycardia. Contrast-enhanced computerized tomography (CECT) abdomen showed that pancreas bulky and heterogeneous post-contrast



**Figure 1:** Diffuse macular reddish rash present over the face of the patient

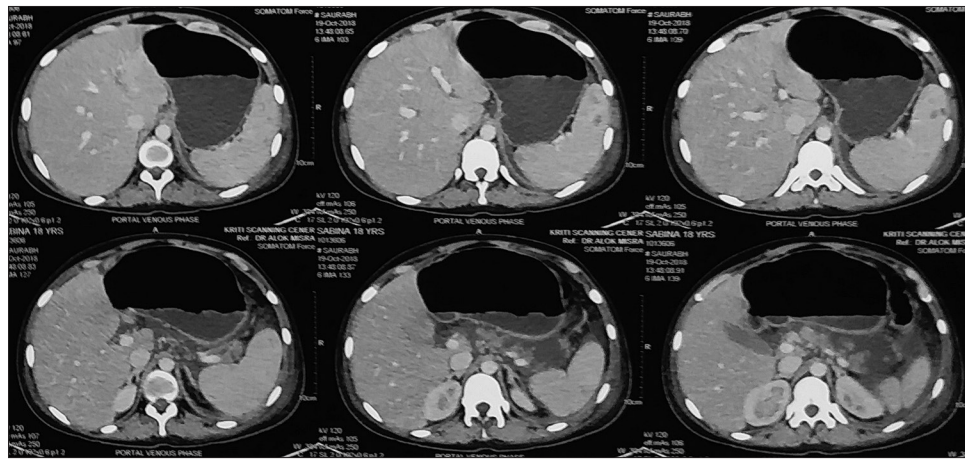
enhancement margins were ill-defined with multiple non-enhancing hypodense areas suggestive of necrosis which were seen in the body and tail region (>30% necrosis). Extensive stranding of the peripancreatic, mesentery, omental, and perigastric fat planes is noted with edematous bowel loops and was suggestive of acute necrotizing pancreatitis with CT severity index of 10/10 (Fig. 2).

The patient was admitted in view of her complaints and was conservatively managed with IV fluids and antibiotics. Serial platelet count/monitoring was done. She was kept nil peroral for 4 days and was subsequently started on a soft diet for 3 days and regular diet thereafter. The abdominal pain subsided; the patient responded well to treatment and recovered completely from fever and pain abdomen by day 7. A gastroscopy opinion

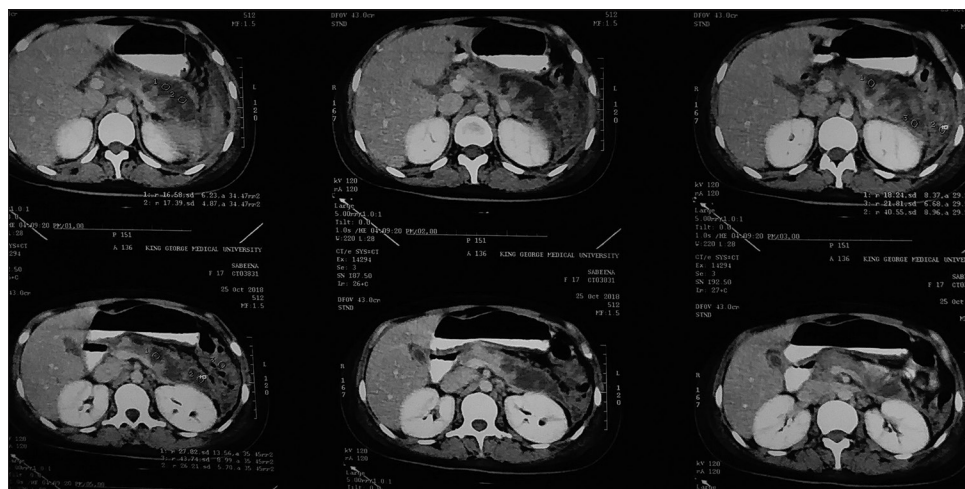
**Table 1:** Laboratory investigation of the patient

Investigations	Day 1	Day 3	Day 5	Day 6	Day 7
Hemoglobin (g%)	7.2 g%	7.3 g%	7.4 g%	7.7 g%	7.9 g%
Total leukocyte count (per/UL)	10700	10840	9400		
Differential Leukocyte Count	N65L29	N70L30-	N75L19-	N80L20-	N72L12,
Mean corpuscular volume (femtoliter)	78	76	78	75	79
Mean corpuscular hemoglobin concentration	25	25	26	30	29
Platelet	0.13	0.2	0.3	0.5	0.7
Random blood sugar (mg/dL)	74	101			
Sodium	131	133			
Potassium	3.9	4.0			
Urea (mg/dL)	68	12			
Creatinine (mg/dL)	2.61	0.4			
Total Bilirubin	0.94	0.69			
Direct bilirubin	0.6	0.46			
Serum glutamic oxaloacetic transaminase	491 U/L	497 U/L	151 U/L		
Serum glutamic pyruvic transaminase	221 U/L	161 U/L	97 U/L		
Alkaline phosphatase	154 U/L	166 U/L			
Serum protein (g/dl)	4.76	5.5			
Serum albumin (g/dl)	3.0	3.11			
HBsAg	Non-reactive				
HCV	Non-reactive				
HIV	Non-reactive				
Prothrombin time	17				
INR	1.06				
Total calcium	7.32 mg/dl				
Ionic calcium	1.28				
Amylase (U/L)	1171	551			
Lipase (U/L)	441	102			
C-reactive protein	121	65	21	6	
Cholesterol	130	58			
High-density lipoproteins	11				
Low-density lipoproteins	20				
pH	7.35				
pCO <sub>2</sub>	44 mmHg				
paO <sub>2</sub>	69 mmHg				
HCO <sub>3</sub>	22 mmol/L				
IgM dengue ELISA	Positive				

INR: International normalized ratio



**Figure 2:** Contrast-Enhanced Computed Tomography abdomen with contrast showing bulky and heterogeneous pancreas. Post-contrast enhancement margins were ill-defined with multiple non enhancing hypodense areas. Extensive stranding of peripancreatic, mesentery, omental and pregastric fat planed is noted with edematous bowel loops



**Figure 3:** Contrast-enhanced computerized tomography abdomen with contrast showing acute necrotizing pancreatitis with developing necrosis

was sought for surgical intervention in view of the necrotic mass being formed; however, a conservative approach was opted. The patient made a complete recovery and was discharged and recalled after 1 month for follow-up. On subsequent follow-up, the patient was found asymptomatic.

## DISCUSSION

Acute pancreatitis is the most common gastrointestinal diagnosis requiring admission. It is defined as inflammation of pancreatic tissue and diagnosed on the basis of the combination of clinical symptoms, laboratory parameters, and imaging. Most common etiology includes gallstone and biliary disease followed by ethanol. Other causes include drugs, autoimmune, hereditary, trauma, and infections [5]. Although infectious causes are rarely considered for acute pancreatitis, they have significant morbidity and mortality [6]. In dengue fever, abdominal and gastrointestinal symptoms are common. This can be due to gastritis, hepatitis, acalculous cholecystitis, peptic ulcer disease, enteritis, and rarely pancreatitis [7]. Viral-induced pancreatitis accounts for 7% of all pancreatitis cases [6].

Dengue virus is an arthropod-borne flavivirus which infects hepatocytes and is associated with thrombocytopenia, fever, malaise, and deranged liver transaminases. Its manifestations may vary from mild-fever with thrombocytopenia to hemorrhagic and vasodilatory shock. It has three phases, namely a febrile phase, critical phase or a phase of plasma leak, and a convalescent-phase or phase of resorption. It can also be classified as dengue fever, dengue hemorrhagic fever, and dengue shock syndrome. Dengue fever is a benign scenario where there are non-specific complaints of fever and malaise and serology are positive. Dengue hemorrhagic fever has severe aches and arthralgias along with petechiae and positive tourniquet test with other hemorrhagic manifestations with positive serology, and dengue shock syndrome is the presence of shock with or without hemorrhagic manifestations with positive serology [8].

Till date, very few cases of dengue virus-induced pancreatitis have been reported [9]. Possible mechanisms proposed are direct invasion of the virus into pancreatic cells, damage secondary to shock (hemorrhagic or vasodilatory) and thrombocytopenia, edema of the ampulla of Vater and rarely autoimmune response generated to dengue virus antigen [10]. In our case, a 17-year-old

female was admitted with fever with rash and abdominal pain. Differential diagnosis of dengue infection, Rickettsial, thrombotic thrombocytopenic purpura/hemolytic-uremic syndrome, vasculitis, and meningococemia was considered. Investigations revealed anemia with thrombocytopenia, deranged kidney function test and liver function test, and elevated levels of amylase and lipase levels (>3 times).

Subsequent CECT abdomen showed bulky pancreas, multiple non-enhancing hypodense areas suggestive of necrosis seen on the body and tail region with extensive peripancreatic fat stranding suggestive of acute necrotizing pancreatitis with normal gallbladder and extrahepatic biliary apparatus (Fig. 3). The workup for fever indicated sterile blood culture, a negative autoimmune profile and negative serology for Rickettsial infection and positive serology for dengue (IgM Dengue+). The patient was conservatively managed with fluids and antibiotics and was kept nil per oral for 4 days and was subsequently started on a soft diet for 3 days and regular diet thereafter. The abdominal pain subsided; she responded well to treatment and recovered completely from fever and pain abdomen by day 7.

Pancreatitis has high mortality if undiagnosed and untreated [11]. It can often remain undiagnosed due to lack of awareness of its association with infective causes like dengue. Clinicians may not order for amylase lipase assay or may brush aside elevated lipase levels as a normal association [12]. Abdominal pain and vomiting are common in both dengue illness and pancreatitis, and thus a severe illness can be unknowingly ignored leading to significant mortality.

## CONCLUSION

As dengue fever has multiple unknown and atypical presentations, lack of awareness of the same is common among physicians. Acute pancreatitis is an uncommon atypical presentation and potentially fatal complication of dengue fever. Complaints of pain abdomen in dengue patients must not be brushed aside as a part of illness but should be investigated on the lines of pancreatitis too and be adequately managed. As resurgence and

epidemics of dengue are common during the rainy season in various parts of the country and with an increasing number of patients, timely recognition of this complication of a common virus in a tropical country such as India can help with proper management and decrease mortality.

## REFERENCES

1. Afghani E, Pandol SJ, Shimosegawa T, Sutton R, Wu BU, Vege SS, *et al.* Acute pancreatitis-progress and challenges: A report on an international symposium. *Pancreas* 2015;44:1195-210.
2. Tsui CY, Burch GE, Harb JM. Pan-creatitis in mice infected with coxsackievirus B1. *Arch Pathol* 1972;93:379-89.
3. Kularatne SA. Dengue fever. *BMJ* 2015;351:h4661.
4. Carod-Artal FJ, Wichmann O, Farrar J, Gascón J. Neurological complications of dengue virus infection. *Lancet Neurol* 2013;12:906-19.
5. Benifla M, Weizman Z. Acute pancreatitis in childhood: Analysis of literature data. *J Clin Gastroenterol* 2003;37:169-72.
6. Parenti DM, Steinberg W, Kang P. Infectious causes of acute pancreatitis. *Pancreas* 1996;13:356-71.
7. Khanna S, Vij JC, Singal KD, Tandon R. Etiology of abdominal pain in dengue fever. *Dengue Bull* 2005;29:85-9.
8. World Health Organization. Comprehensive Guideline for Prevention and Control of Dengue and Dengue Haemorrhagic Fever. Geneva: World Health Organization.
9. Setiawan MW, Samsi TK, Wulur H, Sugianto D, Pool TN. Epigastric pain and sonographic assessment of the pancreas in dengue hemorrhagic fever. *J Clin Ultrasound* 1998;26:257-9.
10. Khor BS, Liu JW, Lee IK, Yang KD. Dengue hemorrhagic fever patients with acute abdomen: Clinical experience of 14 cases. *Am J Trop Med Hyg* 2006;74:901-4.
11. Papachristou GI, Muddana V, Yadav D, O'Connell M, Sanders MK, Slivka A, *et al.* Comparison of BISAP, Ranson's, APACHE-II, and CTSI scores in predicting organ failure, complications, and mortality in acute pancreatitis. *Am J Gastroenterol* 2010;105:435-41.
12. Lee IK, Khor BS, Kee KM, Yang KD, Liu JW. Hyperlipasemia/pancreatitis in adults with dengue hemorrhagic fever. *Pancreas* 2007;35:381-2.

*Funding: None; Conflict of Interest: None Stated.*

**How to cite this article:** Mishra A, Saini R, Kallani M. Acute pancreatitis associated with dengue fever: An interesting and rare complication of dengue virus. *Indian J Case Reports*. 2019;5(1):29-32.

Doi: 10.32677/IJCR.2019.v05.i01.010