

High-dose-rate intracavitary brachytherapy boost post-external beam radiotherapy using rotterdam's applicator in a case of recurrent carcinoma nasopharynx

Shweta Sharma¹, Sharad Bhatnagar², Ajith Nilkanthan³, Manoj Semwal⁴, Sankalp Singh⁵

From ^{1,5}Resident, ²Head, Department of Radiotherapy, ³Head, Department of ENT, ⁴Chief Medical Physicist, Department of Radiation Oncology, Army Hospital, New Delhi, India

Correspondence to: Dr. Shweta Sharma, House no 7/83, VI Floor, Turf View, Defence Officer's Enclave, AJC Bose Marg, Near Alipore Zoo, Alipore, Kolkata – 700022, West Bengal, India. E-mail: Itcolshwetasharma@gmail.com

Received - 23 October 2018

Initial Review - 08 November 2018

Accepted - 31 December 2018

ABSTRACT

Long-term local control is possible in a highly radio-responsive tumor-like carcinoma of the nasopharynx, even in the recurrent setting. High-dose-rate brachytherapy boost with its steep dose fall-off helps achieve salvage by providing optimal dose coverage to the tumor volume which is in close anatomic proximity to critical structures at the base of the skull. Here, we report the case of a 58-year-old lady, an old case of carcinoma nasopharynx presented with recurrence of symptoms in the form of nasal blockade along with a right pre-auricular swelling. Further evaluation showed an fluorodeoxyglucose-avid nasopharyngeal mass, a biopsy from which was positive for nasopharyngeal carcinoma (NPC). She first received re-radiation with external beam radiotherapy using 6 MV photons to the face and neck along with concurrent chemotherapy with cisplatin followed by brachytherapy boost with Rotterdam's Brachytherapy Applicator @5 Gray×2# 1 week apart. Brachytherapy is a feasible tool that allows dose escalation to achieve long-term tumor control in locally advanced NPCs.

Key words: Endocavitary brachytherapy nasopharynx, High-dose rate, Recurrent carcinoma nasopharynx, Rotterdam's applicator

Nasopharynx has a rich submucosal lymphatic network as a result of which 85–90% of cases present with cervical lymphadenopathy, 50% of which is bilateral. Hence, most tumors of nasopharynx spread early to cervical nodes with frequent distant metastasis [1]. Most commonly, Level II lymph nodes are involved (94%) followed closely by the lateral retropharyngeal group of lymph nodes (80%), and rarely, submental, occipital, mediastinal, axillary nodal involvement may also be seen. These tumors also have a high frequency of perineural spread along the cranial nerves. About 80% of primary tumors of the nasopharynx are carcinomas. In the majority of cases, they are undifferentiated and related to Epstein–Barr virus (EBV) infection or poorly to well-differentiated squamous cell carcinomas (SCCs) unrelated to EBV infection. Other tumors, such as lymphomas, are not suitable for brachytherapy [1].

Most of the nasopharyngeal tumors are inoperable due to their anatomic situation at the base of the skull. They are, however, sensitive enough for local control to be achieved with exclusive external beam radiotherapy (EBRT) or chemoradiation so that endocavitary brachytherapy is indicated in the treatment of relatively few cases, as a boost or for recurrent disease. The literature data strongly suggest the existence of a dose-response relationship in the nasopharynx.

Furthermore, since the nasopharynx is deeply situated and surrounded by bone, vessels, and nerves, to achieve dose escalation while maintaining the therapeutic index, the steep falloff of brachytherapy dose is essential to achieve the dosimetric advantage for an opportunity to treat within the zone of nearby critical normal tissue. Of the different methods of brachytherapy application, endocavitary techniques are less challenging than the interstitial ones.

Here, we report the case of a 58-year-old lady with a history of carcinoma nasopharynx presented with recurrence of symptoms in the form of nasal blockade along with a right pre-auricular swelling.

CASE REPORT

A 58-year-old lady presented to the department with the complaints of occasional nasal congestion and a gradually progressive, painless, insidious onset, swelling in front of her right ear. There were no symptoms of dyspnea, dysphonia, dysarthria, or dysphagia. The patient gave a history of nasopharyngeal carcinoma (NPC). She was diagnosed and treated at our hospital in 2003–2004. After the complete clinical evaluation and metastatic workup, she was staged as T2N2M0-Stage III disease and was started on concurrent chemoradiation. She received EBRT to the

face and neck using 6 MV photons on Linac with conventional two-dimensional (2D) planning techniques to a total dose of 4140c gray (Gy)/23# at 5 fractions per week along with weekly cisplatin and paclitaxel, of which she received 4 cycles. However, mid-way through treatment, she developed Grade 2 mucositis and defaulted further chemoradiation despite counseling. Thereafter, the patient was lost to follow-up for 9 years.

The patient presented again in the hospital in August 2012, with a recurrence of symptoms. On examination, the patient had a fairly good Eastern Co-operative Oncology Group (ECOG) performance status of 1 with normal vitals. On local examination, there was a non-tender 1 cm×1.5 cm firm to hard, mobile right pre-auricular nodal region swelling. There was no trismus, ankyloglossia, facial asymmetry, or cranial nerve palsy. There was no growth or lesion in the oral cavity, oropharynx, or larynx.

On posterior rhinoscopy, there was a small bulge in the nasopharynx on the right side near the fossa of Rosenmuller. The rest of the ENT examination was normal. Positron emission topography-computed tomography scan revealed the bulge as well as pre-auricular lymph node to be fluorodeoxy glucose avid. A biopsy from the mass as well as from the pre-auricular node confirmed a NPC recurrence.

The patient was now labeled as rT1N1M0 Stage II disease and was started on concurrent chemoradiation after obtaining written informed consent. Her case was discussed in the Joint Tumor Board, and in view of a long disease-free interval (DFI) of 9 years with good response to incomplete therapy, long time since previous irradiation, with a good ECOG performance status as well as loco-regional and salvageable recurrence, a decision was taken to treat her aggressively with curative intent. Furthermore, since she had received radiation below tolerance doses to critical organ at risk (OAR), so after equieffective dose 2 (EQD2) calculations for normal tissue tolerance, a full dose to the tumor could be achievable providing that patient compliance could be maintained this time. With this ambition, the patient was counseled and encouraged before the start of the treatment to prevent her from defaulting again. Initially, the patient was unwilling for any retreatment; however, later, she agreed on insistence from her husband and son. She received 5940 cGy/33#/52 days EBRT to the face and neck using 6 MV photons using conventional 2D planning techniques on a Siemens dual energy Linac (Model Primus) along with 6 cycles of weekly concurrent chemotherapy with 40 mg/m² iv Cisplatin from end August to early October 2012, after which she further received a boost of 5 Gy×2# of high-dose-rate (HDR) brachytherapy, 1 week apart. She tolerated all phases well and was compliant to the treatment.

The mucosa of the nasal cavity and the nasopharynx was first sprayed with a decongestant (0.05% oxymetazoline hydrochloride) and anesthetized with 5% cocaine hydrochloride applied topically with cotton swabs. The soft palate was anesthetized with a spray of benzocaine, tetracaine hydrochloride, butamben, and benzalkonium chloride (cetacaine). Two 5-French pediatric feeding tubes with an outer diameter of 1.65 mm and an inner diameter of 1.09 mm, respectively, were then introduced into

the nasopharynx transnasally and withdrawn through the mouth transorally to serve as guide tubes for the Rotterdam nasopharynx applicator. The applicator was then guided intraorally over the pediatric feeding tubes into the nasopharynx and the nasal cavity by pulling the nasal portion of the pediatric feeding tubes. Placement of the applicator into the nasopharynx was facilitated by gentle pushing of the oral portion of the pediatric feeding tubes intraorally with a pair of forceps. After the applicator was positioned in the nasopharynx and the nasal cavity, the pediatric feeding tubes were withdrawn, and the applicator was secured in place with a plastic clamp placed over the external portion of the applicator outside the nose (Fig. 1). Dummy iridium-192 sources in afterloading catheters were then inserted into each of the tubes of the applicator. After lead markers were placed on the contralateral outer canthus and tragus, a pair of orthogonal anterior-posterior and lateral localization X-ray films with the dummy sources in place were obtained (Fig. 2). The points of interest, including the nasopharynx, base of the skull, node of Rouviere, pituitary, optic chiasm, spinal cord, and the palate points, were marked on the localization films.

Treatment planning and optimization were then performed with a computer software program (Plato brachytherapy afterloading planning system). Points were selected which should receive the reference dose. Usually, these are the nasopharynx points (Na) and the Rouviere node (R) (Fig. 3). The dose distribution was optimized such that these points receive the prescribed dose. They can be assigned a weighting factor for dose requirements, in case of inadequate optimization. After treatment planning, afterloading catheters were then inserted into the applicator and connected to a remote-controlled, HDR afterloading machine for treatment

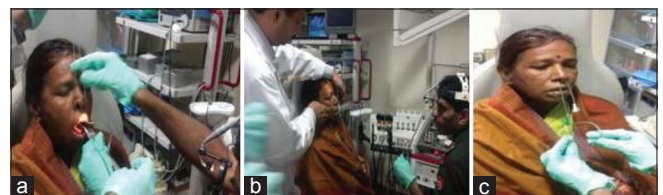


Figure 1: (a-c) Endocavitary brachytherapy applicator insertion procedure on the patient

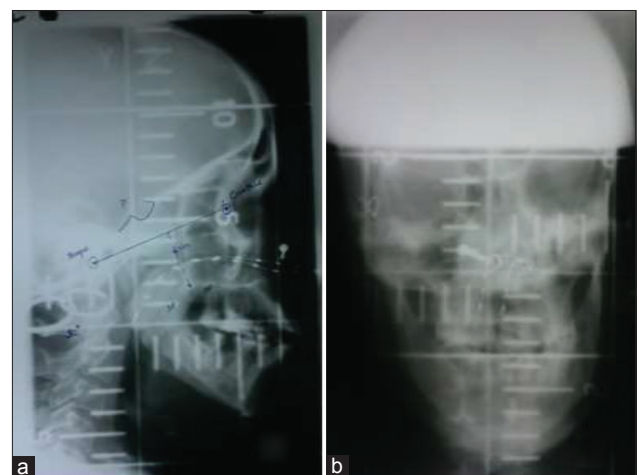


Figure 2: (a and b) Labeled orthogonal X-rays of the patient

delivery. After completion of treatments, the nose clamp and the afterloading catheters were removed. Two 5-French pediatric feeding tubes were reinserted into the applicator and the applicator was withdrawn through the mouth by pushing it into the nose while gently pulling on the feeding tubes exiting the mouth. The patient was re-called after 3 and 6 months for follow-up.

DISCUSSION

The carcinoma of the nasopharynx is relatively common in Asian countries as compared to the Western countries [2]. In most cases, the initial symptoms are a nasal obstruction and/or hypoacusia, while progression can be with cervical nodal involvement or cranial nerve paralysis.

We chose our patient's case for publishing a report due to its uniqueness. In most cases, recurrent cases are not eligible for full dose re-radiation, as tolerance values of OARs have already been reached in the first treatment. However, the peculiarity of our case was such that since the patient had defaulted mid-way through treatment, her total EQD2 was way below tolerance levels, giving us a window of opportunity to treat her aggressively to the full dose. Furthermore, this case is a rare example of the achievement of good locoregional control as reflected by a DFI of 9 years, highlighting probably the underlying favorable tumor biology in the first instance. The literature supports an aggressive approach to management of locoregional nasopharyngeal recurrences as these are largely salvageable. Our patient too has been in remission with very few side effects (occasional rhinorrhea manageable with conservative treatment), for the past 6 years, supporting this logic further.

The Rotterdam nasopharyngeal applicator [2,3] is an inexpensive, reusable, and flexible silicone applicator, tailored to the shape of the soft tissues of the nasopharynx and generally well tolerated by patients. It is suitable for applications with stepping source after loaders for post-delivery room or HDR-brachytherapy, as well as for classical low-dose rate. Depending on the epicenter

of the tumor, for instance, in case of low to mid-posterior wall, a transoral or transnasal approach and, for a high posterior wall, a transpalatal approach or split-palate approach can be used. It can remain *in situ* for the duration of the treatment, which varies from 2 to 6 days, and can be performed on an outpatient department basis in case of HDR brachytherapy. The shape of the silicone applicator closely conforms to the nasopharyngeal vault. The two silicone tubes, with an outer diameter of 15 French and an inner diameter of 9 French, can accommodate standard 6 French afterloading catheters. The radioactive sources are consequently positioned closer to the base of the skull than to the soft palate.

Even though three-dimensional (3D) cardiac resynchronization therapy (CRT), intensity-modulated radiation therapy, and stereotactic radiotherapy are the mainstays of treatment of NPC with very encouraging outcomes, many radiotherapy centers still rely on a 2D technique to treat the numerous patients referred to them. Until these centers adopt 3D-CRT as a standard, they will need to optimize the resources available. Dose escalation directly correlates with better locoregional control and prolonged overall survival in NPC. The inherent physical and dosimetric characteristics of brachytherapy allow the delivery of a high dose to the nasopharynx at the same time minimizing the dose to adjacent structures.

As per the literature, brachytherapy, although associated with major complications, provides reasonable long-term outcomes in salvaging recurrent NPC. In one of the earliest retrospective comparative studies [4], there was a benefit in local relapse-free survival (LRFS) as well as overall survival for patients treated for T1-4 carcinoma of the nasopharynx treated by EBRT plus endocavitary brachytherapy boost (between 1997 and 1994), as opposed to patients treated by EBRT only (between 1978 and 1988) to a minimum dose of 60 Gy (Fig. 4a). However, there was a significant excess death rate due to intercurrent disease and/or second primaries. The gain in local control was mainly confined to the T1-3 patient category. Except for a few patients developing synechia, no significant difference in morbidity was observed

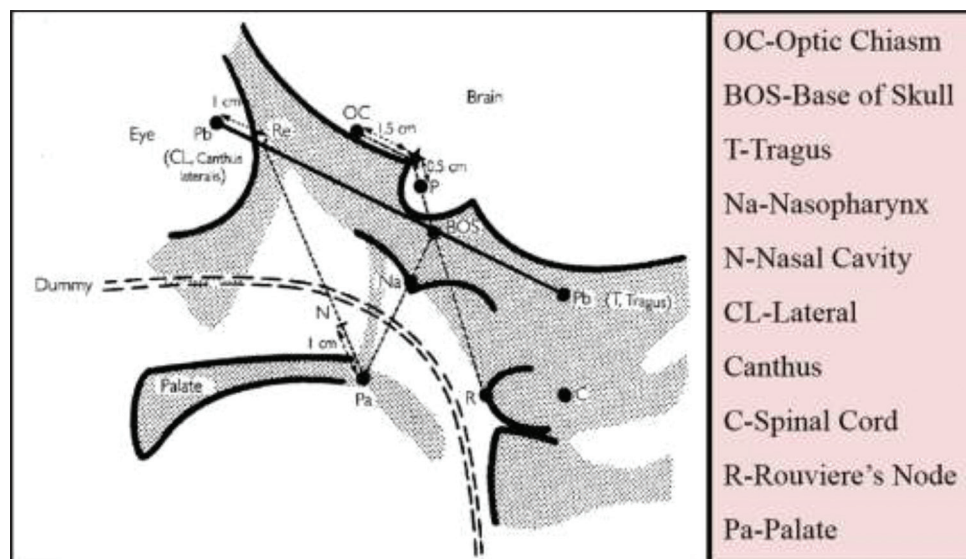


Figure 3: Dosimetry points




Figure 4: (a) Graph [4] and (b) table [5] showing results of previous studies

for patients treated by external radiotherapy only compared with those treated by external radiotherapy plus brachytherapy. In this study, however, only primary disease and only SCC histology were included, and recurrent disease was excluded.

The N stage at recurrence is a significant prognostic factor for both LRFS and disease free survival. Several publications [5] (Fig. 4b) have reported that re-irradiation dose is one of the most important factors for local-regional progression after the salvage treatment. The general consensus is that re-irradiation dose above 60 Gy is needed for effective salvage [6,7]. For small-volume recurrences treated with brachytherapy alone, Choy *et al.* [8] reported a local control rate of 61% at 5 years with 60 Gy delivered by gold grain implants. Moreover, the local control was superior in failures confined to the nasopharynx compared to failures extending beyond the nasopharynx, 81 versus 44%, respectively. Similar results have been observed by Kwong *et al.* [9] who observed an overall survival rate at 5 years of 54%, with the sequelae of headache, palatal fistula, and mucosal radiation necrosis at the site of implantation in 28, 19, and 16% of the patients, respectively. On the other hand, Zheng *et al.* [10] reported that the 5-year actuarial local failure-free survival rate of patients with initially diagnosed T3–T4 disease for the 3D conformal radiotherapy group and brachytherapy group was 84 versus 60%, with 3D conformal radiotherapy providing better local control than brachytherapy as a salvage treatment for locally persistent NPC, especially in patients with initially diagnosed T3–T4 disease.

Results from a contemporary literature are available from a study carried out between July 1996 and March 2008, whereby 29 patients were re-irradiated for locally recurrent nasopharyngeal cancer (LR-NPC) treated at Memorial Sloan Kettering Cancer Center, New York. 13 patients received combined-modality treatment (CMT), consisting of EBRT followed by intracavitary

brachytherapy, whereas 16 received EBRT alone. The median follow-up for all patients was 45 months and for surviving patients was 54 months. A 5-year actuarial local control, event-free survival, and overall survival rates were 52%, 44%, and 60%, respectively. No difference was observed between patients treated with EBRT and CMT. Overall survival was superior in patients who achieved local control ($p=0.0003$) [11]. The incidence of late Grade ≥ 3 events in patients retreated with EBRT alone was significantly increased compared with those receiving CMT (73% vs. 8%; $p=0.005$). In this modern re-irradiation series of patients with LR-NPC, favorable overall survival was achieved in comparison to historical series. Patients treated with CMT experienced significantly fewer severe late effects compared with those treated with EBRT. The authors strongly recommended the addition of brachytherapy to early-stage recurrences.

CONCLUSION

Intracavitary brachytherapy using the Rotterdam’s nasopharyngeal applicator is an easy to use, patient-friendly, economical alternative for dose escalation in recurrent NPC at institutes where conformal and complex radiation treatment techniques are not yet available. It provides a reasonable hope for long-term locoregional control as well as increased overall survival in selected patients of recurrent NPC with acceptable morbidity.

REFERENCES

1. Wang CC. Carcinoma of the nasopharynx. In: Radiation Therapy for Head and Neck Neoplasms. 3rd ed. New York: Wiley-Liss; 1997. p. 257-260.
2. Levendag PC, Peters R, Meeuwis CA, Visch LL, Sipkema D, de Pan C, *et al.* A new applicator design for endocavitary brachytherapy of cancer in the nasopharynx. *Radiother Oncol* 1997;45:95-8.
3. Levendag PC, Visser AG, Kolkman-Deurloo IK, Eijkenboom WM, Meeuwis CA. HDR brachytherapy with special reference to cancer of the

- nasopharynx. In: Brachytherapy from Radium to Optimization. Speiser. Veenendaal, The Netherlands: Nucletron International BV; 1994. p. 121-31.
4. Levendag PC, Peter R, Meeuwis CA, Visch LL, Sipkema D, de Pan C, *et al.* A new applicator design for endocavitary brachytherapy of cancer in the nasopharynx. *Radiother Oncol* 1997;45:95-8.
 5. Levendag P, De Pan C, Sipkema D, Visser A, Kolkman IK, Jansen P. Principles and practice of brachytherapy using after loading systems. In: Joslin CA, Flynn A, Hall EJ. High Dose-rate Interstitial and Endocavitary Brachytherapy in Cancer of the Head and Neck. Ch. 21. London: Hodder Arnold; 2001. p. 307-10.
 6. Mazon JJ, Van Limbergen E. Gec-Estro Handbook-of-Brachytherapy. Ch. 13. Leuven, Belgium: ACCO; 2002. P. 289-97.
 7. Smee RI, Meagher NS, Broadley K, Ho T, Williams JR, Bridger GP, *et al.* Recurrent nasopharyngeal carcinoma: Current management approaches. *Am J Clin Oncol* 2010;33:469-73.
 8. Choy D, Sham JS, Wei WI, Ho CM, Wu PM. Transpalatal insertion of radioactive gold grain for the treatment of persistent and recurrent nasopharyngeal carcinoma. *Int J Radiat Oncol Biol Phys* 1993;25:505-12.
 9. Kwong DL, Wei WI, Cheng AC, Choy DT, Lo AT, Wu PM, *et al.* Long term results of radioactive gold grain implantation for the treatment of persistent and recurrent nasopharyngeal carcinoma. *Cancer* 2001;91:1105-13.
 10. Zheng XK, Chen LH, Chen YQ, Deng XG. Three-dimensional conformal radiotherapy versus intracavitary brachytherapy for salvage treatment of locally persistent nasopharyngeal carcinoma. *Int J Radiat Oncol Biol Phys* 2004;60:165-70.
 11. Cheah SK, Lau FN, Yusof MM, Phua VC. Treatment outcome with brachytherapy for recurrent nasopharyngeal carcinoma. *Asian Pac J Cancer Prev* 2014;14:6513-8.

Funding: None; Conflict of Interest: None Stated.

How to cite this article: Sharma S, Bhatnagar S, Nilkanthan A, Semwal M, Singh S. High-dose-rate intracavitary brachytherapy boost post-external beam radiotherapy using rotterdam's applicator in a case of recurrent carcinoma nasopharynx. *Indian J Case Reports*. 2019;5(1):24-28.

Doi: 10.32677/IJCR.2019.v05.i01.009